

# A Study of Anatomical Variations in Patients with Chronic Rhinosinusitis.

Smruti Swain<sup>1</sup>

<sup>1</sup>Associate Professor, Department of ENT, SCB Medical College Cuttack, Odisha, India.

Received: January 2018

Accepted: January 2018

**Copyright:** © the author(s), publisher. It is an open-access article distributed under the terms of the Creative Commons Attribution Non-Commercial License, which permits unrestricted non-commercial use, distribution, and reproduction in any medium, provided the original work is properly cited.

## ABSTRACT

**Background:** Improvements in functional endoscopic sinus surgery (FESS) and computed tomography (CT) have concurrently increased interest in the anatomy of the nose and paranasal sinuses. Revolutionary changes in the surgical treatment of rhino sinusitis in recent years, particularly in endoscopic surgery, require the surgeons to have detailed knowledge of the anatomy of the lateral nasal wall, paranasal sinuses and surrounding vital structures. A number of anatomical variants in the region are encountered, many of which are detectable only by the use of CT. These variations might induce osteomeatal obstruction, preventing mucus drainage and predisposing to chronic rhino sinusitis. The aim of this prospective study was to analyze the incidence of anatomic variations in a series of 100 patients with persistent symptoms of chronic rhinosinusitis after failure of preliminary medical therapies and their correlation with paranasal sinus disease, to assess whether anatomic variations are associated with disease pathology and to identify those variants that may impact operative safety. Setting: Tertiary care otolaryngology unit. **Methods:** 100 consecutive cases of chronic rhino sinusitis patients attending the ENT outpatient department, during a period of June 2015-May 2017, who had chronic sinusitis for more than three months duration not responding to the medical treatment and who were willing to undergo Functional Endoscopic Sinus Surgery satisfying the inclusion criteria were studied. **Results:** In our study it was observed that 72% patients had anatomic variations. 43% of the chronic sinusitis cases had two or more anatomical variations and 29% of the cases had single anatomical variation. Deviated nasal septum in 41% cases, Concha bullosa was found in 36%, paradoxical middle turbinate in 11% cases. **Conclusion:** Prevalence of multiple anatomical variations was more in our study in comparison to single anatomical variation. Deviated nasal septum was the most common anatomical variation encountered in our study followed by concha bullosa.

**Keywords:** Chronic rhino sinusitis, FESS, Osteomeatal complex, Paranasal sinuses.

**Abbreviations:** CRS-chronic rhinosinusitis, FESS-functional endoscopic sinus surgery, PNS-para nasal sinus

## INTRODUCTION

Chronic Rhinosinusitis is defined as an inflammation of the nose and the paranasal sinuses characterised by at least 8-12 weeks of at least 2 symptoms, like nasal blockage/obstruction/congestion, nasal discharge (anterior/posterior nasal drip), facial pain/pressure and/or reduction or loss of smell and either endoscopic signs of disease or relevant CT scan changes. Confirmation of sinus disease using an objective measure is required because the symptoms can be nonspecific and mimicked by several disease entities (eg, upper respiratory tract infection, allergic rhinitis, migraine). Conversely, in the absence of symptoms, diagnosis of CRS based on radiology alone is not appropriate because of a high incidence

of radiological anomalies on CT scans in normal individuals. Thus, the presence of symptoms plus an objective finding are necessary.<sup>[1]</sup> Addition of nasal endoscopy to symptom assessment substantially increased diagnostic accuracy in confirming the presence of CRS using sinus CT as the criterion standard.<sup>[2]</sup>

The approach to patients with chronic rhino sinusitis has changed after Messerklinger published the first comprehensive account of technique of nasal endoscopy and its application to the diagnosis and treatment of sinonasal diseases.<sup>[3]</sup> The endoscopic surgery aims at removing the obstruction of the main drainage pathway. Surgical clearance of these chronically infected sinuses while maintaining their ventilation and drainage is the treatment of choice.<sup>[4]</sup> Improvements in functional endoscopic sinus surgery (FESS) and computed tomography (CT) have concurrently increased interest in the anatomy of the nose and paranasal sinuses. Common anatomical variations are not rare in patients with chronic rhinosinusitis. Revolutionary changes in the surgical treatment of rhino sinusitis in recent years, particularly in endoscopic surgery, require the

### Name & Address of Corresponding Author

Dr. Smruti Swain  
Associate Professor,  
Department of ENT,  
SCB Medical College Cuttack,  
Odisha,  
India.

surgeons to have detailed knowledge of the anatomy of the lateral nasal wall, paranasal sinuses and surrounding vital structures. A number of anatomical variants in the region are encountered, many of which are detectable only by the use of CT.<sup>[5]</sup> These variations might induce osteomeatal obstruction, preventing mucus drainage and predisposing to chronic rhino sinusitis.

Moreover, anatomic variants with a potential impact on surgical safety occur frequently and need to be specifically sought as part of preoperative evaluation.<sup>[6-8]</sup>

#### **Aims and objectives**

- To study epidemiological factors associated with CRS
- To study the clinical picture and radiological investigations of CRS.
- To study how anatomical variations impact progression of disease
- To study modification in management if anatomical variations are present

## **MATERIALS AND METHODS**

The present study was conducted in the Dept. of ENT and head neck surgery, SCB medical college Cuttack from June 2015 to May 2017. Patients with Chronic Rhinosinusitis (as per the criteria for diagnosis) attending the OPD and indoor were selected for the study.

#### **Exclusion criteria**

Patients with sinusal polyp, allergic fungal sinusitis, nasal mass, osteomyelitis, previous sinus surgery.

Clinical study comprise of 100 consecutive cases of chronic rhinosinusitis. A detailed history, clinical examination was done in all cases. They were investigated and treated and follow up was done upto a minimum period of 12 weeks.

## **RESULTS**

**Table 1: Showing age incidence of patients.**

Age in years	No. of patients
0-10	4
10-20	28
21-30	19
31-40	38
41-50	6
51-60	4
>60	1
Total	100

**Table 2: Sex distribution.**

Sex	No. of patients
Male	68
Female	32
Total	100

Out of 100 patients, 38 were in the age group of 31-40 years followed by 28 patients who were in 11-20

years age group; it is less common in extreme of ages. There were 68 male and 32 female, with male female ratio of 2.1:1

**Table 3: Incidence of symptoms.**

Symptoms	No. of pts
Nasal obstruction	82
headache	58
Nasal discharge	48
Post nasal discharge	23
Disturbance of smell	15
Nasal bleeding	11
Irritation in throat	38
Aural problems	14
Foetid smell from mouth	8
Facial pain	24
Sneezing	10

Mostly patients complained of nasal obstruction, headache, nasal discharge and maximum patients had multiple complains.

**Table 4: Incidence of abnormality of turbinates.**

Abnormality of turbinates	Number of patients
Hypertrophy of inferior turbinate	34
Hypertrophy of middle turbinate	8
Hypertrophy of both inferior and middle turbinate	15
Atrophy of inferior turbinate	3
Atrophy of both inferior and middle turbinate	2

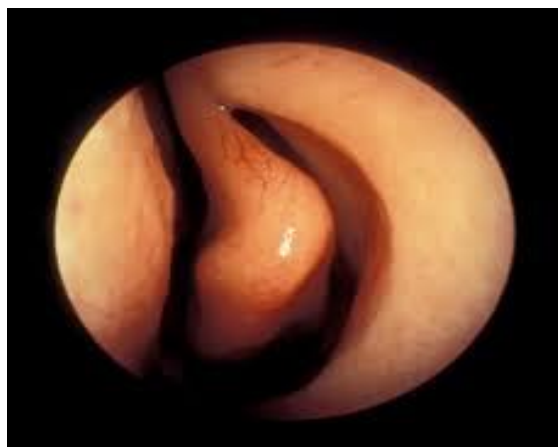This table shows that out of 100 patients, 34 had hypertrophy of only inferior turbinate and 15 had hypertrophy of both inferior and middle turbinate.

**Table 5: Endoscopic evaluation.**

Variations	Unilateral Number of pts	Bilateral Number of pts	Total
Deviated nasal septum			41
Uncinate attached to middle turbinate	8	17	25
Uncinate attached to lamina papyracea	12	54	66
Infundibular obstruction	5	57	62
Prominent agar nasi cell	10	12	22
Accessory maxillary ostium	6	5	11
Purulent discharge	4	8	12
Mucoid discharge	8	14	22
Concha bullosa	18	10	28
Paradoxical middle turbinate	6	5	11

In the present study anatomical variations like concha bullosa was present in 34% cases, deviated

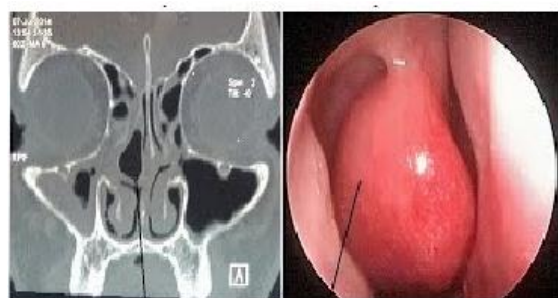
nasal septum in 41 % cases, infundibular obstruction was found in 67% cases, and discharge in middle meatus in 36 % cases.



**Figure 1: Endoscopic view of paradoxical middle turbinate**

**Table 6: CT Evaluation.**

Variations	unilateral No.of patients	bilateral No.of patients	Total No. of patients
concha bullosa	20	16	36
Paradoxical middle turbinate	6	5	11
Uncinate attached to lamina	5	61	66
Uncinate attached to middle turbinate	4	21	25
frontal recess narrowing	12	6	18
Maxillary sinus hypoplastic	4	9	13
agar nasi cell	17	5	22
Haller cell	7	8	15
Onodi cell	6	2	8
pneumatized anterior clinoid process	4	14	18
Pneumatized posterior clinoid process	8	6	14
deviated nasal septum			41

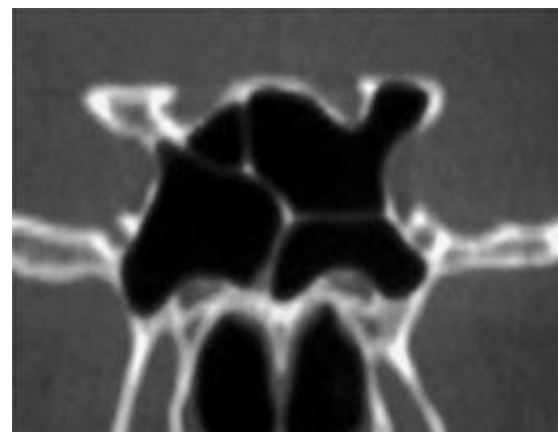


**Figure 2: CT finding and Endoscopic of concha bullosa.**

A detailed analysis of CT scans showed 72 of 100 patients had common or uncommon anatomic

variations and most of them had more than one variation. Deviated nasal septum in 41% cases, Concha bullosa was found in 36%, paradoxical middle turbinate in 11% cases,

With respect to the level difference between the ethmoid and cribriform plate, Keros grade I was by far the most common at 78% followed by grade II in 13% and grade III in 9 % patients. The maxillary sinus (82%) was most commonly involved, followed by the anterior ethmoid (52%), frontal sinus (21%), posterior ethmoid (6%) and sphenoid sinus (6%).



**Figure 3: Pneumatized anterior clinoid process**

**Table 7: Incidence of different surgeries.**

Types	No of cases
Uncinectomy	92
Anterior Ethmoidectomy	52
Total Ethmoidectomy	6
Sphenoidectomy	6
Frontal sinus surgery	21
Septoplasty	16
Revision surgery	6

Uncinectomy was performed in 92% cases, followed by anterior ethmoidectomy in 52% cases.

## DISCUSSION

Commonest age incidence for CRS was 31-40 yrs in our study, followed by 10-20 years age group. Similar age incidence was there in the study of Aramani A and Karadi R N et al.<sup>[9]</sup> But in a study by Uday srikar and Harini r.m 21-30 years was the common age group affected by CRS.<sup>[10]</sup>

In our study 68 were male and 32 were female in the ratio of 2.1:1. In the study of Sachdeva P et al. Male, female ratio was 1.7:1, and in the study of uday srikar Harini 56.07% were males and 43.93% were females.<sup>[10,11]</sup>

Nasal obstruction was the most common presenting symptom (82 %), followed by headache [58%] and nasal discharge (48 %). In the study of Uday srikar Harini M, Major presenting symptoms were Nasal obstruction (85%), Headache (71%), Nasal discharge (36%) and Sneezing (29%). But Headache was the most common symptom (85%) followed by

post nasal drip (80%) in the study of Sachdeva P et al.<sup>[10,11]</sup>

The maxillary sinus(82) was most commonly involved, followed by the anterior ethmoid(52%), frontal sinus(21%), posterior ethmoid (6%) and sphenoid sinus(6%) . In the study of UDAY SRIKAR DR. M.HARINI M,Maxillary sinus was predominantly involved(87%), followed by Ethmoidal sinus(72%), Sphenoid sinus(38.3%) and Frontal(34.6%).

A detailed analysis of CT scans showed 72of 100 patients had common or uncommon anatomic variations and most of them had more than one variation

Similar findings were reported by Liu X et al., who observed prevalence of about 81% anatomical variations in chronic rhinosinuisitis cases.<sup>[12]</sup>

Severino Aires de Araujo Neto et al. reported relatively less anatomical variations 65% in the osteomeatal complex of the chronic rhino sinusitis cases.<sup>[13]</sup> Perez et al. also observed similar prevalence of anatomical variations in the chronic sinusitis cases.<sup>[14]</sup>

Deviated nasal septum was found to be the most common amongst the anatomical variations (41%) in chronic sinusitis cases in the present study which was followed by concha bullosa (36%)and paradoxically bent middle turbinate. Agger nasi cell in 22 and Haller cell in 15 pts.

In the study ofAramani, Karadi ,the most common anatomic variation observed on CT scans was nasal septal deviation, which was presented by 58.5%patients. Concha bullosa of the middle turbinate was the second most common variant, observed in 49.3%, and was mostly seen on one side of the nasal wall (30.7%). A total of 32.8% had hypertrophic ethmoid bulla, whereas agger nasi cell was observed in 24.3% patients.

The most common anatomical variation in all patients (study + control group), was septal deviation (72.7 %) in the study of Ahmet Kaygusuz, Mehmet Haksever, et al.<sup>[15]</sup>

### Summary

Present study was carried in the Dept. of ENT and head neck surgery from2016-2017. The clinical material for the study include 100 patients with CRS.

1. Out of them the age group of 31-40 years was most commonly affected by CRS
2. males are more affected than females in the ratio of 2.1:1
3. Out of the 100 cases commonest presenting symptom was nasal obstruction(82%), followed by headache ((58%) and nasal discharge (48%) cases.
4. The most common anatomical variation was deviated nasal septum(41%) followed by concha bullosa(36%). Agar nasi cell (22%) ,haller cell (15%).
5. Most common surgery done was uncinectomy followed by anterior ethmoidectomy.

## CONCLUSION

Many authors believe that anatomical variations of paranasal sinus structures may predispose patients to recurrent sinusitis.<sup>[16,17]</sup> On the other hand, the relative importance of anatomical variations is still a matter of discussion, and a consensus has not been reached.<sup>[18]</sup>

## REFERENCES

1. Desrosiers M, Evans GA, Keith PK, et al. Canadian clinical practice guidelines for acute and chronic rhinosinusitis. J Otolaryngol Head Neck Surg. 2011;40(Suppl 2):S99–S193.
2. Bhattacharyya N, Lee LN. Evaluating the diagnosis of chronic rhinosinusitis based on clinical guidelines and endoscopy. Otolaryngol Head Neck Surg. 2010;143(1):147–151.
3. Messerklinger W. Endoscopy of the nose. Baltimore, MD: Urban & Schwarzenberg; 1978.
4. Dua K, Chopra H, Khurana AS, et al. CT scan variations in chronic sinusitis. Ind J Radiol Imag. 2005; 15:315–20
5. Bolger WE, Butzin CA, Parsons DS. Paranasal sinus bony anatomic variations and mucosal abnormalities: CT analysis for endoscopic sinus surgery. Laryngoscope. 1991; 101:56–64
6. Danese M, Duvoisin B, Agrifoglio A, et al. Influence des variantes anatomiques nasosinuales sur les sinusites recidivantes, persistantes ou chroniques. J Radiol. 1997;78:651–657.
7. Kennedy DW, Zinreich SJ. The functional endoscopic approach to inflammatory sinus disease: current perspectives and technique modifications. Am J Rhinol. 1988; 2:89–96.
8. Stammberger HR, Posawetz W. Functional endoscopic sinus surgery. Concept, indications and results of the Messerklinger technique. Arch Otorhinolaryngol. 1990; 247:63–66.
9. Aramani A, R.N. Karadi, et al :A Study of Anatomical Variations of Osteomeatal Complex in Chronic Rhinosinusitis Patients-CT Findings J Clin Diagn Res. 2014 Oct; 8(10): KC01–KC04
10. Uday srikar.v.s.,Harini r.m: Endoscopic Study in Regard To Anatomical Variations in Cases of Sinusitis in A Tertiary Care Hospital in South India – Case Series, - International journal of scientific research,Volume: 5 | Issue : 12 | December 2016
11. Sachdeva P \*, Kuldeep S. et al. International Journal of Otorhinolaryngology and Head and Neck Surgery. 2017 Jul;3(3):606-610
12. Liu X, Zhang G, Xu G .Anatomic variations of the ostiomeatal complex and their correlation with chronic sinusitis: CT evaluation].i. 1999 Jun; 34(3):143-6
13. Severino Aires de Araújo Neto, et al. The role of osteomeatal complex anatomical variants in chronic rhinosinusitis. Radiol Bras. 2004;39:227–32.
14. Pérez-Piñas, Sabaté J ,et al,Anatomical variations in the human paranasal sinus region studied by CT.J Anat. 2000 Aug; 197 ( Pt 2):221-7.
15. Ahmet Kaygusuz, Mehmet Haksever, Sinonasal Anatomical Variations: Their Relationship with Chronic Rhinosinusitis and Effect on the Severity of Disease—A Computerized Tomography Assisted Anatomical and Clinical Study, Indian J Otolaryngol Head Neck Surg. 2014 Sep; 66(3): 260–266
16. Bolger WE, Butzin CA, Parsons DS, Paranasal sinus bony anatomic variations and mucosal abnormalities: CT analysis for endoscopic sinus surgery. Laryngoscope. 1991 Jan; 101(1 Pt 1):56-64
17. Fadda GL, Rosso S, Aversa S, Petrelli A, Ondolo C, Succo G Multiparametric statistical correlations between paranasal sinus anatomic variations and chronic rhinosinusitis. Acta Otorhinolaryngol Ital. 2012 Aug; 32(4):244-51.

*Swain; Anatomical Variations in Patients with Chronic Rhinosinusitis*

18. Nair S ,Correlation between symptoms and radiological findings in patients of chronic rhinosinusitis: a modified radiological typing system.Rhinology. 2009 Jun; 47(2):181-6.

**How to cite this article:** Swain S. A Study of Anatomical Variations in Patients with Chronic Rhinosinusitis. Ann. Int. Med. Den. Res. 2018; 4(2):EN01-EN05.

**Source of Support:** Nil, **Conflict of Interest:** None declared