

Study of Radiological Changes of Bones in Leprosy Patients.

K. Balarami Reddy¹, L.Sreedevi¹, S.Suryanarayana²

¹Assistant Professor, Department of DVL, Govt. Medical College, Anantapuramu, Andhra Pradesh.

²Professor & HOD, Department of DVL, Govt. Medical College, Anantapuramu, Andhra Pradesh.

Received: November 2017

Accepted: November 2017

Copyright: © the author(s), publisher. It is an open-access article distributed under the terms of the Creative Commons Attribution Non-Commercial License, which permits unrestricted non-commercial use, distribution, and reproduction in any medium, provided the original work is properly cited.

ABSTRACT

Background: India has the greatest number of leprosy cases worldwide, Brazil is the second and Indonesia is the third most common country. Many changes, like bone involvement and soft tissue changes occur in leprosy due to various factors like specific leprosy infection, deformity, anaesthesia, trauma and ulceration, can be observed in skiagrams. The aim of the study is to know the prevalence of radiological changes in Leprosy patients and various presentations of radiological changes. **Methods:** The present study included 35 cases of leprosy who attended the out-patient clinic, Department of Dermatology, Venereology & Leprology, Government General Hospital, Anantapuramu, Andhra Pradesh. Radiographs were taken for all the patients, including Anteroposterior, lateral or oblique view of both hands, both feet and nasal bones. These skiagrams were studied, for specific, non-specific bone changes and osteoporosis, in detail. These radiological findings have been correlated with other clinical features. **Results:** Majority of the patients were presented with contractures of digits (71.4%), followed by 60%, Trophic or other ulcers (48.5%), wasting of muscles (37.1%), Nasal deformity (31.4%). Nasal bone erosions were noted among 3(8.5%) out of 35 patients, whereas nasal bone resorption observed in a patient (2.8%). 42.8% patient radiological changes were observed as both specific & nonspecific changes, 28.5% were nonspecific bone changes, 20% were Osteoporosis and 8.5% were specific bone changes. **Conclusion:** Once bone changes develops in leprosy patients, its difficult to treat patient and also need good rehabilitation resources. Early diagnosis and prompt treatment may help to avoid bony deformities.

Keywords: Leprosy, Bone, Skiagram.

INTRODUCTION

Leprosy is a chronic infectious disease caused by acid-fast, rod shaped bacillus, Mycobacterium leprae, which evokes a localized or wide spread granulomatous response that can be either self-limiting or progressive, depending on the immunologic status of the host.^[1]

India has the greatest number of cases, Brazil is the second and Indonesia is the third most common country. WHO detected new cases of leprosy 228,474 during the year 2010, whereas the beginning of 2011 prevalence of leprosy stood at 192,246.^[2] Worldwide 2 to 3 million people are estimated to be permanently disabled due to leprosy.^[3]

Its principal clinical manifestations are determined more by the nature and vigour of the host's response to the infection than by the multiplication of the causative agent in the tissues. Its course can be interrupted by acute immunologic responses by the host to dead mycobacterium leprae.

Leprosy affects various parts in the body such as nerves, skin, mucous membranes of the upper respiratory tract, anterior chamber of the eyes, and testis in male (all cooler parts of the body).^[4] It sometimes certain other tissues like muscle, bone, adrenal gland and kidney.

Although leprosy was one of the earliest human diseases to be associated with a specific microorganism, it is among the last of the infections to yield its major secrets.^[5] Fascinating in its variegated clinical pattern, important because of its wide distribution in the world, and intriguing by reason of its accompanying peripheral neuropathy, and unresolved pathologic and epidemiologic riddles, leprosy constitutes a continuing challenge to the physician and research workers.

The aim of the study is to know the prevalence of radiological changes in Leprosy patients and various presentations of radiological changes.

MATERIALS AND METHODS

The present study included 35 cases of leprosy who attended the out-patient clinic, Department of Dermatology, Venereology & Leprology, Government General Hospital, Anantapuramu,

Name & Address of Corresponding Author

Dr. L. Sreedevi,
Assistant Professor,
Department of DVL,
Govt. Medical College, Anantapuramu, Andhra Pradesh

Andhra Pradesh. This study analysed prospectively done from July 2012 to June 2016 at Department of DVL. They were 28 (80%) male and 7 (20%) female patients. The youngest patient was aged about 25 years. Leprosy was classified on the basis of clinical features into lepromatous, tuberculoid, borderline or dimorphous, borderline-tuberculoid, borderline-lepromatous and polyneuritic (neural) leprosy. The average duration of illness as stated by patient was 6 years.

Clinically 4 (11.4%) were tuberculoid, 14 (40%) were borderline, 15 (42.8%) lepromatous and 2 (5.7%) polyneuritic cases. All these cases were thoroughly examined and the clinical findings were noted. A detailed history was taken and recorded. Skin-slit smears were examined from the lepromatous and borderline lepromatous cases for AFB.

Radiographs were taken for all the patients, including Anteroposterior, lateral or oblique view of both hands, both feet and nasal bones of all patients. These skiagrams were studied, for specific, non-specific bone changes and osteoporosis, in detail. These radiological findings have been correlated with other clinical features.

RESULTS

Most of the patients had deformities and the incidence of deformity is more among males. Maximum number of deformities found in patients who are aged 40 years or above [Table 1].

Table 1: Prevalence of different types of leprosy among males and females.

Type of leprosy	Male		Female		Total	
	No	%	No	%	No	%
Polyneuritic	1	2.8	1	2.8	2	5.7
Tuberculoid	3	8.5	1	2.8	4	11.4
Borderline	11	31.4	3	8.5	14	40
Lepromatous	13	37.1	2	5.7	15	42.8
Total	28	80	7	20	35	100

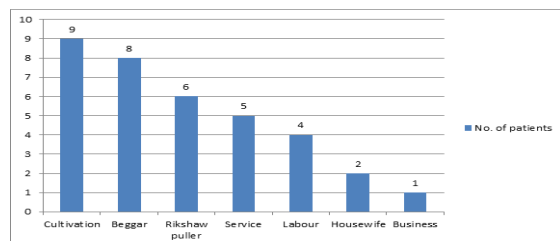


Figure 1: Occupation of leprosy patients.

Most of them were poor socioeconomic status and many of them were manual labourers who work as farmers, rickshawpullers, Beggars. 25.7% are doing cultivation, 22.8% were beggars, 17.1% were rikshaw pullers, 14.2% were service men, 11.4% were working as labour, 5.7% were house wife and 2.8% were businessmen [Figure 1].

Majority of the patients were presented with contractures of digits (71.4%), followed by 60%, Trophic or other ulcers (48.5%), wasting of muscles (37.1%), Nasal deformity (31.4%) [Table 2].

Table 2: Prevalence of various forms of deformities.

Type of Deformity	No. of cases (n=35)	Percentage (%)
Contractures of digits	25	71.4%
Loss of digits	21	60%
Trophic or other ulcers	17	48.5
Wasting of Muscles	13	37.1%
Nasal Deformity	11	31.4%

Both specific and nonspecific bone changes were noted most commonly among leprosy patients. 42.8% patient radiological changes were observed as both specific & nonspecific changes, 28.5% were nonspecific bone changes, 20% were Osteopetrosis and 8.5% were specific bone changes [Table 3].

Table 3: Bone radiological changes among leprosy patients.

Type of disease	No. of cases	Specific bone changes		Non-Specific bone changes		Both specific & Non specific		Osteopetrosis	
		No	%	No	%	No	%	No	%
Polyneuritic	2	0	0	2	5.7	0	0	0	0
Tuberculoid	4	0	0	2	5.7	1	2.8	1	2.8
Borderline	14	1	2.8	3	8.5	7	20	3	8.5
Lepromatous	15	2	5.7	3	8.5	7	20	3	8.5
Total	35	3	8.5	10	28.5	15	42.8	7	20

Majority of patients affected with lesions on both hands (51.4%), one foot (37.1%) followed by one hand and one foot (25.7%) [Table 4].

Table 4: Deformities based on the site of lesion.

Location	No. of cases	Percentage
One hand	6	17.1%
One foot	13	37.1%
Both hands	18	51.4%
Both feet	5	14.2%
One hand and one foot	9	25.7%
Both hands and one foot	6	17.1%
Both feet and one hand	4	11.4%
Both hands and both feet	7	20%

Nasal bone erosions were noted among 3(8.5%) out of 35 patients, whereas nasal bone resorption observed in a patient (2.8%).

DISCUSSION

Many changes, like bone involvement and soft tissue changes occur in leprosy due to various factors like specific leprosy infection, deformity, anaesthesia, trauma and ulceration, can be observed in skiagrams. Bone changes are mainly of two types, specific and non-specific. Specific changes are due to specific

infection by *Mycobacterium leprae* and non-specific changes are due to deformity and indiscriminate use of anaesthetic limb which received repeated trauma and infection resulting in chronic ulcers. Osteoporosis is also observed and is due to lodgement of *M. Leprae* in medulla and also to disuse. Soft tissue changes observed were swelling, absorption and contractures. These are useful in estimating the extent of deformity. Also the extent of penetrating the ulcers with tracks can be seen in skiagrams.

Incidence of bone changes in leprosy was found to be 87.3% by Choudhuri et al and 82.9% by Thappa et al and Carayon et al reported that 60-80% had shown bone changes.^[6-9] Paterson (1955) found bone changes in 95% of cases and basis observed it to be 91% and 77% in 1962 and 1972 respectively.^[9] Chhabriya et al observed bone changes in all 50 cases they had studied,^[10] of which 17 cases showed specific lesions and 35 cases showed non-specific bone lesion.

In this study, the higher incidence of leprosy maybe due to the fact that most of our patients are manual workers, working in fields, where they get repeated trauma and develop secondary infection. Due to inadequate medical facilities and lack of knowledge about the disease, they ignore the trauma for a long time until deformity results.

Various deformities like trophic ulcers, loss of digits, contractures of digits. Muscle wasting nasal deformity and nerve thickening were more common among lepromatous and borderline patients in this study. Balachandra S et al observed trophic ulcer with radiological changes.^[11]

Nasal bone erosions were noted among 3(8.5%) out of 35 patients, whereas nasal bone resorption observed in a patient (2.8%). This may be attributed to specific infection by *M. Leprae* causing nasal deformity and secondary infection also plays a role and contributes to the subsequent development of deformity.

Chhabriya et al documented osteopetrosis in 50% of cases. Soft tissue changes like absorption,^[10] swelling and contractures were observed in 64% of cases. Ulcer tracks in the soles were observed in a few cases. Honey combing (40%) periostitis and ostetis (40%) and bone and joint destruction were most common of all specific in 32% and 36% of cases respectively. Less commonly observed findings were sclerosis. Enlargement of nutrient foramina and subarticular erosions were observed.

In the present study, 42.8% patient radiological changes were observed as both specific & nonspecific changes, 28.5% were nonspecific bone changes, 20% were Osteopetrosis and 8.5% were specific bone changes. Paterson observed in only 2-3% of his cases. He found honey combing,^[9] sclerosis and bone cysts to be relatively common. Chhabriya et al reported bone cysts, sclerosis etc., in 34% of cases.^[10]

Majority of patients affected with lesions on both hands (51.4%), one foot (37.1%) followed by one hand and one foot (25.7%) in the present study. Carl D Enna et al noted characteristic bone changes in small bones of hands and feet.^[12]

Almost all the patients showed non-specific bone changes in this study. Paterson observed it in 45% cases.^[9] Chhabriya et al found it in 66% of cases.^[10] Among these non-specific bone changes absorption of phalanges with involvement of terminal (72%) middles (60%) and proximal (40%) soft tissue changes (64%) concentric absorption, absorption of metatarsals or metacarpals.

Mende B et al reported radiological changes both nonspecific and specific.^[13] The specific bone changes were cystic brightenings and nonspecific bone changes as bone absorption including akroosterolysis and osteopetrosis.

In this study, Clinically 4 (11.4%) were tuberculoid, 14 (40%) were borderline, 15 (42.8%) lepromatous and 2 (5.7%) polyneuritic cases. Thappa et al,^[7] reported Nonspecific changes in Borderline tuberculoid, Borderline lepromatous, Lepromatous leprosy as 64.3%, 80% and 26.7% respectively. Whereas, Choudhuri et al,^[6] observed 76.5%, 50% and 100% nonspecific changes in BT, BL, LL respectively. Ankad Balachandra S et al,^[14] documented higher percentage of nonspecific changes among different types of leprosy, i.e., BT (96.6%), BL (91.6%) and LL (100%) and PN (100%) and 62% of the patients showed specific bone changes.

CONCLUSION

The most frequently involved part is foot. Other sites affected were hand, nose, ears and face. Many patients had deformities and trophic ulcers. Muscle wasting (small muscles of hand) was noted in a few cases. Thickening of the nerves was noted in most of the cases. Even though leprosy is an ancient disease, still worldwide leprosy cases are seen, responsible for major social issues. Once bone changes develops in leprosy patients, its difficult to treat patient and also need good rehabilitation resources. Early diagnosis and prompt treatment may help to avoid bony deformities.

REFERENCES

1. New Leprosy Bacterium: Scientists use Genetic Finger print To Nail Killing Organism. ScienceDaily. 2008-11-28. Archived from the original on 2010-03-13. Retrieved 2010-01-31.
2. <http://www.who.int/lep/situation/prevalence/en/>
3. WHO (1995). Leprosy disabilities: magnitude of the problem. Weekly Epidemiological Record. 70 (38): 269-75. PMID 7577430
4. Leprosy Fact Sheet N0101. World Health Organization. January 2014. Archived from the original on 2013-12-12.

5. Current status of leprosy: epidemiology, basic science and clinical perspectives. *The Journal of dermatology*. 39 (2): 121-9.
6. Choudhuri H, Thappa DM, Kumar RH, Elangovan S. Bone changes in leprosy patients with disabilities/deformities (A clinico-radiological correlation). *Indian J Lepr* 1999; 71 (2): 203-215.
7. Thappa DM, Sharma VK, Kaur S, Suri S. Radiological changes in the hands and feet in disabled leprosy patients: a clinico-radiological correlation. *Indian J Lepr* 1992; 64(1):58-66.
8. Carayon A, Dharmendra. Bone and joint changes in leprosy. In: Dharmendra, editor, *Leprosy*, Vol 2. Bombay: Samant and company; 1985;546-550.
9. Paterson DE. Radiological bone changes and angiographic findings in leprosy with special reference to the pathogenesis of 'atrophic' conditions of the digits. *Clinical radiology* 1955 July;7(1):35-36.
10. Chhabriya BD, Sharma NC, Bansal NK, Agrawal GR. Bone changes in leprosy. A study of 50 cases. *Indian J Lepr* 1985; 57 (3): 632-639.
11. Balachandra S Ankad, Rudresh S Halawar. Bone involvement in leprosy : Early changes. *Radiology of infectious diseases*. 2015 March;1(2):88-89.
12. Carl D Enna, Robert R, Jacobson, Robert O Rausch. Bone changes in Leprosy: A correlation of clinical and radiographic features. *Diagnostic radiology*. 1971 August;100(2).
13. Mende B, Stein G, Kreysel HW. Bone changes in Hansen's disease. *Rofo*. 1985 Feb;142(2):189-92.
14. Ankad Balachandra S, Hombal A, Rao Sudhakar, Naidu varma M. Radiological Changes in Hands and Feet in Leprosy Patients with Deformities. *Journal of Clinical Diagnostic Research*. 2016 March; 5(4):703-707.

How to cite this article: Reddy KB, Sreedevi L, Suryanarayana S. Study of Radiological Changes of Bones in Leprosy Patients. *Ann. Int. Med. Den. Res.* 2018; 4(1):DT05-DT08.

Source of Support: Nil, **Conflict of Interest:** None declared