

A Prospective Study of Nail Changes in Dermatological and Systemic Illnesses.

Sushil Rathi¹, Dharmendra Mishra², Sunil Chaudhari³

¹Associate Professor, Department Of Skin and V.D, Indira Gandhi Government Medical College, Nagpur- Maharashtra.

²Professor and Head, Department Of Skin and V.D, Indira Gandhi Government Medical College, Nagpur- Maharashtra.

³Senior Resident, Department Of Skin and V.D, Indira Gandhi Government Medical College, Nagpur- Maharashtra.

Received: February 2018

Accepted: February 2018

Copyright: © the author(s), publisher. It is an open-access article distributed under the terms of the Creative Commons Attribution Non-Commercial License, which permits unrestricted non-commercial use, distribution, and reproduction in any medium, provided the original work is properly cited.

ABSTRACT

Background: Some of the nail changes seen in certain dermatological or systemic pathologies may be unique to concerned condition. The knowledge of such nail changes may be immensely helpful in the diagnosis of some of these pathologies. Nail changes may precede other signs in some conditions and in these cases nail changes may help in early diagnosis. Various components of the nails which may get affected may include nail matrix, nail plate, nail bed and vasculature. We conducted this prospective study to know the prevalence of nail changes in various dermatological and systemic illnesses in patients attending dermatology outpatient department and patients admitted in different wards of our teaching institute. Aims and Objectives: (1) To study various nail changes in association with skin and systemic diseases. (2) To assess the diagnostic and prognostic significance of various nail changes. (3) To find out various etiological factors of the nail diseases. **Methods:** After approval from institutional ethical committee and obtaining informed consent from the patients nail changes were studied in patients attending dermatology OPD and those patients who were admitted in various wards of our institute. History, investigations and general and systemic examination was done in all the patients. Patients were included in this study on the basis of predefined inclusion and exclusion criteria. Nail and toes were examined for the changes such as dystrophy, ridging, thinning of nail plates, presence of Pterygium, pigmentation and onycholysis. The changes were studied and their association with skin and systemic diseases was determined. Data analysis was carried out using SPSS16.0 version software. **Results:** In this prospective study of 225 patients there were 142 males (63.1 %) and 83 females (36.9 %) with a M: F ratio of 1:0.58. Most common age group to be affected was found to be 21-30 years and 31-40 years followed by 41-50 years and 51-60 years. The most common nail change was found to be onychomycosis (31.1 %) followed by paronychia (16%), psoriasis (11.5 %) and nail dystrophy (8.8 %). Longitudinal ridging, thinning of nail plates, pitting, Pterygium and pigmentation were common changes seen in patients with lichen planus. **Conclusion:** Examining the patients for nail changes which may be seen in association with various dermatological and systemic conditions is an integral part of dermatology practice. These nail changes may precede the other signs and symptoms of the diseases and hence may be crucial in early diagnosis of such conditions.

Keywords: Nail changes, dermatological and systemic illnesses, nail plate, nail bed.

INTRODUCTION

The nail is an interesting part of the human body. Its functions consist of grasping small objects and to provide protection to the ends of the digits. It consists of flattened cells and keratin and is bound proximally by the eponychium laterally and distally by nail fold. It contains a high content of cystine disulphide bonds.^[1] Men and women down the ages have always been concerned about their nails. Every effort has been made by them to make nails colorful and attractive as a pink and lustrous nail has been equated with good health. Nails, like hairs, have been subjected to variety of onslaughts.^[2] The nail changes may be an early sign of skin and systemic

diseases and sometimes nails only may be affected. Thus examination of nails becomes necessary in each and every case.^[3]

The examinations of nails consist of examination of nail folds (color and shape), lunula (color and shape), nail bed, hyponychium and nail plate. The changes in nails may be a reflection of many dermatological or systemic disorders.^[4] The common findings like clubbing may suggest chronic conditions like infective endocarditis, cyanotic congenital heart disease, pulmonary diseases or even inflammatory bowel disease. Likewise spoon shaped nails (koilonychia) may be due to anemia or hemochromatosis.^[5] Onycholysis may be the feature of disorders like psoriasis, trauma or hyperthyroidism. In many cases connective tissue disorders may cause nail changes such as koilonychia and pitting of nails. Likewise Beau's lines may be present in any systemic illness that is severe enough to disrupt nail growth and may include the causes such as Raynaud's disease

Name & Address of Corresponding Author

Dr Sunil Chaudhari
Senior Resident
Department Of Skin and V.D,
Indira Gandhi Government Medical College
Nagpur- Maharashtra.

Pemphigus vulgaris and trauma.^[6] Telangiectasias may be present in cases suffering from rheumatoid arthritis, systemic lupus erythromatosus and trauma. In addition to clubbing, koilonychia, onycholysis and nail pitting various other nail abnormalities which can be commonly encountered in day to day dermatology practice may include Ptygium, Onychorrhexis (ridging), leuconychia, melanonychia, cyanosis, icterus and splinter hemorrhages.^[7]

Many opportunities to diagnose underlying systemic or dermatological conditions are lost because it is very rare in developing countries for a patient to consult a dermatologist for nail problems.^[8] It is therefore important from the point of view of a practicing dermatologist to be familiar with common nail findings and their association with dermatological and systemic illnesses. Such a familiarity on the part of a dermatologist will not only be helpful in deciding the workup but also limit the differential diagnoses and eventually lead to final diagnosis. It must also be mentioned that the nail problems are routinely under diagnosed and remain untreated for a long time because most of the patients perceive them to be not associated with any serious illness⁹. It is probably a life time work to see and collect all possible nail disorders.

We conducted this prospective study of 225 patients who either attended dermatology outpatient department or were admitted inwards of a tertiary care institute situated in an urban area. Our emphasis was on finding out the nail changes in various systemic and dermatological illnesses.

MATERIALS AND METHODS

The institutional ethical committee duly approved the study. All patients attending the outpatient department of dermatology and patients admitted in wards for various systemic illnesses were included in this study depending upon the inclusion and exclusion criteria. A total of 225 patients were included in this study after obtaining informed consent from them. All cases were studied in detail. Complete history and clinical examination was recorded as per a predefined proforma. In history, the presenting symptoms, duration and evaluation of nail changes were noted. Details regarding occupation, contact with certain chemicals, use of nail cosmetics and any particular habit were asked. History of associated skin and systemic disease was noted. In clinical examination, number of nails involved, change in color, luster, size, shape and surface of the nail plates were recorded. Changes in cuticle and nail folds, presence of onycholysis and subungual keratin deposition were also noted.

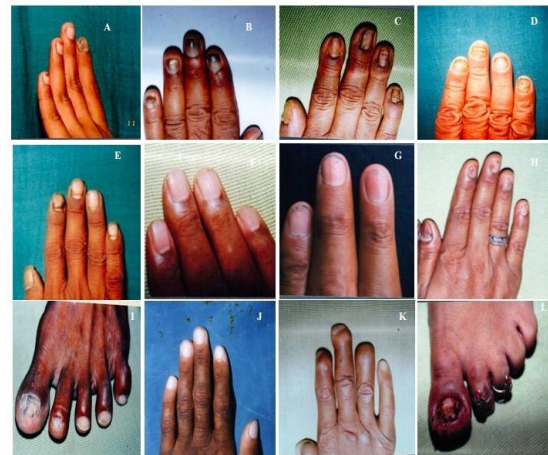

Figure 1: Common nail changes seen in the studied cases included (A) Subungual Warts (B) Onychomycosis (C) Chronic paronychia (D) Fingernail Onychomycosis (E) Beau's lines (F) Longitudinal Ridging (G) Nail pitting in psoriasis (H) Dystrophic nails in a patient with lichen planus (I) Toenail onychomycosis (J) Pallor on fingernails. (K) Leprosy (L) Acute Paronychia due to in-growing toenails.

Associated skin, mucous membrane and scalp lesions were also observed. General and systemic examination was done routinely. Haemogram, urine analysis, liver and renal function tests and blood sugar were carried out wherever indicated. Skin biopsy was done in patients having associated skin lesions. KOH smear for fungal examination was also carried out in patients suspected to have onychomycosis. After diagnosis was confirmed patients were treated accordingly. Specific as well as symptomatic treatment was instituted. Patients were also referred to medical, surgical, ENT, ophthalmology, gynecology departments for their concerned complaints. Patients receiving the treatment were followed up to observe any improvement in nail changes following the treatment. The results were studied using appropriate statistical methods. Data analysis was carried out using SPSS16.0 version software. Microsoft word and excel were used for generating charts and graphs.

Inclusion Criteria

1. Patient attending dermatology OPD for conditions affecting nails.
2. Patients attending dermatology OPD for other reasons but found to have nail changes.
3. Patients admitted in various wards of our institute and was incidentally found to be having nail changes.
4. Those patients who gave informed consent for being part of this study.

Exclusion criteria

1. The patient who refused consent.
2. Patients with Traumatic nail conditions.

RESULTS

This was a prospective study of 225 patients having conditions affecting the nails or the systemic conditions in which the nails were secondarily affected. Out of these 225 patients there were 142 males (63.1 %) and 83 females (36.9 %) with a M: F ratio of 1:0.58.

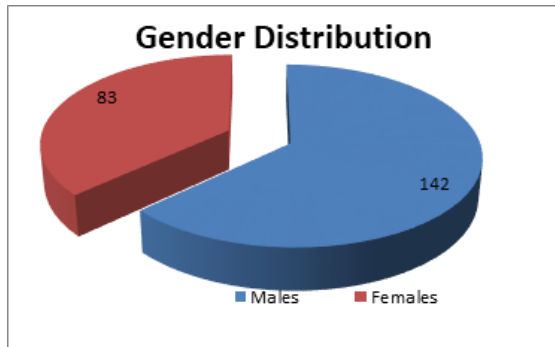


Figure 2: Gender Distribution of the studied cases.

The analysis of the age groups of the studied cases showed that the most common age group to be affected was found to be 21-30 years and 31-40 years followed by 41-50 years and 51-60 years.

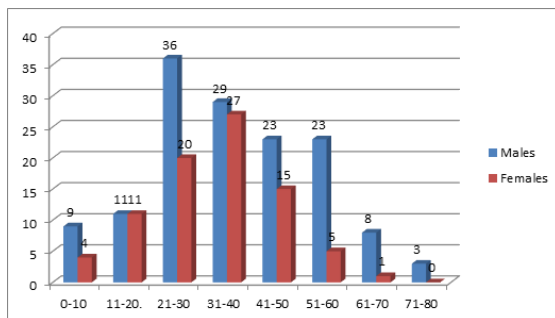


Figure 3: Age distribution of the studied cases.

The analysis of the patients on the basis of whether they had any associated mucous membrane, skin lesions or systemic illness showed that out of 225 patients 146 patients had associated lesion or systemic illness. Out of these 146 patients 122 (54.2 %) patients had either associated skin lesions or mucous membrane lesions and 24 patients had some systemic illness (10.6%).

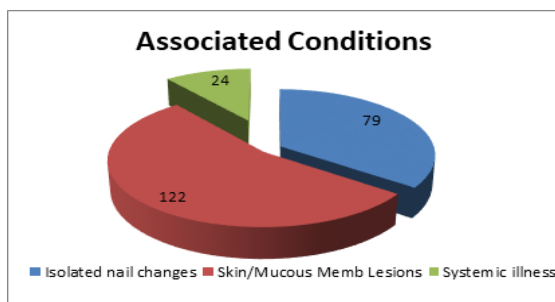


Figure 4: Skin, mucous membrane or systemic illness associated with nail changes.

The most common nail change was found to be onychomycosis (31.1 %) followed by paronychia (16%), psoriasis (11.5 %) and nail dystrophy (8.8 %) other less common forms of nail changes were also noted and is given in tabulated form below.

Table 1: Various Nail Changes in the studied cases.

Sr No	Name Of The Disorder	Males	Females	Total	Percentage
1	Onychomycosis	50	20	70	31.1 %
2	Paronychia	11	25	36	16 %
3	Psoriasis	24	2	26	11.5 %
4	Nail Dystrophy	12	8	20	8.8 %
5	Eczema	7	5	12	5.3 %
6	Warts	7	2	9	4 %
7	Lichen Planus	6	2	8	3.5 %
8	Melanonychia	4	2	6	2.6 %
9	Pemphigus	1	3	4	1.7 %
10	Koilonychia	2	2	4	1.7 %
11	Shedding Of Nails	2	1	3	1.3 %
12	Shiny Nail	3	0	3	1.3 %
13	Scleroderma	0	2	2	0.8 %
14	Erythroderma	2	0	2	0.8 %
15	Epidermolysis Bullosa	0	2	2	0.8 %
16	Idiopathic pitting	1	1	2	0.8 %
17	Nail Biting	2	0	2	0.8 %
18	Clubbing	2	0	2	0.8 %
19	Pellagra	0	2	2	0.8 %
20	Diabetes Mellitus	2	0	2	0.8 %
21	Alopecia Areata	1	0	1	0.4 %
22	Darier's disease	1	0	1	0.4 %
23	Leprosy	0	1	1	0.4 %
24	Striate Leuconychia	1	0	1	0.4 %
25	Half and Half Nail	0	1	1	0.4 %
26	Idiopathic Onycholysis	0	1	1	0.4 %
27	Jaundice	1	0	1	0.4 %
28	Ingrowing of toe nail	0	1	1	0.4 %
	Total	142	83	225	100 %

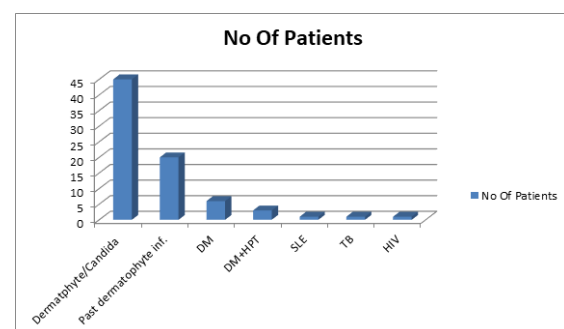


Figure 5: Associated conditions in patients with onychomycosis.

The analysis of the patients with onychomycosis showed that 70 patients had onychomycosis and out

of these patients 50 were males and 20 were females. Their ages ranged from 18-80 years and duration ranged from 1-20 years. 45 patients had either dermatophyte or Candida infection involving the skin while 20 patients had past history of dermatophyte infection of the skin. Out of these 70 patients 6 had diabetes mellitus, 3 had hypertension and diabetes. SLE, tuberculosis and HIV was seen in 1 patient each.

The analysis of patients with onychomycosis showed that DSLO was the most common type (61.4%) while proximal subungual OM (4.28%) was the least common type of OM. Fingernails were more commonly affected by toenails. KOH positive status was seen in 82.85% patients.

Table 2: Pattern of onychomycosis, pattern of nail involvement and KOH status.

Type Of Onychomycosis	Distal and Lateral Subungual OM	43	61.4 %
	Superficial white OM	20	28.5%
	Proximal Subungual OM	3	4.28%
	Candida OM	4	5.75%
	Total	70	100 %
Nail Involvement	Finger Nails Only	42	60.0 %
	Toe nails only	9	12.8 %
	Asymmetrical	16	22.8 %
	All Nails	3	4.3 %
	Total	70	100 %
KOH Status	KOH Positive	58	82.85 %
	KOH Negative	12	17.15 %
	Total	70	100 %

The analysis of fungus affecting the nails showed that Dermatophytes (80%) were the most common type of fungus involved followed by yeasts (20%). Amongst the isolated Dermatophytes and yeasts the most commonly found dermatophyte was T Rubrum (40%) followed by T Mentagrophytes and T.Tonsurans. Candida was found in 20 % patients.

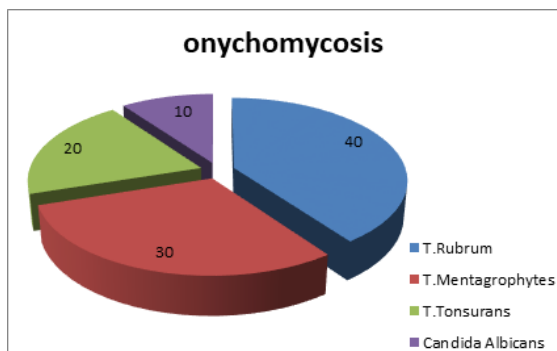


Figure 6: Species of Dermatophytes in the studied cases.

The analysis of the patients with paronychia showed that out of 36 patients with paronychia there were 11 males and 25 females. The ages of the affected patients ranged from 20-75 years. Out of these patients 6 had acute paronychia while 30 patients

had chronic paronychia. Right nail hands were affected more commonly than left hand. Amongst 36 patients 3 had finger or toe web space lesions, 4 had palmoplantar keratoderma while 2 had diabetes mellitus. All patients with paronychia were prescribed systemic antifungal/antibiotics and topical steroids, antifungal and antibiotic cream along with symptomatic treatment.

Table 3: Gender Distribution in the cases of paronychia.

Gender	No. Of Patients	Percentage
Males	11	30.55 %
Females	25	69.45 %

Psoriatic nail changes were found in 26 patients of which 24 were males and 2 were females. Their ages ranged from 8-66 years. All patients had body lesions of psoriasis. Among nail changes, 12 had yellowish discoloration, 3 had black. 3 had brown and 1 had white discoloration while 9 patients had no discoloration. Pitting was found in 23 patients, subungual hyperkeratosis was seen in 6, onycholysis in 6 and ridging was found in 18 patients. 1 patient had psoriatic arthritis. All patients were treated with steroid and keratolytic cream topically.

Table 4: Psoriatic Nail changes in the studied cases.

Nail Changes	No	Percentage
Pitting	23	88.46 %
Discoloration	20	76.92 %
SHK	6	23 %
Onycholysis	6	23 %
Ridging	18	69.23 %

In our study 20 patients had dystrophic nails of which 12 were males and 8 females. Of these, 8 were children and 12 were adults. Out of f these 20 patients, 2 had single nail involvement 10 had involvement of more than 10 nails while 8 had involvement of all nails. Among these, 1 had scalp psoriasis, 1 had eczema, 1 had lichen nitidus, 1 had S.J.syndrome, 2 had anemia and 1 had hypothyroidism. All patients were treated symptomatically. Total 12 patients had nail changes due to eczema, of these 7 were males and 5 were females. Contact dermatitis, atopic dermatitis and dyshydrotic eczema was seen in 9, 2 and 1 patients respectively. In almost all these patients, nail changes could be attributed to their occupation. Both finger and toe nails involvement was found. Eczema on hands and feet was present in all patients. Discoloration and ridging was the most common nail changes seen in eczema.

Table 5: Nail changes in patients with eczema.

Nail Changes	No	Percentage
Discoloration	7	88.46 %
Pitting	3	76.92 %
SHK	6	23 %
Onycholysis	2	23 %
Ridging	8	69.23 %

In present study, total 9 patients, 7 males and 2 females, were found to have periungual warts. Of these 3 were children and 6 were adults. Single nail involvement was found in 7 patients while in 2 patients 2 finger nails were involved. History of trauma to nail was present in 1, nail biting in 1 while 1 patient had warts on dorsum of hands. All patients were treated with liq. Salactin paint and cryotherapy. Lichen planus was seen in 8 patients (6 males and 2 females). The ages of the patients ranged between 8-80 years. 1 patient had hypertrophic lichen planus while remaining 7 patients had classical lichen planus. The most common nail changes seen in these patients were found to be longitudinal ridging and thinning of nail plate (6 patients each) followed by Pterygium, pigmentation and pitting.

Table 6: Nail changes in patients with Lichen Planus.

Nail Changes	No	Percentage
Longitudinal ridging	6	75 %
Thinning of nail plate	6	75 %
Pitting	1	12.5 %
Pterygium	2	25 %
Pigmentation	2	25 %

Total 6 patients, 4 males and 2 females had melanonychia. Of these 1 had transverse while 5 had longitudinal melanonychia. All nails were involved in 3 patients, only finger nails in 2 while only thumb nails were involved in 1 patient who was HIV positive. Diffuse pigmentation of skin was present in 1 patient while Knuckle pigmentation was present in 1 patient. Out of 4 patients who had pemphigus 1 was male and 3 were females. All patients were of pemphigus vulgaris which was confirmed by biopsy. All patients were treated with oral/injectable steroids. Dapsone was given in 2 patients while cyclophosphamide in 1 patient.

Beau's lines were found to be the most common nail abnormality associated with pemphigus. Koilonychia was seen in 4 patients. Of these 2 were males and 2 were females. All patients were anemic with Hb < 8 gm%. One patient had Mitral valve prolapse with mitral regurgitation and one patient had buccal mucosal pigmentation. 3 patients were found to have shedding of nails. 2 were 2 months old male infants while 1 was 44 years old female. No history of any skin or systemic disease was found in any of these patients. Shiny nails were found in 3 patients. All 3 were males. Two female patients had nail changes due to scleroderma. Only finger nails were involved. Both patients had shortening of finger nails. Two male patients had nail changes due to erythroderma. Both had psoriasis. All nails were involved. Yellowish discoloration and Beau's lines were present in both while pitting was present in one patient.

Two female patients were studied for nail changes due to epidermolysis bullosa. First was 12 years old who had h/o epidermolysis bullosa since birth and had involvement of both finger and toe nails. Second

was 42 years old who had h/o epidermolysis bullosa for 15 years and had involvement of toe nails only. Nails were dystrophic in both patients. Two patients had pitting of nails. One was male and the other was female. Both patients had involvement of finger nails only. None of these had any history of skin or systemic disease. Female patient had onycholysis also. Two patients had habit of nail biting. Both were males. First was 12 years old with involvement of right thumb nails only. Second was 37 years old with involvement of four right finger nails. No H/o. any psychiatric disorder was present in both. Two male patients had clubbing of finger nails. One had T.B. and other had H/o. bronchial asthma. Two female patients had nail changes due to pellagra. All nails were involved. Both patients were anemic and had pallor of nail bed. Two male patients had nail changes due to D.M. Both had longitudinal ridging involving both finger and toe nails. One male patient had H/o. alopecia areata for 2 years. Nail involvement showed pitting. Only finger nails were involved. One male patient had nail changes due to Dariers disease. Both finger and toe nails were involved. He had longitudinal ridging, thinning and brittleness of nails. No typical triangular nick was noted. One female patient having H/o. leprosy for 3 years had resorption of terminal phalanges of fingers and shortening of nails. One male patient had striate leuconychia involving left middle finger nail. One female patient had nail changes due to CRF. She had H/o hypertension for 8 years and CRF for 1 year. Finger nails showed proximal whitening and distal reddening. One female patient had onycholysis of finger nails. No h/o any skin lesion was present. One male patient having H/o jaundice for 1year had dystrophic finger nails. Lastly one female patient presented with acute paronychia of great toe nails due to in growing of toe nails.

DISCUSSION

This was a prospective study of 225 patients with nail changes due to either primary nail disease or secondary affection of nails in various systemic illnesses. Onychomycosis was found to be the most common pathology seen in these patients and out 70 (31.1%) patients were found to be having onychomycosis. Similar studies by Zaias N et al showed that 30 % patients were having onychomycosis⁹. Another study by Mahmoud G reported the prevalence of onychomycosis to be around 23 % across Europe.^[10] The incidence is more in warm and humid climate. The risk factors for onychomycosis included advanced age, diabetes mellitus, Immunosuppression due to any cause and family members with onychomycosis. It is one of the most difficult superficial infections and many of the patients never get cured completely. It is not only the eradication of the infection which is important but also re-infection needed to be prevented which

appears to be a difficult task because of the fact that in many of the patients many household family members are found to be simultaneously affected.^[11] As mentioned earlier the increasing age appears to be one of the risk factors for onychomycosis. In a prospective multicenter study to determine the epidemiology of onychomycosis Gupta et al found the prevalence of onychomycosis to be 8%.^[12] They further reported the prevalence of onychomycosis to be 18.2% in the patients with age more than 60 years while this prevalence was found to be 0.7% in patients younger than 19 years. In our study the most common age group affected by onychomycosis was found to be 31-40 years while Velez et al found the patients in between 50-70 years to be most commonly affected. In our study Dermatophytes were seen in 80% followed by yeasts which were seen in 20% patients. Other studies have reported different infections rate. Velez et al found dermatophyte infection in 18.8% patients while yeasts and saprophytes were seen in 33% and 17.2% patients respectively.^[13] Such a wide difference may be due to geographical and environmental conditions. In Our study *T. Rubrum* was found to be the most common offending fungus while Puri et al reported *T. Mentagrophytes* to be the most commonly involved fungus.^[14] In our study paronychia was the second most common nail change which was seen after onychomycosis with 16% patients affected by it. Females (69.45%) were found to be more commonly affected than males (30.55%). Similar female preponderance was reported by many authors including Chow E et al et al who reported that the Female: Male ratio to be 2.3 : 1. This female preponderance may be due to the fact that females are engaged in more household work like washing etc making them vulnerable for such infections.^[15] In our study psoriatic nail changes were seen in 26 patients out of which 24 were males and 2 were females. Nail matrix and nail bed both were affected by psoriasis. Nail matrix affection may be responsible for changes such as koilonychia, pitting and streaking while nail bed affection may be responsible for onycholysis, subungual hyperkeratosis and splinter hemorrhages.^[16] Similar findings were seen in the study conducted by MP Shah et al who reported that discoloration was seen in 93.3% of the patients with psoriasis. The other nail changes seen in patients with psoriasis were found to be ridging (66.6%), pitting (60%), and onycholysis (40%). Common nail changes in patients with eczema in our study were found to be ridging (66.6%) followed by discoloration (58.3%) and SHK (50%). Other less common changes seen in patients with eczema were found to be pitting (25%) and onycholysis (16.6%). Similar findings were reported in a study conducted by Wollina U et al.^[17] In our study common nail changes seen in patients with lichen planus were found to be longitudinal

ridging (75%) and thinning of nail plate (75%) followed by Pterygium (25%), and Pigmentation (25%). Tosti et al in their study of nail changes in patients with lichen planus found the common nail changes in these patients to be longitudinal ridging (66.6%) followed by thinning of nail plate (50%) and Pterygium (16.6%). Pigmentation was seen in relatively small number of patients (4.2%).^[18] Finally the nail changes in pemphigus, scleroderma, erythroderma, epidermolysis bullosa, pellagra and alopecia areata etc were seen in small number of patients. The nail changes in all these conditions were found to be similar to the changes found in the studies conducted by Holzberg et al and Rao S et al.^[19,20]

CONCLUSION

Examination of the nails is an integral part of dermatology practice. Various nail changes seen in association with various dermatological or systemic illnesses may not only aid in early diagnosis of some conditions but also may help in deciding targeted workup of the patients. Clinching the diagnosis of a systemic illness (collagen vascular diseases, lichen planus, iron deficiency anemia or psoriasis) can be possible if a dermatologist is aware of such nail changes.

REFERENCES

1. Gniadecka M, Faurskov Nielsen O, Christensen DH, Wulf HC. Structure of water, proteins, and lipids in intact human skin, hair, and nail. *J Invest Dermatol.* 1998 Apr 110(4):393-8.
2. Pinteala T, Chiriac AE, Rosca I, et al. Nail Damage (Severe Onychodystrophy) Induced by Acrylate Glue: Scanning Electron Microscopy and Energy Dispersive X-Ray Investigations. *Skin Appendage Disorders.* 2017;2(3-4):137-142.
3. Apolinar E, Rowe WF. Examination of human fingernail ridges by means of polarized light. *J Forensic Sci.* 1980 Jan;25(1):154-61.
4. Witkowska AB, Jasterzbski TJ, Schwartz RA. Terry's Nails: A Sign of Systemic Disease. *Indian Journal of Dermatology.* 2017;62(3):309-311.
5. Kumar V, Aggarwal S, Sharma A, Sharma V. Nailing the Diagnosis: Koilonychia. *The Permanente Journal.* 2012;16(3):65.
6. Braswell MA, Daniel CR 3rd, Brodell RT. Beau lines, onychomadesis, and retronychia: A unifying hypothesis. *J Am Acad Dermatol.* 2015 Nov;73(5):849-55.
7. Haber R, Khoury R, Kechichian E, Tomb R. Splinter hemorrhages of the nails: a systematic review of clinical features and associated conditions. *Int J Dermatol.* 2016 Dec;55(12):1304-1310.
8. Senet P, Fichel F, Baudot N, Gaitz JP, Tribout L, Frances C. [Nail-fold capillaroscopy in dermatology]. *Ann Dermatol Venereol.* 2014 Jun-Jul;141(6-7):429-37.
9. Zaias N, Rebell G. The successful treatment of *Trichophyton rubrum* nail bed (distal subungual) onychomycosis with intermittent pulse-dosed terbinafine. *Arch Dermatol.* 2004 Jun;140(6):691-5.
10. Ghannoum M, Isham N. Fungal Nail Infections (Onychomycosis): A Never-Ending Story? *Goldman WE, ed. PLoS Pathogens.* 2014;10(6):e1004105.

11. Pajaziti L, Vasili E. Treatment of Onychomycosis – a Clinical Study. *Medical Archives*. 2015;69(3):173-176.
12. Gupta AK, Jain HC, Lynde CW, Watteel GN, Summerbell RC. Prevalence and epidemiology of unsuspected onychomycosis in patients visiting dermatologists' offices in Ontario, Canada--a multicenter survey of 2001 patients. *Int J Dermatol*. 1997 Oct;36(10):783-7.
13. Vélez A, Linares MJ, Fenández-Roldán JC, Casal M. Study of onychomycosis in Córdoba, Spain: prevailing fungi and pattern of infection. *Mycopathologia*. 1997;137(1):1-8.
14. Puri DK, Sarin RC, Arora S. Pattern of Dermatophytes Affecting the Nails. *Indian J Dermatol Venereol Leprol*. 1978 Mar-Apr;44(2):91-94.
15. Chow E, Goh CL. Epidemiology of chronic paronychia in a skin hospital in Singapore. *Int J Dermatol*. 1991 Nov;30(11):795-8.
16. Schons KRR, Knob CF, Murussi N, Beber AAC, Neumaier W, Monticelo OA. Nail psoriasis: a review of the literature . *Anais Brasileiros de Dermatologia*. 2014;89(2):312-317. doi:10.1590/abd1806-4841.20142633.
17. Wollina U, Nenoff P, Haroske G, Haenssle HA. The Diagnosis and Treatment of Nail Disorders. *Deutsches Ärzteblatt International*. 2016;113(29-30):509-518.
18. Tosti A. The nail apparatus in collagen disorders. *Semin Dermatol*. 1991 Mar;10(1):71-6.
19. Holzberg M. Common nail disorders. *Dermatol Clin*. 2006 Jul;24(3):349-54.
20. Rao S, Banerjee S, Ghosh SK, Gangopadhyay DN, Jana S, Mridha K. Study of nail changes and nail disorders in the elderly. *Indian J Dermatol*. 2011 Sep-Oct;56(5):603-6.

How to cite this article: Rathi S, Mishra D, Chaudhari S. A Prospective Study of Nail Changes in Dermatological and Systemic Illnesses. *Ann. Int. Med. Den. Res*. 2018; 4(2):DT05-DT11.

Source of Support: Nil, **Conflict of Interest:** None declared