

Palatal Displacement of Maxillary Canines and Maxillary Transverse Dimensions.

Mohamad Aslam Baidar Gull¹, Mohammad Mushtaq², Samirah Maqbool³

¹MDS Orthodontics, Department of Orthodontics & Dentofacial Orthopaedics, Government Dental College & Hospital, Srinagar, J&K, India
²Professor and Head, Department of Orthodontics & Dentofacial Orthopaedics, Government Dental College & Hospital, Srinagar, J&K, India.

³BDS, Government Dental College & Hospital, Srinagar, J&K, India

Received: January 2018

Accepted: January 2018

Copyright: © the author(s), publisher. It is an open-access article distributed under the terms of the Creative Commons Attribution Non-Commercial License, which permits unrestricted non-commercial use, distribution, and reproduction in any medium, provided the original work is properly cited.

ABSTRACT

Background: The maxillary permanent canines play a key role in smile design. Any morphological defect or eruption anomaly, affecting the maxillary permanent canine has a negative impact on the smile and facial esthetics of the person. The purpose of this study was to examine whether a clinically significant association exists between maxillary transverse dimension and palatally displaced canines (PDC). **Methods:** Twenty-four subjects (8 males and 16 females) with PDC were matched to twenty-four subjects (8 males and 16 females) without PDC (control) for age, sex and posterior occlusion. Prior to any orthodontic treatment, a CBCT scan was taken on all the patients. On axial and coronal sections of CBCT images, the maxillary basal bone widths and interdental widths at the maxillary first premolars, second premolars and first molars were measured. **Results:** The maxillary basal bone widths and interdental widths at the maxillary first premolars, second premolars and first molars between the subjects with palatally displaced canines and the control group showed no statistically significant differences in their means, thus indicating that there was no statistically significant difference in maxillary transverse dimensions between the affected subjects and the control subjects. **Conclusion:** Skeletal and dental maxillary transverse width was not related to the occurrence of palatally displaced canine. Thus, affected patients exhibit adequacy of maxillary dental arch width.

Keywords: Maxillary canines, maxillary transverse dimension, palatal displacement.

INTRODUCTION

Impaction has been defined in many ways by various authors. According to Raghoebar, impaction can be defined as “cessation of eruption of a tooth caused by a physical barrier in the eruption path or the abnormal position of the tooth” while Richardson defined it as “teeth with a delayed eruption time or that are not expected to erupt completely based on clinical and radiographic assessment”.^[1,2] The maxillary permanent canine is second most common tooth to be impacted after mandibular third molars.^[3] Impacted canine in the palatal position occurs 3 to 6 times more often than buccal position.^[4] Impacted canines are twice as common in women as in men, and the incidence in the maxilla is more than double compared to mandible.^[5] According to Dewel, “maxillary canine

is the most interesting from development point of view than any other tooth”.^[6] The canine develops deep in maxilla, follows the longest path of eruption, and erupts into the occlusal plane only after the adjacent teeth do. In a three-dimensional study of the eruption pattern of the canine, Coulter and Richardson found that the maxillary canine travelled 22 mm during its course of eruption. It is not surprising, then, that ectopic eruption or impaction of the maxillary canine is a frequently encountered tooth malposition.^[7]

The etiology of palatally impacted canines, also known as palatally displaced canines (PDCs) is not well understood. Two theories have been presented so far that might explain the PDC phenomenon. The first theory is the guidance theory which proposes that local factors, such as absent lateral incisors, peg-shaped lateral incisors, and supernumerary teeth, can interfere with the path of eruption of maxillary canines.^[8] The second theory postulates that genetics is responsible for PDC. Peck and Peck reported that PDC often occurs with other dental anomalies.^[9] PDC also occurs in families, suggesting a heredity component. The review article by Richardson and Russell, on diagnosis and prevention of impacted maxillary

Name & Address of Corresponding Author

Dr. Mohamad Aslam Baidar Gull
 MDS Orthodontics,
 Department of Orthodontics & Dentofacial
 Orthopaedics,
 Government Dental College & Hospital,
 Srinagar, J&K, India

Gull et al; Palatal Displacement of Maxillary Canines and Maxillary Transverse Dimensions

canines, points out that inadequate arch space is associated more with labial canine impaction rather than palatal impaction.^[2]

In addition to these two theories, many investigators have been trying to uncover a relationship between occurrence of PDC and the width of the maxilla, both skeletally and dentally. Langberg and Peck examined pretreatment dental casts of patients with PDC and found no significant difference in the arch width between the PDC and control group.^[10] Another study by Al-Nimri and Gharaibeh on pretreatment dental casts of patients with PDC showed that patients with PDC have greater maxillary transverse dimensions than the control group.^[11] More recently, Yan et al. examined the pretreatment CBCT of patients with PDC and found there was no correlation between the maxillary skeletal width and PDC.^[12]

The purpose of this study was to determine whether there is a difference in maxillary skeletal and dental transverse dimensions between subjects with PDC and subjects without PDC using cone beam computed tomography.

MATERIALS AND METHODS

Subjects

The study was carried out on the patients visiting the out-patient section of the Department of Orthodontics and Dentofacial Orthopaedics, Government Dental College & Hospital, Srinagar. All patients were at least 11 years old. The exclusion criteria were history of orthodontic treatment, missing or supernumerary maxillary incisors, congenital anomalies like cleft lip and palate. Pretreatment CBCT images of 24 patients with PDC (PDC group) and 24 subjects without PDC (control group) were selected from the department. The PDC group consisted of 8 males and 16 females. The age range in the PDC group was from 11 to 35 years, and the mean age was 21.2 years. Palatal impactions of the canine presented both unilaterally and bilaterally. Each patient in the PDC group was matched with one control by gender, age and posterior occlusion. The control group also contained 8 males and 16 females. The age range in the control group was from 11 to 38.4 years, and the mean age was 20.4 years. The data was obtained using the NewTom GiANO NNT Scanner with the patient in upright position and head positioned along the Frankfort horizontal plane, running parallel to the floor. All the scans were taken using the same machine by the same operator. The operating parameters were set at 3mA and 90kV, dose of 80-100 μ Sv and the scan time of 9 seconds. All CBCT images were taken using a limited dentoalveolar field of view (FOV: 8cm \times 8cm and 8cm \times 11cm).

Methods

All CBCT images were oriented and standardized using the software provided by the manufacture. In the frontal and right lateral views, each image was oriented in three planes of space. In the frontal view, the head was positioned with the floor of the orbits parallel to the floor. In the right lateral view, the Frankfort horizontal line (upper rim of external auditory meatus, Porion, to the inferior border of the orbital rim, Orbitale) was adjusted so that it was parallel to the floor. After these steps were completed, the skull's position was saved and set as the default position throughout this study. All data were calculated from this new default position of the patient's three-dimensional skull. Evaluation of the parameters was based on the identification and registration of a series of points. First, points I and II were reference points that represented the level of basal bone of the maxilla. In the frontal view, these two landmarks were plotted on the right and left sides of the skull and were defined as the most superior aspect of the concavity of the maxillary bone as it joined the zygomatic process [Figure 1].

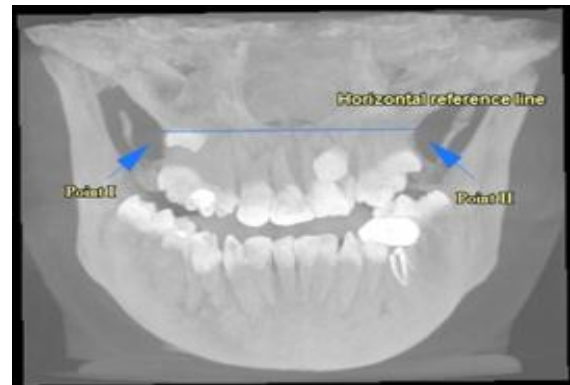

Figure 1: Reference points I and II on the frontal view of the skull, defined as the most superior aspect of the concavity of the maxillary bone as it joined the zygomatic process. A horizontal reference plane is drawn parallel to the floor through points I and II.

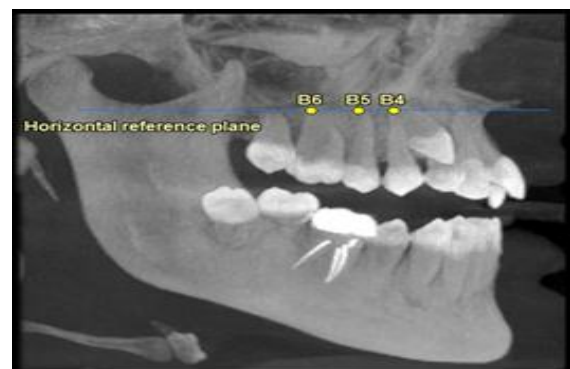

Figure 2: The right lateral view of the skull, illustrates points S4, S5, and S6 on the horizontal reference plane. Point B4 was marked directly above the midpoint of the maxillary first premolar. Point B5 was marked directly above the midpoint of the second premolar. Point B6 was marked directly above the midpoint of the first molar.

Gull et al; Palatal Displacement of Maxillary Canines and Maxillary Transverse Dimensions

A horizontal reference plane was drawn parallel to the floor from point I to point II. In the right lateral view, points B4, B5, and B6 were marked on the horizontal reference plane above the centre of the clinical crowns of the first premolar, second premolar, and maxillary first molar, respectively [Figure 2].

This same method was used to construct points B4', B5', and B6' from the left lateral view. In the axial view, the maxillary basal bone width was measured at the level of first premolars (the distance between points B4 and B4'), the second premolars (the distance between points B5 and B5'), and the first molars (the distance between points B6 and B6') [Figure 3].

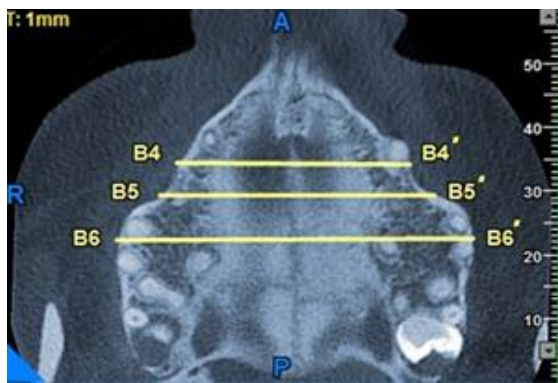


Figure 3. An axial section of the horizontal reference plane. B4, B4', B5, B5', B6, and B6' were located on the horizontal reference plane and on the cortical outline of the maxilla. Maxillary skeletal widths were measured as B4–B4', B5–B5', and B6–B6'.

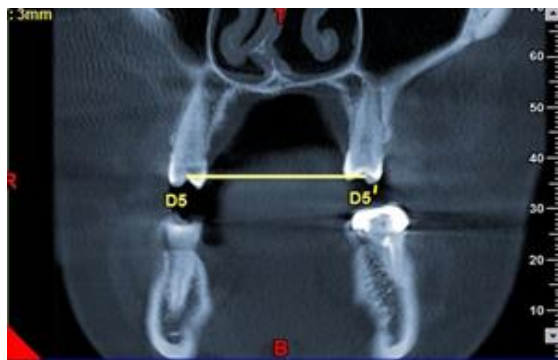


Figure 4: Coronal section of the skull at the central fossae of the maxillary second premolars. The section thickness was 3mm to reveal most of the dental crown. D5 represents the right second premolar's central fossa. D5' represents the left second premolar's central fossa. This same method was utilized for the first premolars (D4, D4') and first molars (D6, D6').

A second set of data measured the maxillary transverse dimensions dentally. In the frontal view, coronal sections were made through the central fossae of the maxillary first premolars, second premolars, and first molars. The thickness of each coronal section was adjusted to 3 mm in order to

get most of the dental crown structure. The right and left central fossae of the maxillary first premolars were marked as D4 and D4', the second premolars as D5 and D5', and the first molars as D6 and D6', respectively. The maxillary dental width was measured at the level of the first premolars (the distance between points D4 and D4'), the second premolars (the distance between points D5 and D5'), and first molars (the distance between points D6 and D6') [Figure 4]. All measurements were expressed in millimeters (mm).

Statistical analysis

The recorded data was compiled and entered in a spreadsheet (Microsoft Excel) and then exported to data editor of SPSS Version 20.0 (SPSS Inc., Chicago, Illinois, USA). Continuous variables were summarized in the form of mean and standard deviations and categorical variables were summarized as percentages. The paired t-test was used to determine whether the differences in the measurements between the PDC group and the control group were significant. To test intraexaminer reproducibility, 12 images were randomly selected and remeasured 2 weeks later by the same examiner. The paired t-test was used to determine whether the initial and repeated measurements showed any significant differences. A P-value of less than 0.05 was considered statistically significant.

RESULTS

Out of 24 patients in the PDC group, 8 (33%) were male subjects and 16 (67%) female subjects. Same was true for control group. Among 24 patients in the PDC group, 15 patients (62.5%) had a unilateral PDC and 9 patients (37.5%) presented with bilateral PDCs [Table 1].

Table 1: Description of the Palatally Displaced Maxillary Canines (PDC) Group and Control Group

	PDC group (n = 24)	Control group (n = 24)
Male:Female, No. (%)	8 : 16 (33 :67)	8 : 16 (33 : 67)
Unilateral:Bilateral, No. (%)	15 : 9 (62.5 : 37.5)	N/A

[Table 2] shows the maxillary measurements of the skeletal and dental transverse widths of both the PDC and control groups. No significant relationship was found between PDC and the maxillary skeletal transverse dimensions at the levels of the maxillary first premolars, maxillary second premolars, and maxillary first molars. Similarly, no significant relationship was found between PDC and the maxillary transverse dimensions dentally at the level of the maxillary

Gull et al; Palatal Displacement of Maxillary Canines and Maxillary Transverse Dimensions

first premolars, maxillary second premolars, and maxillary first molars.

Table 2: Skeletal and Dental Width Measurements of Palatally Displaced Maxillary Canines (PDC) and Control Groups

Measurements (Skeletal & Dental)	PDC group, in mm			Control group, in mm			P Value
	n	Mean	SD	n	Mean	SD	
B4-B4'	2 4	37.3 4	3.7 0	2 4	37.2 2	3.3 6	0.90
B5-B5'	2 4	48.8 2	3.9 4	2 4	49.1 8	4.1 2	0.75
B6-B6'	2 4	59.1 6	3.0 4	2 4	59.7 6	2.8 4	0.48
D4-D4'	2 4	35.2 2	4.6 2	2 4	35.6 2	2.0 8	0.70
D5-D5'	2 4	39.6 4	2.9 6	2 4	39.3 0	1.9 6	0.64
D6-D6'	2 4	44.5 8	2.5 4	2 4	44.2 4	1.8 6	0.59

B4-B4', B5-B5', and B6-B6', skeletal width at maxillary first premolar, second premolar, and first molar, respectively; D4-D4', D5-D5', and D6-D6', interdental width measured at central fossae of maxillary first premolar, second premolar, and first molar, respectively; SD indicates standard deviation

DISCUSSION

Radiographic examination before the age of 11 years does not provide a reliable prognosis of the maxillary canine eruption path as the root of the maxillary canine starts to migrate buccally and occlusally at the age of 10 years.^[13,14] So patients only over 11 years of age were included in this study.

In this study, the most prevalent gender was females, confirming that the impacted upper canines are produced twice as common in women than in men, with a ratio of 2 or 3 to 1.^[15,16] One main reason because the women were more prevalent in this sample added to etiologic factor is probably the mere fact that women are esthetically more oriented to get orthodontic treatment.

The present study showed that the skeletal transverse widths of the maxilla in the PDC group were not different to those in the control group at the first premolar, second premolar, and first molar levels. Therefore, it is concluded that the maxillary transverse width, skeletally, was not an etiologic factor contributing to the presence of PDC. This finding was in agreement with those of Yan et al and Saiar et al.^[12,16] The results of the study also indicated that there was no significant difference, dentally, in the interpremolar and intermolar widths between the PDC and control groups. Similar results were reported by Langberg and Peck, Yan et al and Saiar et al.^[10,12,16] In contrast, Al-Nimri and Gharaibeh found that PDC occurred more frequently in the Class II division 2 malocclusions

and in those with larger intermolar and interpremolar widths.^[11]

McConnell et al did a study in which he compared 57 subjects with 81 impacted canines to 103 subjects without impacted canines. Intercanine and intermolar widths were done on diagnostic casts. These authors concluded that patients with impacted maxillary canines have transverse deficiencies in the anterior portion of the arch.^[17] They suggested that expansion therapy might decrease the need for extraction and possibly prevent PDC. It was also suggested that young patients with an intercanine-to-intermolar ratio of 0.8 or less would be candidates for expansion therapy. Baccetti et al. reported that rapid maxillary expansion in the early mixed dentition lowered the incidence of PDC.^[18] Langberg and Peck believed that there is strong evidence pointing to genetics as the underlying cause of PDC and that maxillary arch width is not the primary contributory factor in PDC anomaly.^[10] However, they agreed that intra-arch dental measurements might not be a valid measurement of maxillary skeletal transverse dimensions. To predict impaction of maxillary permanent canines, Sambatro et al took PA cephalograms of 43 patients at 8 years of age and repeated again at 14.3 years of age for the same patients. They reported a wider posterior hemi maxilla and less distance between the crown of the unerupted canine and mid sagittal plane, for patients who later developed maxillary canine impaction.^[19]

Thus our study does not corroborate the conclusions of McConnell et al but supports the hypothesis of Langberg and Peck that maxillary skeletal width is not a primary contributory factor in PDC. Further investigation into the etiology of PDC is needed before clinical recommendations can be made to prevent PDC.^[10,17]

CONCLUSION

Skeletal and dental maxillary transverse width was not related to the occurrence of palatally displaced canine.

REFERENCES

1. Raghoobar GM, Boering G, Vissink A, Stegenga B. Eruption disturbances of permanent molars: a review. *J Oral Pathol Med* 1991; 20: 159-66
2. Richardson G, Russel KA. A Review of Impacted Permanent Maxillary Cuspids: diagnosis and prevention. *J Can Dent Assoc* 2000; 66: 497-501.
3. Shah RM, Boyd MA, Vakil TF. Studies of permanent tooth anomalies in 7,886 Canadian individuals. I: Impacted teeth. *Dent J* 1978; 44: 262-4.
4. Walker L, Enciso R, Mah J. Three-dimensional localization of maxillary canines with cone beam computed tomography. *Am J Orthod Dentofac Orthop.* 2005; 128:418-23.

Gull et al; Palatal Displacement of Maxillary Canines and Maxillary Transverse Dimensions

5. Jacoby H. The etiology of maxillary canine impactions. A clinical and radiologic study. *Am J Orthod Dentofac Orthop.* 1983;84:125–32.
6. Dewel BF. The upper cuspid: its development and impaction. *Angle Orthod* 1949;19:79-90.
7. Coulter J, Richardson A. Normal eruption of the maxillary canine quantified in three-dimensions. *Eur J Orthod* 1997;18:444-56.
8. Brin I, Becker A, Shalhav M. Position of the maxillary permanent canine in relation to anomalous or missing lateral incisors: a population study. *Eur J Orthod* 1986;8:12-16.
9. Peck S, Peck L, Kataja M. The palatally displaced canine as a dental anomaly of genetic origin. *Angle Orthod* 1994;64:249-56.
10. Langberg BJ, Peck S. Adequacy of maxillary dental arch width in patients with palatally displaced canines. *Am J Orthod Dentofacial Orthop.* 2000;118:220–223.
11. Al-Nimri K, Gharaibeh T. Space conditions and dental and occlusal features in patients with palatally impacted maxillary canines: an aetiological study. *Eur J Orthod.* 2005;27:461–465.
12. Yan B, Sun Z, Fields H, Wang L, Luo L. Etiologic factors for buccal and palatal maxillary canine impaction: a perspective based on cone-beam computed tomography analyses. *Am J Orthod Dentofacial Orthop.* 2013;143:527–534.
13. Ericson S, Kurol J. Radiographic examination of ectopically erupting maxillary canines. *Am J Orthod Dentofacial Orthop.* 1987;91:483–492
14. Ericson S, Kurol J. Longitudinal study and analysis of clinical supervision of maxillary canine eruption. *Community Dent Oral Epidemiol.* 1986;14:172–176.
15. Dachi SF, Howell FV. A study of impacted teeth. *Oral Surg Oral Med Oral Pathol.* 1961;14:1165–9.
16. Sairar M, Rebellato J, Sheats RD. Palatal displacement of canines and maxillary skeletal width. *Am J Orthod Dentofacial Orthop.* 2006;129:511–519.
17. McConnell TL, Hoffman DL, Forbes DP, Janzen EK, Weintraub NH. Maxillary canine impaction in patients with transverse maxillary deficiency. *J Dent Child* 1996;63:190-5.
18. Baccetti T, Mucedero M, Leonardi M, Cozza P. Interceptive treatment of palatal impaction of maxillary canines with rapid maxillary expansion: a randomized clinical trial. *Am J Orthod Dentofacial Orthop.* 2009;136: 657–661.
19. Sambataro S, Baccetti T, Franchi L, Antonini F. Early Predictive Variables for Upper Canine Impaction as Derived from Posteroanterior Cephalograms. *Angle Orthod* 2005; 75: 28-34

How to cite this article: Gull MAB, Mushtaq M, Maqbool S. Palatal Displacement of Maxillary Canines And Maxillary Transverse Dimensions. *Ann. Int. Med. Den. Res.* 2018; 4(2):DE09-DE13.

Source of Support: Nil, **Conflict of Interest:** None declared