

A New Single Wire Technique for Intermaxillary Fixation – Easy Way Out.

Abhishek Bhattacharjee¹, Abhishek Khatua¹, Vinod Kumar¹, Prashanth R², Rudresh K B³

¹Post Graduate Student, Department of Oral and maxillofacial Surgery, Vokkaligara Sangha Dental College and Hospital, Bangalore.

²Senior Lecturer, Department of Oral and maxillofacial Surgery, Vokkaligara Sangha Dental College and Hospital, Bangalore.

³Reader, Department of Oral and maxillofacial Surgery, Vokkaligara Sangha Dental College and Hospital, Bangalore.

Received: October 2017

Accepted: November 2017

Copyright: © the author(s), publisher. It is an open-access article distributed under the terms of the Creative Commons Attribution Non-Commercial License, which permits unrestricted non-commercial use, distribution, and reproduction in any medium, provided the original work is properly cited.

ABSTRACT

Intermaxillary fixation (IMF) plays an important role in the treatment of maxillofacial fracture. The most preferred way is upper and lower arch bar fixation or eyelet wiring and IMF done by box wiring. Here we present a new type of IMF technique, using 26 gauge stainless steel cut into 6cm length single wire technique. It is a single, quick, economical, minimal invasive and easy technique without any arch bar or eyelet fixation. Indication for this kind of wiring is undisplaced or minimally displaced fractures, stabilization of fractures during open reduction and internal fixation, orthognathic surgery and in tumor resection surgeries.

Keywords: Faciomaxillary fracture. maxillomandibular fixation, single wire, easy technique

INTRODUCTION

Intermaxillary fixation is an important procedure in the treatment of maxillofacial fracture and is done by wiring together the upper and lower teeth which in turn serve for the maxillo-mandibular fixation.^[1,2] Different IMF techniques have evolved, commonly used are arch bar fixation, eyelet wiring etc., All these techniques have some merits and demerits. The disadvantages include long procedure time, excess trauma, cost factor.^[3] Here we present a new IMF technique using a single wire which is simple and efficient.

Technique

In this technique a prestretched single 26 gauge stainless steel wire of 6 inches is taken. First the wire is passed around the buccal surface of maxillary teeth to palatal aspect, with one end of the wire from the mesial side and the other end from the distal. Now the both ends are held with a wire twister from the palatal side and brought down to the lingual side of the subsequent mandibular teeth. Both ends of the wire are now crossed over so that the distal end comes mesially and vice versa. The ends of the wire are inserted through the

the other side of the arch. Now the maxillary-mandibular teeth are occluded to the desired occlusion and the ends of the wire are twisted together at the buccal surface. Excess wires are cut and rosettes are made in the interdental cervicogingival level. Following which further procedures (Open Reduction Internal Fixation, Orthognathic surgery etc.) can be carried out and then the wires can be easily removed with very little trauma.

CASE REPORT

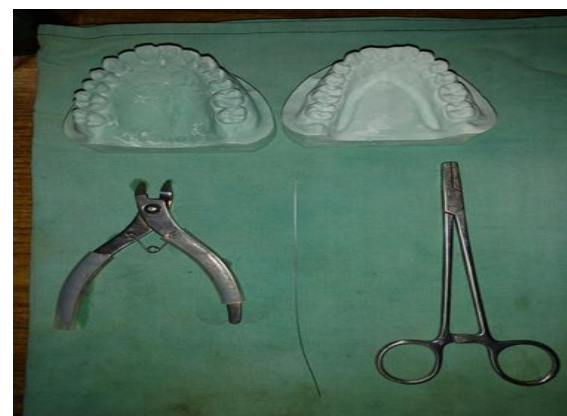

Figure 1: Armamentarium required for wiring in the models (26 gauge : 6 inch prestretched wire, wire tweester, wire cutter)

Name & Address of Corresponding Author

Dr Abhishek Bhattacharjee,
Post Graduate Student,
Department of Oral and maxillofacial Surgery,
Vokkaligara Sangha Dental College and Hospital,
Bangalore.

interdental space and brought out to the buccal side of the mandibular teeth. The same is repeated on

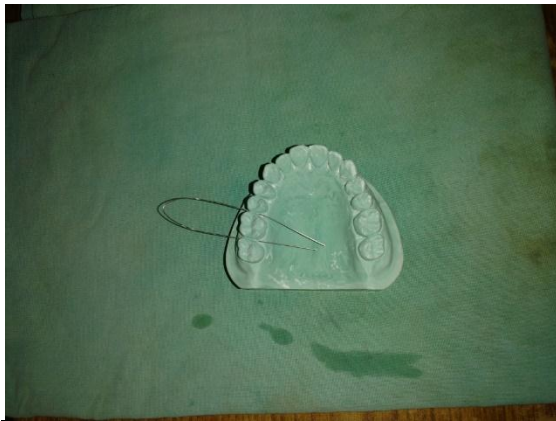

Figure 2: The wire passed from buccal to lingual aspect in the maxillary tooth.




Figure 3: Crossover of the wire ends done in the lingual aspect for better girdling of the teeth. 3A: Left side. 3B: Right side

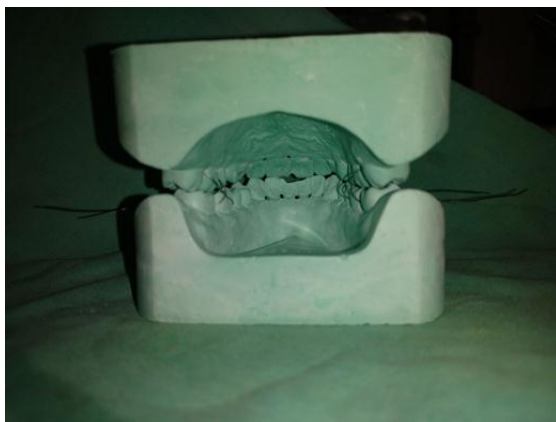


Figure 4: Bilateral crossover of wires

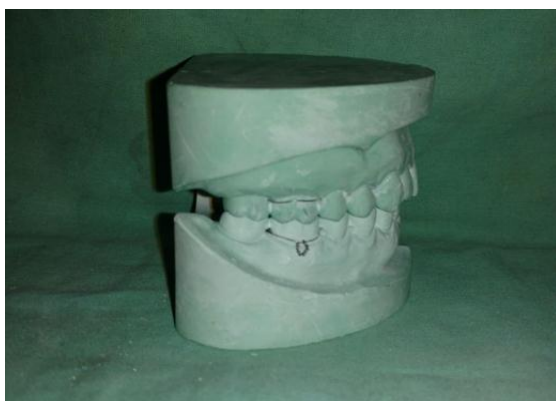

Figure 5: Wire twisted together and rosette was made at the cervico-gingival region and IMF achieved.

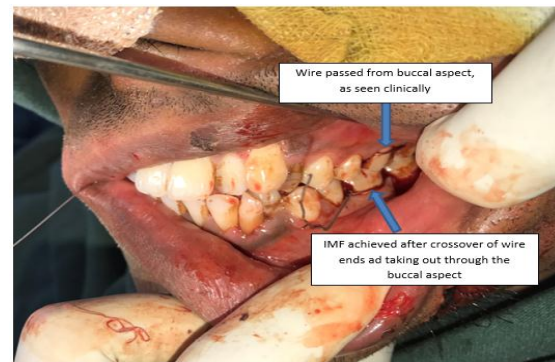


Figure 6: Single wire technique reproduced on patient, clinical photograph.

DISCUSSION & CONCLUSION

Intermaxillary fixation plays an important role as it can be used as a guide to fracture reduction.^[2] Different intermaxillary fixation technique have been used like, ivy loop wiring, extended eyelet method, a wired arch bar, an acrylated arch bar, Dimac wire, a bonded arch bar, thermoforming plates, bone screws system.^[2] Virendra et al, Verma et al., have designed other technique which are easy and cost effective, even intermaxillary fixation with sutures have also been proposed.^[1-4] In this technique the crossover of wire gives a 360 degree embrace over the tooth thereby increasing the surface area of the wire in contact with the tooth. This in turn increases the amount of friction between the tooth and wire, thus decreasing the chance of wire slippage. Thus this simple wiring technique gives a better occlusion and stability with intermaxillary fixation.

REFERENCES

1. Pappachan B (2010). Intermaxillary fixation with buccolingual stabilization. *J Maxillofac Oral Surg* 9(2):159–161
2. Singh V, Bhagol A, Kumar I (2010) A new and easy technique for maxillomandibular fixation. *Natl J Maxillofac Surg* 1(1):24–25
3. Verma A, Yadav S, Dhupar V. A New Simplified technique for intermaxillary fixation by loop designed wire. *Journal of maxillofacial and oral surgery*, 2015.14(2).499-500
4. Rai A. Intermaxillary fixation with sutures: RAI Modification. *British Journal of Oral and Maxillofacial Surgery* :55(4); 2017, 21-22

How to cite this article: Bhattacharjee A, Khatua A, Kumar V, Prashanth R, Rudresh KB. A New Single Wire Technique for Intermaxillary Fixation – Easy Way Out. *Ann. Int. Med. Den. Res.* 2018; 4(1): DE12-DE13.

Source of Support: Nil, **Conflict of Interest:** None declared