

# Impacted Maxillary Canines Increase External Root Resorption Of Adjacent Incisors: Physical Proximity A Predisposing Factor.

Mohamad Aslam Baidar Gull<sup>1</sup>, Mohammad Mushtaq<sup>2</sup>

<sup>1</sup>MDS Orthodontics, Department of Orthodontics & Dentofacial Orthopaedics, Government Dental College & Hospital, Srinagar, J&K, India

<sup>2</sup>Professor and Head, Department of Orthodontics & Dentofacial Orthopaedics, Government Dental College & Hospital, Srinagar, J&K, India.

Received: November 2017

Accepted: December 2017

**Copyright:** © the author(s), publisher. It is an open-access article distributed under the terms of the Creative Commons Attribution Non-Commercial License, which permits unrestricted non-commercial use, distribution, and reproduction in any medium, provided the original work is properly cited.

## ABSTRACT

**Background:** The maxillary canines are of great importance both aesthetically and functionally. Ectopic eruption of maxillary canines cause various complications among which root resorption of adjacent incisors is most common. **Objective:** The objectives of this study were to investigate the prevalence, extent of resorption, and predisposing risk factors for incisor root resorption associated with impacted maxillary canines. **Methods:** Unilaterally and bilaterally impacted canines (n=53) from 42 patients (27 female, 15 male) who visited Department of Orthodontics for treatment were evaluated. CBCT scans were taken with NewTom GIANO NNT Scanner keeping in mind the risks associated with ectopic eruption of maxillary canines and were analyzed with 3D visualization software. **Results:** Among the studied impactions, 79.2% were impacted palatally and 11.3% buccally. The lateral incisors were the teeth most affected by resorption. 18 incisors were resorbed, which included 16 lateral incisors (30.2 per cent) and 2 central incisors (3.8 per cent). Among lateral incisors, the resorption was slight in 11 cases (20.8 per cent), moderate in 3 cases (5.6 per cent), and severe in 2 cases (3.8 per cent) while among central incisors, the resorption was only slight in 2 cases (3.8 per cent). A correlation was found between the proximity/contact of the impacted canine to the incisors and their resorption. Follicle size did not play a major role in incisor resorption. **Conclusion:** Canine impaction poses a higher risk for root resorption of adjacent incisors. Physical proximity (<0.5 mm) between impacted canine and adjacent roots of incisors is the most important predictor for root resorption. The width and the shape of the dental follicle of the impacted canines do not correlate with root resorption of maxillary incisors.

**Keywords:** External root resorption, impacted maxillary canine, physical proximity.

## INTRODUCTION

Impaction is defined as failure of eruption of a tooth into the appropriate position in the dental arch within the time and physiological limits of the normal eruption process.<sup>[1]</sup> After third molars, the maxillary canine is the second most frequently impacted permanent tooth with a prevalence of 1–3 per cent.<sup>[2,3]</sup> The maxillary canines are of great importance both aesthetically and functionally. Apart from causing aesthetic and functional problems, ectopic eruption of maxillary canines cause various complications such as root resorption of adjacent teeth especially lateral incisors, follicular cyst formation and also recurrent infection and pain.<sup>[4]</sup> Root resorption is the most

common complication of impacted maxillary canines and it may lead to loss of tooth also.<sup>[5]</sup>

In order to reduce complications due to impacted maxillary canines, early detection of impaction and diagnosis and assessment of extent of resorption is of great value regarding various treatment options.<sup>[6]</sup>

Root resorption on the teeth adjacent to maxillary impacted canines is very difficult to diagnose because of general absence of symptoms of resorption and reliance of clinician on two-dimensional radiographic imaging, especially when the resorption is present palatally or buccally.<sup>[7]</sup>

Cone Beam Computed Tomography (CBCT) is a new three-dimensional imaging technique that recently became increasingly important in diagnosis and treatment planning in dentistry. It has significantly improved the sensitivity and accuracy of the diagnosis of root resorption.

Many risk factors have been attributed to root resorption associated with impacted maxillary canines. Based on two-dimensional radiographic imaging, specific canine location (mesial to the midroot axis of the lateral incisor) and angulation

### Name & Address of Corresponding Author

Dr. Mohamad Aslam Baidar Gull,  
MDS Orthodontics, Department of Orthodontics &  
Dentofacial Orthopaedics,  
Government Dental College & Hospital,  
Srinagar, J&K, India.

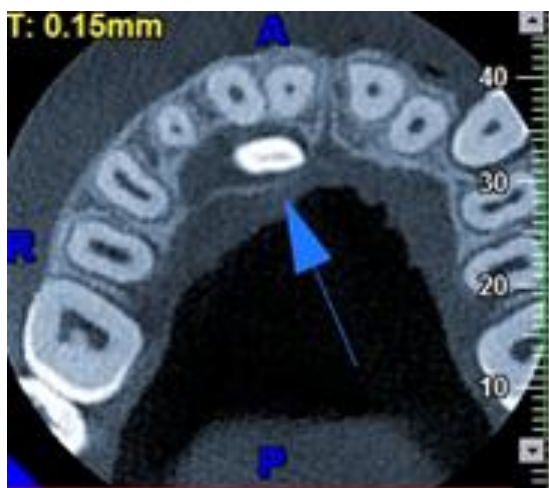
(canine long axis to the midsagittal plane greater than 25°) were suggested to increase root resorption by 50 per cent.<sup>[8]</sup> On contrary to this, physical pressure or contact from impacted maxillary canine has been advocated by many studies to be the principle causative factor for root resorption.<sup>[9,10]</sup>

The objectives of this study were to investigate the prevalence, extent of resorption, and predisposing risk factors for incisor root resorption associated with impacted maxillary canines.

## MATERIALS AND METHODS

The study was carried out on the patients visiting the out-patient section of the Department of Orthodontics and Dentofacial Orthopaedics, Government Dental College & Hospital, Srinagar. CBCT scans were taken for orthodontic reasons and keeping in mind the risks associated with ectopic eruption of maxillary canines. Patients with combined incisor and canine impactions, craniofacial anomalies, cleft lip and cleft palate were not included in this study. A total of 42 patients (27 female, 15 male) were selected. These clinical situations were considered as a single group. A total of 53 impacted canines were studied in which 11 were bilateral impactions, 17 right unilateral and 14 left unilateral impactions.

The data was obtained using the NewTom GIANO NNT Scanner with the patient in upright position. All the scans were taken using the same machine by the same operator. The operating parameters were set at 3mA and 90kV, dose of 80-100 µSv and the scan time of 9 seconds. All CBCT images were taken using a limited dentoalveolar field of view (FOV: 5cm×8cm, 8cm×8cm and 8cm×11cm).



**Figure 1: Representative example of an axial CBCT scan exhibiting a palatally located impacted canine.**

Imaging data was analyzed with the software provided by the manufacturer (NewTom 9000 Version 3. 10). The data was reconstructed in

slices, and examined slice by slice in all three dimensions (sagittal, coronal and axial) on 1:1 scaled images using the provided software. The following variables were analysed:

**Location** of impacted maxillary canine (buccolingual crown location of impacted canine in relation to lateral incisors): It was classified as buccal, palatal and apical position. It was assessed using sagittal and/or axial view [Figure 1].

**Root resorption** of incisors:

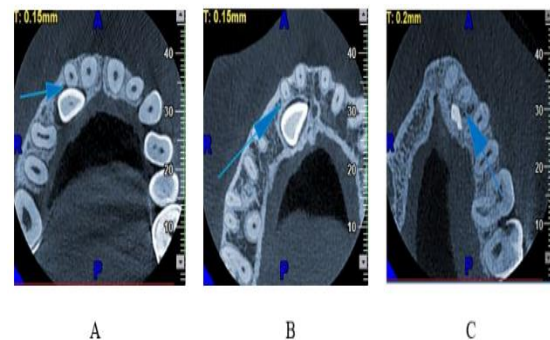
It was graded based on the system suggested by Ericson and Kuroi (2000).<sup>[11]</sup>

**No resorption:** intact root surface, the cementum may have been lost.

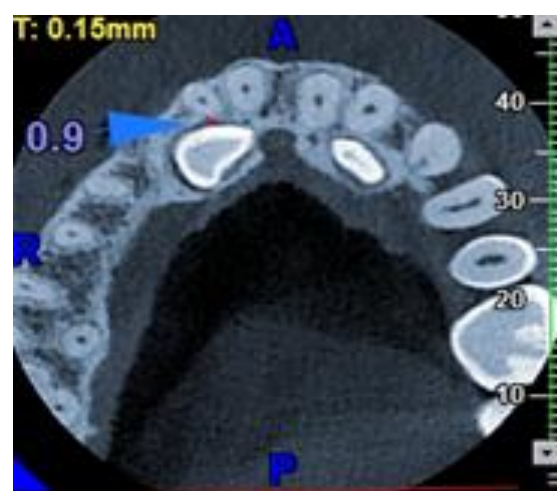
**Slight resorption:** resorption up to half of the dentine thickness [Figure 2A].

**Moderate resorption:** resorption of the dentine midway to the pulp or more, the pulp lining being unbroken [Figure 2B].

**Severe resorption:** resorption reaches the pulp [Figure 2C].



**Figure 2: Representative example of different types of root resorption in axial CBCT scans; (A) slight root resorption on a right lateral incisor; (B) moderate root resorption on a right lateral incisor; (C) severe root resorption on a left lateral incisor.**



**Figure 3: Proximity between impacted canine and lateral incisor in axial view.**

**Proximity** of the impacted canine to the lateral and central incisors: This was measured as the shortest distance between the impacted canine and the

incisor [Figure 3]. Contact was defined by  $\leq 0.5$  mm distance between the two teeth.

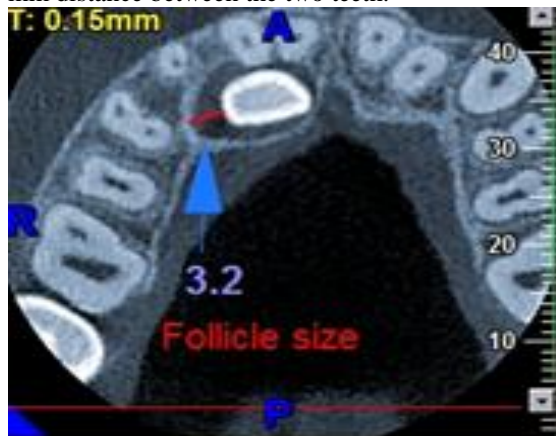

Figure 4: Follicles as measured in millimetres from crown to periphery of follicle (axial view).

**Follicle size:** It was measured at the widest area from the crown to the periphery of the follicle [Figure 4]. If the dimension from the crown to the periphery of the follicle was less than 2 mm, it was considered to be within normal limits, and if it was greater than 2 mm, it was considered to be an enlarged follicle.

**Statistical Analysis**

The recorded data was compiled and entered in a spreadsheet (Microsoft Excel) and then exported to data editor of SPSS Version 20.0 (SPSS Inc., Chicago, Illinois, USA). Continuous variables were summarized in the form of mean and standard deviations and categorical variables were summarized as percentages. Chi-square test or Fisher’s exact test, whichever appropriate, was used for comparison of categorical variables. A P-value of less than 0.05 was considered statistically significant.

**RESULTS**

In our study, CBCT scans of 53 impacted canines were analysed from 42 patients. The mean age of the patients was 21.2 years (range: 13–30 years, SD  $\pm 5.09$  years) with majority of subjects being 14-19 years [Figure 5A]. Of the 42 included patients, 15 (35.7 percent) were male subjects and 27 (64.3 percent) were female subjects [Figure 5B].

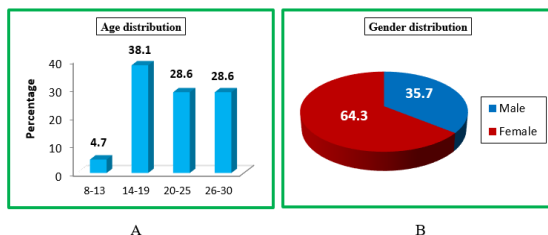


Figure 5: Age and gender distribution of the studied patients

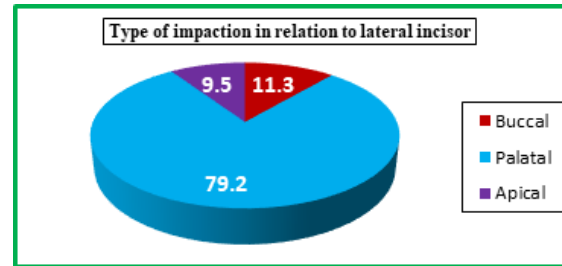


Figure 6: Distribution of impacted canine position.

Unilateral impaction was present in 31 patients (73.8 percent), and 11 patients (26.2 percent) presented with bilateral impaction. Among these 53 impacted canines, there was no significant difference between left and right impactions with 28 located on the right side (52.8 percent) and 25 on left side (47.2 percent).

It is evident from the distribution of the impacted canine position [Figure 6] that there were 79.2 per cent palatally impacted canines (42 canines), 11.3 per cent buccally impacted canines (6 canines) and 9.5 percent were located apically (5 canines).

The lateral incisors were the teeth most affected by resorption and were more resorbed than the central incisors. 18 incisors were resorbed, which included 16 lateral incisors (30.2 percent) and 2 central incisors (3.8 per cent) [Table 1]. Resorption occurred only on the lateral incisors in 16 cases, only on the central incisors in 2 cases, and on both incisors in none. No significant correlation between age, sex, and resorption was found.

Table 1: Incisor resorption associated with impacted canines.

Resorption	Lateral Incisor		Central Incisor	
	No.	%age	No.	%age
Yes	16	30.2	2	3.8
No	37	69.8	51	96.2
Total	53	100	53	100

Among lateral incisors, the resorption was slight in 11 cases (20.8 per cent), moderate in 3 cases (5.6 per cent), and severe in 2 cases (3.8 per cent) while among central incisors, the resorption was only slight in 2 cases (3.8 per cent) [Table 2].

Table 2: Resorption on the roots of maxillary incisors.

Root Resorption	Lateral Incisors		Central Incisors	
	No.	%age	No.	%age
No	37	69.8	51	96.2
Slight	11	20.8	2	3.8
Moderate	3	5.6	0	0.0
Severe	2	3.8	0	0.0
Total	53	100	53	100

Among 37 lateral incisors with canine contact, 15 were resorbed, whereas only 1 of 16 laterals without canine contact was resorbed. There was a highly significant correlation (P-value = 0.021) between contact and resorption. Among 7 centrals with canine contact 2 were resorbed, whereas none

was resorbed among 46 centrals without canine contact, again showing a high correlation between contact and resorption (P-value = 0.015) [Table 3].

**Table 3: Relationship of proximity of impacted canine with incisor root resorption.**

Resorption	Laterals		Centrals	
	Contact	No contact	Contact	No contact
Yes	15 (40.5%)	1 (6.2%)	2 (28.6%)	0 (0%)
No	22 (59.5%)	15 (93.8%)	5 (71.4%)	46(100%)
Total	37	16	7	46
P-value	0.021		0.015	

Approximately two-third of the impacted canine follicles examined were within normal limits (66.67%). The remaining cases (33.33%) were considered enlarged (> 2 mm). Follicle size varied from 0.5 mm to 3.8 mm, with an average of 1.8 mm. In two cases, the follicle was not present. No significant relationship (P-value =0.40) was observed between the occurrence of root resorption and a widened dental follicle of the ectopic canine [Table 4].

**Table 4: Relationship of follicle size with incisor root resorption.**

Follicle Size	Resorption		No Resorption		P-value
	No.	%age	No.	%age	
Within Normal Range	10	58.8	24	70.6	0.401
Enlarged	7	41.2	10	29.4	
Total	17	100	34	100	

## DISCUSSION

In planning the surgical-orthodontic repositioning of malpositioned maxillary canines, correct diagnosis requires not only their precise location, but also a thorough and accurate assessment of their relationship with not only adjacent anatomical structures, but also in particular the roots of adjacent teeth.<sup>[3,12]</sup> In order to minimize the risk of root resorption, early detection of any abnormal contact between the malpositioned canine and the roots of permanent incisors is essential.<sup>[7]</sup> In this respect, conventional radiology has often proved inadequate.

The prevalence of impacted maxillary canines varies within a range of 1-3 per cent.<sup>[2,3]</sup> Female subjects seem to be more affected than males.<sup>[3,11]</sup> Our study also shows more female subjects affected than males in a ratio of 2:1. Walker and co-workers speculate that the difference in genetics, as well as overall craniofacial growth and development between the two sexes, could be possible reasons for that finding.<sup>[2]</sup> Another reason could be that females seek orthodontic treatment

more frequently than males, as a result are reported more often than females.

In our study, the buccolingual positions of impacted canines were 79.2 per cent palatal and 11.3 per cent buccal, consistent with the findings of Preda et al.<sup>[3]</sup> In Asian samples, however, impacted canines were more often located buccally (45.2 percent) than palatally (40.5 percent) as reported by Liu et al.<sup>[9]</sup> Different reasons have been attributed to buccal and palatal impactions. Labial displacement is usually due to an inadequate dental arch space, whereas palatal displacement often occurs despite adequate arch space.<sup>[13]</sup>

The etiology of root resorption is still not fully understood. It has been postulated that enlarged dental follicles and the pressure caused by an erupting tooth may be responsible for root resorption of adjacent teeth.<sup>[14]</sup> However, based on a CT study, Ericson and co-workers have concluded that the dental follicle does not cause root resorption of permanent teeth.<sup>[15]</sup> They concluded that resorption of the permanent maxillary incisor is caused by the physical contact between the incisor and the canine, and by direct pressure from the canine as a part of the eruption process. As the maxillary canine erupts, the alveolar barrier of the adjacent incisor is temporarily resorbed and the normal protective layer of cementoblasts and collagen fibres disappears and open up for the dentinoclasts.<sup>[11]</sup> An ectopic canine with a well-developed root, erupting medially along the long axis of the adjacent lateral incisor and inclined > 25° to the midline of the jaw, presented the greatest risk for root resorption of the lateral incisor.<sup>[7,11]</sup> Our study supports previous findings that there is a correlation between prevalence of root resorption of permanent teeth and proximity/contact of the impacted canine. In our study sample, 15 resorbed lateral incisors and 2 resorbed central incisors showed proximity/ contact with the impacted canine. Only one lateral incisor and no central incisor was resorbed without direct canine contact. Further our study found that there was an overall but not statistically significant tendency for enlarged canine follicles to occur together with root resorption. The size of follicles was within a range of 0.5 to 3.8mm in 53 impacted canines, indicative of a propensity for cystic degeneration. Therefore, our study supports the findings of Ericson and co-workers, but due to the limited sample size some caution is still necessary.<sup>[15]</sup>

Ericson and Kurol in one of their CT studies found that the ipsilateral lateral incisor was the tooth most commonly affected by root resorption (38 per cent), followed by the ipsilateral central incisor (9 per cent).<sup>[11]</sup> We also found similar results as 30.2 per cent of the lateral incisors and 3.8 per cent of the central incisors show some degree of resorption. Root resorption as a result of impacted canines

seems to be a rapid, progressive process that almost always ceases once the impacted canine has been removed from the affected root area.<sup>[17]</sup> Previous studies have shown that the amount of information obtained from three-dimensional analysis is significantly greater than from conventional periapical and panoramic radiography and consequently this may have an influence on the treatment plan.<sup>[18,19]</sup>

## CONCLUSION

As resorption is asymptomatic in early stages of resorption, it is very difficult to detect and diagnose particularly with two-dimensional radiographic methods. CBCT provides additional accurate information about location of impacted maxillary canine and prevalence and degree of root resorption of neighbouring teeth. Canine impaction poses a higher risk for root resorption at adjacent teeth than normally erupted canines. Physical proximity (<0.5 mm) between impacted canine and adjacent roots of incisors is the most important predictor for root resorption associated with impacted canines at the incisors. The width and the shape of the dental follicle of the impacted canines do not correlate with root resorption of maxillary incisors.

## REFERENCES

- Maverna R, Gracco A. Different diagnostic tools for the localization of impacted maxillary canines: clinical considerations. *Progress in Orthodontics* 2007; 8: 28–44
- Walker L, Enciso R, Mah J. Three-dimensional localization of maxillary canines with cone-beam computed tomography. *American Journal of Orthodontics and Dentofacial Orthopedics* 2005; 128: 418–423.
- Preda L, La Fianza A, Di Maggio E M, Dore R, Schifino M R, Campani R. The use of spiral computed tomography in the localization of impacted maxillary canines. *Dentomaxillofacial Radiology* 1997; 26: 236–241.
- Becker A, Smith P, Behar R. The incidence of anomalous maxillary lateral incisors in relation to palatally-displaced cuspids. *Angle Orthodontist* 1981; 51: 24–29
- Ericson S, Kurol J. Incisor root resorptions due to ectopic maxillary canines imaged by computerized tomography: a comparative study in extracted teeth. *Angle Orthodontist* 2000; 70: 276–283
- Ericson S, Kurol J. Early treatment of palatally erupting maxillary canines by extraction of the primary canines. *Eur J Orthod* 1988; 10:283–295.
- Ericson S, Kurol J. Radiographic examination of ectopically erupting maxillary canines. *Am J Orthod Dentofacial Orthop.* 1987; 91:483–492.
- Ericson S, Kurol J. Resorption of maxillary lateral incisors caused by ectopic eruption of the canines. A clinical and radiographic analysis of predisposing factors. *Am J Orthod Dentofacial Orthop* 1988; 94:503-13.
- Liu DG, Zhang WL, Zhang ZY, Wu YT, Ma XC. Localization of impacted maxillary canines and observation of adjacent incisor resorption with cone-beam computed tomography. *Oral Surg Oral Med Oral Pathol Oral Radiol Endod* 2008; 105:91-8.
- Kim Y, Hyun HK, Jang KT. The position of maxillary canine impactions and the influenced factors to adjacent root resorption in the Korean population. *Eur J Orthod* 2012; 34:302-6.
- Ericson S, Kurol J. Resorption of incisors after ectopic eruption of maxillary canines: a CT study. *Angle Orthod* 2000; 70:415-23.
- Bodner L, Sarnat H, Bar-Ziv J, Kaffe I. Computed tomography in the management of impacted teeth in children. *J Dent Child* 1994; 61: 370-377
- Jacoby H. The etiology of maxillary canine impactions. *Am J Orthod Dentofac Orthop* 1983 ; 84: 125–132.
- Marks S C, Schroeder H E, Andreasen J O. Theories and mechanism of tooth eruption. In: Andreasen J O, Kölsen-Pedersen J, Laskin D M (eds). *Textbook and color Atlas of tooth impactions*. Mosby, St Louis; 1997.p. 20–65.
- Ericson S, Bjerklin K, Falahat B. Does the canine dental follicle cause resorption of permanent incisor roots? A computed tomographic study of erupting maxillary canines. *Angle Orthod* 2001; 72: 95–104.
- Jacobs SG. Reducing the incidence of unerupted palatally displaced canines by extraction of deciduous canines. The history and application of this procedure with some case reports. *Austr Dent J* 1998; 43: 20–27.
- Becker A, Chaushu S. Long-term follow-up of severely resorbed maxillary incisors after resolution of an etiologically associated impacted canine. *Am J Orthod Dentofacial Orthop* 2005; 127: 650–654.
- Alqerban A , Willems G, Bernaerts C, Vangastel J, Politis C, Jacobs R. Orthodontic treatment planning for impacted maxillary canines using conventional records versus 3D CBCT. *Euro J Orthod* 2014; 36: 698–707
- Bjerklin K, Ericson S. How a computerized tomography examination changed the treatment plans of 80 children with retained and ectopically positioned maxillary canines. *Angle Orthod* 2006 ;76: 43–51

**How to cite this article:** Gull MAB, Mushtaq M. Impacted Maxillary Canines Increase External Root Resorption of Adjacent Incisors: Physical Proximity A Predisposing Factor. *Ann. Int. Med. Den. Res.* 2018; 4(2):DE01-DE05.

**Source of Support:** Nil, **Conflict of Interest:** None declared