

Is Direct Vision Internal Urethrotomy a Viable Option for Treating Urethral Strictures in Patients with Morbidities: Our Experience.

Sanjay Bhat¹, A. K. Roy², Saurabh Rai³, Maham Ahmad⁴, Narendra P. Singh⁵, Rahul Bhushan⁶

^{1,2}Professor, Department of Surgery, Era's Lucknow Medical College.

³Ass. Professor, Department of Surgery, Era's Lucknow Medical College.

⁴Senior Resident, Department of Surgery, Era's Lucknow Medical College.

^{5,6}Junior Resident, Department of Surgery, Era's Lucknow Medical College.

Received: January 2017

Accepted: January 2017

Copyright: © the author(s), publisher. It is an open-access article distributed under the terms of the Creative Commons Attribution Non-Commercial License, which permits unrestricted non-commercial use, distribution, and reproduction in any medium, provided the original work is properly cited.

ABSTRACT

Background: Direct visual internal urethrotomy (DVIU) and urethral dilatation are the most commonly performed procedures for urethral stricture disease. This approach is appealing both for urologists and patients as it is minimally invasive. The objective of this paper is to outline the current scientific evidence supporting this approach for its use in the management of urethral strictures in patients with multiple morbidities who would not tolerate prolonged surgeries well and to share our own experiences. **Methods:** We performed a retrospective study of cystoscopy-guided internal urethrotomies performed between 2009 and 2014 on patients with co morbid conditions. **Results:** Overall, urethral stricture stabilized in 76.7% of patients with 1 or 2 internal urethrotomies within 24 months of follow-up. **Conclusion:** Direct vision cold knife urethrotomy is a safe technique that should be exercised as a therapeutic trial in patients with co morbidities as an alternative giving a safer and easier option.

Keywords: DVIU, urethral stricture, Urethrotomy, morbidity.

INTRODUCTION

Urethral stricture affects approximately 300 in 100000 men. The process of wound healing by chronic inflammation results in the formation of granulation tissue, ultimately leading to scar formation. This applies to inflammation of the urethra as well, resulting in subsequent scarring and stricture formation.^[1]

Name & Address of Corresponding Author

Dr. Sanjay Bhat
Professor,
Department of Surgery,
Era's Lucknow Medical College.

Gonococcal urethritis was initially the most common etiological factor for urethral stricture disease (USD), and has been now replaced by trauma or iatrogenic injury as the major etiology.^[2]

Clinical presentation of USD depends on the degree of obstruction to urinary flow, the location, degree and chronicity of the stricture. Patients may present with obstructive lower urinary tract symptoms (LUTS) or with complications such as urinary tract infections (UTI), prostatitis or epididymo-orchitis, renal failure.^[3]

Diagnostic evaluation of patients with USD includes Uroflowmetry and imaging of the urethra. Urethral

imaging is conventionally done with a retrograde urethrogram (RGU), which delineates the length and location of the stricture. However, recent advances in radiological imaging have contributed to the use of sono-urethrogram and urethral MRI. Urethral stricture disease (USD) management has witnessed many changes right from the use of sounds and bougies, urethral dilatations, endoscopic procedures and open surgeries.^[4]

Direct visual internal urethrotomy (DVIU) and urethral dilatation are the most commonly performed procedures for urethral stricture disease. This approach is appealing both for urologists and patients as it is minimally invasive.^[5] The objective of this paper is to outline the current scientific evidence supporting this approach for its use in the management of urethral strictures in patients with multiple morbidities who would not tolerate prolonged surgeries well and to share our own experiences at our centre at Era's Lucknow Medical College, Lucknow.

Currently urethral stricture disease is relatively common, most strictures being acquired from injury or infection. Blunt perineal trauma causes injury to the bulbar urethra; pelvic fractures result in urethral distraction defects in the posterior urethra, but iatrogenic causes, including urological instrumentation and placing indwelling catheters,

which result in strictures anywhere in the urethra, are probably the most common cause.

DVIU was popularized after the initial report of Sachse in 1972. In the 1980s, the concept of intermittent self-catheterization (SC) following DVIU took shape in order to decrease stricture recurrence. This paper analyses the developments in DVIU that have occurred subsequently and attempts to outline its role in the current management of urethral stricture disease.

Patients having high risk and relatively contraindicated to prolonged surgeries include:^[6]

- Age>60 years.
- BMI>30
- Diabetes Mellitus
- Current smoker
- Alcoholic
- COPD
- CHF
- MI within past 6 months
- HTN on medication
- Acute renal failure or current Dialysis
- History of CVA
- Advanced Malignancy
- Pregnancy

MATERIALS AND METHODS

We performed a retrospective study at our centre Era's Lucknow Medical College and Hospital where cystoscopy-guided internal urethrotomies had been performed between 2009 and 2014 on patients with co morbid conditions. Our planned indication for the procedure was urethral strictures shown on simultaneous voiding cystourethrography and retrograde urethrography.

The length of stricture was grouped in less than 1, 1-2 cms and greater than 2 cms.

A flexible cystoscope was introduced through a mature cystostomy tract to the posterior urethra up to the nearly blinded point. The bladder, bladder neck, and prostatic urethra were examined, and in cases of bulbar urethral stricture, the external urethral sphincter and the distance of the stricture from the sphincter were evaluated. Then, the urethrotome was passed retrogradely through the urethra to the stricture point.

Monitoring any impression of urethrotome on the monitor through the flexible cystoscope, we were able to do under-vision urethrotomy in our patients. After providing a wide open urethra that allows easily introduction of a 21-F resectoscope to the bladder, a 18-F urethral catheter was placed. The urethral catheter was left in place for 5 days. Thereafter, self catheterization by the patient was started with 18-F urethral catheters.

The patients were instructed for performing self calibration, and the probable complications or problems were described. The follow-up visits were

planned as monthly clinical visits for 12 months, and then, every 3 months for a maximum of 24 months.

All of the patients were followed up for 24 months after their last urethrotomy. urethrography was done 6 and 12 months postoperatively, and urethrocystoscopy was done 6, 12, and 24 months, postoperatively. urethrocystoscopy was done in patients who had any difficulty in voiding or had any problem in self calibration.

Our indication for additional urethrotomies was stricture recurrence shown on retrograde urethrography and confirmed by urethrocystoscopy. We defined urethral stricture stabilization for our patients as remaining without stricture recurrence for 24 months after the last urethrotomy.

LUTS especially obstructive voiding symptoms remain the typical reason for evaluating urethral stricture disease. Recurrent UTIs, urethral bleeding, and now more rarely, urethrocutaneous fistula and peri-urethral abscess develop. Retrograde urethrography (RUG) remains the study of choice for diagnosis. Often an antegrade voiding study through a previously placed suprapubic tube, combined with a RUG, provides important information regarding the length of stricture and a fair idea of urethral caliber at the site of stricture.^[6]

Cysto-urethroscopy allows the true calibre of a urethral stricture to be evaluated (there is often a mismatch between radiographic and endoscopic findings) and if a small flexible endoscope (or ureteroscope) is used the length of the stricture and the quality of the proximal urethra can be assessed.^[7]

In the case of pelvic fracture urethral distraction defects (PFUDDs) it is important to examine the active sphincter area of the urethra for evidence of concomitant injury, and the bladder for calculi; this is usually done via the suprapubic tract. MRI can be invaluable in some cases of posterior urethral strictures after pelvic fracture.^[8]

The patients were observed for any complications. Severe complications considered as the following: severe bleeding that needed packing and physical examination and antegrade or retrograde cystoscopy.^[9]

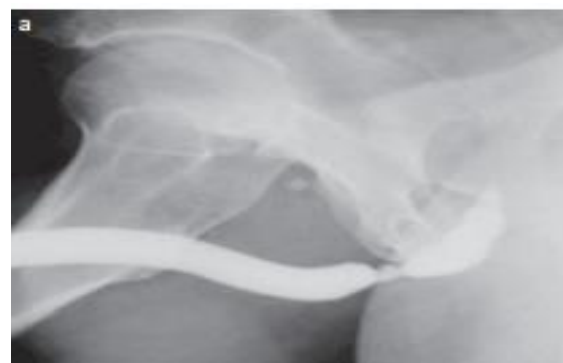

Figure 1: RUG study.

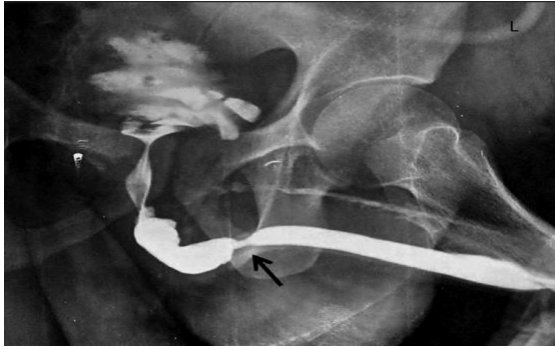


Figure 2: MCU Study.

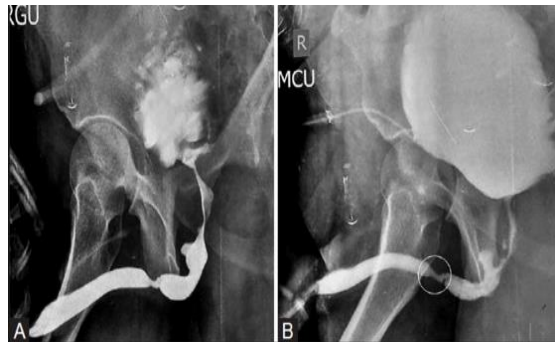

Figure 3: RGU & MCU Study.

RESULTS

A total of 23 patients fulfilled our criteria and underwent flexible cystoscopy-guided internal urethrotomy at our center.

Associated co morbid conditions with stricture:

- Diabetes: 10
- Hypertensive: 7
- Advanced age: 14
- History MI/Angina/CVA: 4
- Smoker/Alcoholic: 11
- Advanced BMI: 9
- COPD: 1
- CHF: 1
- Malignancy: 2

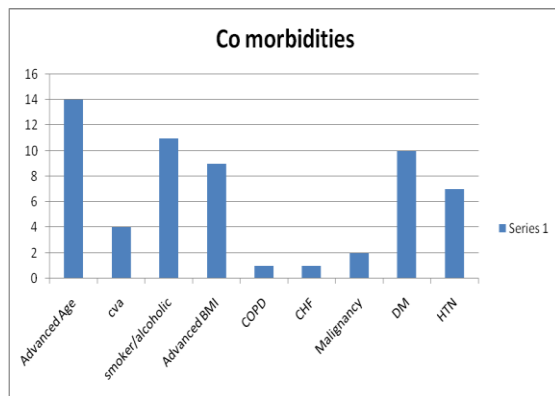


Figure 4: Co-morbidities.

Table 1: Etiological classification for pts.

Idiopathic	9 pts	39.13%
Injury post catheterization	4 pts	17.39%
History of trauma	6 pts	26.08%
Post TURP	4 pts	17.39%

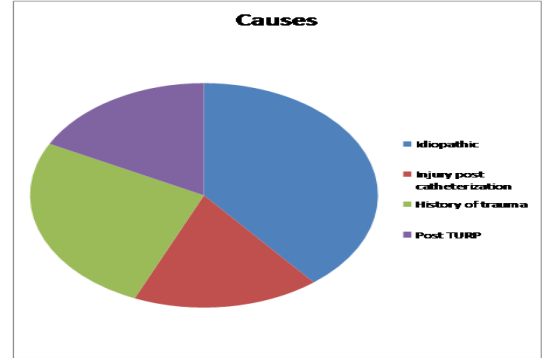


Figure 5: Causes.

Table 2: The presenting complaint in the patients.

Poor urinary stream	13	56.52%
Dribbling	3	13.04%
Intermittency	2	8.69%
Sense of incomplete emptying	2	8.69%
Recurrent UTI	2	8.69%
Urine retention	1	4.34%

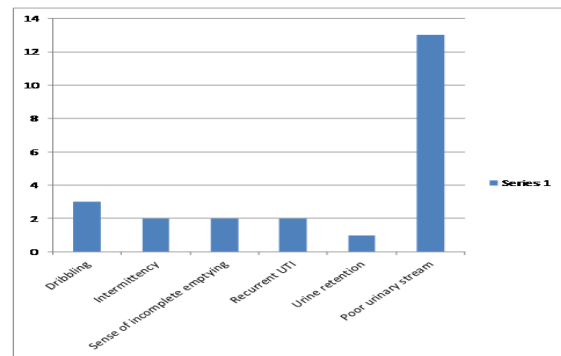


Figure 6: Symptoms.

Table 3: Site of urethral strictures.

Penile	5 pts	21.73%
Bulbar	14 pts	60.86%
Prostatomembranous	4 pts	17.39%

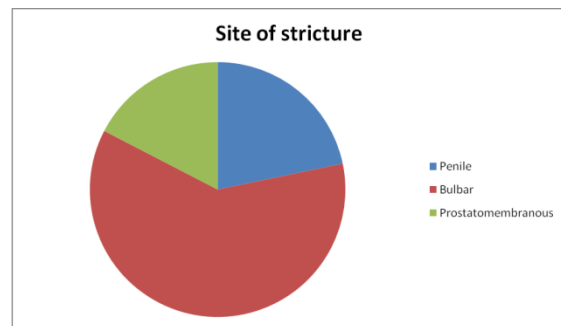


Figure 7: Site of Stricture.

The external urethral sphincter was intact and away from the stricture site in all of these patients. Straddle injury and catheterization trauma were the cause of disease in 2 and 7 patients, respectively. Spinal anesthesia was used in all of the patients. Overall, urethral stricture stabilized in 76.7% of patients with 1 or 2 internal urethrotomies within 24 months of follow-up. All second internal urethrotomies in these patients were done during the first 12 months after the first internal urethrotomy

Failure rate assessment:

Overall failure: 6 out of 23.

Table 4: Postoperative complications.

Complication	No. of patients	Penile	Bulbar	prostatome mbranous
Bleeding	3	2	0	1
Fluid extravasation	1	1	0	0
UTI	3	2	1	0
Recurrent stricture	6	2	1	2

DISCUSSION

Up to the mid 20th century, urethral dilatation and blind internal urethrotomy remained the treatment of choice for urethral strictures. Suprapubic cystostomy was the only alternative.

Modalities of treatment like urethral dilatation and rail road techniques are more or less obsolete because of poor efficacy and inherent complications. On the other hand, internal optical urethrotomy is now considered the gold standard in management of urethral stricture because of its simplicity and easy performance which leads to worldwide popularity of this procedure for treatment of urethral stricture.

The idiopathic etiology of stricture in our study was idiopathic in 39.13% followed by traumatic injuries in 26% cases. In contrast to our study Chelton et al^[10] reported 11.5% traumatic stricture. The high incidence of traumatic stricture in our study was due to road traffic accidents & war injuries.

In our study, in 76.7% patients, the response to optical urethrotomy was good while 6 out of 23 were having poor response. These were quite comparable with Holm Nielsen et al^[11] reported success rate 77% & Pansadoro V reported 11% poor results.^[12]

CONCLUSION

During a 5-year period urethral strictures in 23 patients with associated co morbidities were treated by cold knife urethrotomy. Analysis of the etiology, diagnosis, surgical technique, complications and postoperative management is described. Satisfactory results were achieved in 71 per cent of the cases. The over-all morbidity rate was 9 per cent. Direct vision cold knife urethrotomy is a safe technique that

should be exercised as a therapeutic trial in patients with co morbidities as an alternative giving a safer and easier option.

REFERENCES

1. Das S. Urology in ancient India. *Ind J Urol.* 2007;23:2–5.
2. Santucci RA, Eisenberg L. Urethrotomy has a much lower success rate than previously reported. *J Urol.* 2010;183:1859–62.
3. Al-Ali M, Al-Shukry M. Endoscopic repair in 140 cases of urethral occlusion: the promise of guided optical urethral reconstruction. *J Urol.* 1997;156:129–31.
4. Jablonski Z, Kedzierski R, Miekos E, Sosnowski M. Comparison of neodymium-doped yttrium aluminium garnet laser treatment with cold knife endoscopic incision of urethral strictures in male patients. *Photomed Laser Surg.* 2010; 28: 239–44.
5. Turek PJ, Cendron M, Malloy TR, Carpiniello VL, Wein AJ. KTP-532 laser ablation of urethral strictures. *Urology.* 1992; 40:330–34.
6. Patient Selection for Day Case-eligible Surgery: Identifying Those at High Risk for Major Complications; Michael R. Mathis, M.D.; *Journal of American Society of Anaesthesiologists; Anesthesiology.* 2013; 119: 1310-1321.
7. Kamp S, Knoll T, Osman MM, Kohrmann KU, Michel MS, Alken P. Low-power holmium: YAG laser urethrotomy for treatment of urethral strictures: Functional outcome and quality of life. *J Endourol.* 2006;20:38–41.
8. Pain JA, Collier DG. Factors influencing recurrence of urethral strictures after endoscopic urethrotomy. *Br J Urol.* 1984;56:217–9.
9. Mazdak H, Izadpanahi MH, Ghalamkari A, Kabiri M, Khorrami MH, Nouri-Mahdavi K, et al. Internal urethrotomy and intraurethral submucosal injection of triamcinolone in short bulbar strictures. *IntUrolNephrol.* 2009 .
10. Chilton CP, Shah PJR, Fowler CG, Tiptaft RC, BlandyJP. The impact of optical urethrotomy on the management of urethral strictures. *Br J Urol.* 1983; 55: 705.
11. Holm-Nielsen A, Schultz A, Moller-Pedersen V. Direct vision internal urethrotomy: A critical review of 365 operations. *Br J Urol.* 1984; 56:308–12
12. Pansadoro V, Emiliozzi P. Internal urethrotomy in the management of anterior urethral strictures: long term follow up. *J Urol.* 1996; 156: 73-75.

How to cite this article: Bhat S, Roy AK, Rai S, Ahmad M, Singh NP, Bhushan R. Is Direct Vision Internal Urethrotomy a Viable Option for Treating Urethral Strictures in Patients with Morbidities: Our Experience. *Ann. Int. Med. Den. Res.* 2017; 3(2):SG37-SG40.

Source of Support: Nil, **Conflict of Interest:** None declared