

Fracture Penis: Our Experience with 29 Cases in a Tertiary Care Hospital, Odisha.

Bharat Kumar Behera¹, Narendranath Swain¹

¹Assistant professor, Department of Surgery, SCB Medical College, Cuttack.

Received: March 2017

Accepted: March 2017

Copyright: © the author(s), publisher. It is an open-access article distributed under the terms of the Creative Commons Attribution Non-Commercial License, which permits unrestricted non-commercial use, distribution, and reproduction in any medium, provided the original work is properly cited.

ABSTRACT

Background: Penile fracture is a surgical condition commonly occurs due to blunt trauma to the erect penis during masturbation or sexual intercourse. In this study we share our experience in treating 29 such cases. **Methods:** The data of 29 patients from medical records and outpatient follow up visits were collected retrospectively at our hospital. **Results:** The mean age of the patients was of 24 ± 2.5 years; trauma during coitus was the most common cause of the penile fracture. All fractures were repaired on an emergency basis via subcoronal incision. One patient had longitudinal rupture site. One patient had associated urethral injury. Postoperatively, all patients voided with good flow and had erections with adequate rigidity. **Conclusion:** Penile fracture diagnosis is mostly clinical. Early surgical intervention and repair carries excellent outcome.

Keywords: Penile, fracture, rupture, trauma, erectile dysfunction.

INTRODUCTION

Penile fractures occur to the erect penis as a result of blunt trauma commonly during coitus or masturbation.^[1,2] There are many other aetiologies for penile fracture as striking the erect penis, for example falling on the rigid erected penis or even rolling over on the erect penis in bed. It is not a common problem, this is why the best line of management is not well defined.^[3]

Name & Address of Corresponding Author

Dr Bharat Kumar Behera
Assistant professor
Department of Surgery
SCB Medical College, Cuttack, Odisha.

The resultant injury is usually a transverse tear in the tunica albuginea of one corporal body. However, involvement of both corpora, corpus spongiosum and urethra had also been reported.^[4] Rupture of the tunica albuginea occurs due to its marked thinning from a resting thickness of 2mm down to 0.25 ± 0.5 mm on erection together with the associated marked short-term pressure increases (intracavernous pressures exceeding 450mm Hg), which approach or exceed the tunica tensile strength during acute abrupt loading or bending of the erect penis.^[5] Typically the patient reports a snap or cracking sound accompanied by immediate pain and rapid detumescence followed immediately by development of swelling and angulation.^[6] Blood at the meatus or gross hematuria were reported in cases of urethral injury.^[7] Penile ultrasonography, cavernosography and, recently, magnetic resonance

imaging (MRI) have been reported to be helpful in establishing the diagnosis and localizing the site of the tear, particularly in the suspicious cases.^[8,9] Ascending urethrogram is mandatory whenever urethral injury is suspected. All recent reports favor early surgical repair due to the adequate functional and cosmetic results with minimal complications.^[10] This is in contrast to old reports favoring conservative management.^[11] Various surgical approaches have been reported. These included circumferential subcoronal longitudinal incision over the hematoma site or, more recently, an inguinoscrotal incision.^[12-14] We now evaluate our own experience with 29 patients with penile fractures who were all managed by early operative intervention.

MATERIALS & METHODS

Between August 2013 to August 2016, 29 patients with penile fracture detected clinically were treated at our department the time from injury to clinical presentation was between 6 hours and 72 hours. Out of the 29 Patients 16 cases had injured during sexual intercourse and 7 cases had been injured during masturbation. Most patients presented cracking and propping sound followed by rapid detumescence. Associated pain and swelling were also encountered. Physical examination revealed penile swelling and ecchymosis confined to shaft. Ruptured site was palpable in 2 cases. Tenderness could be felt in other cases. Clinical presentation investigation and operative findings and post-operative complications were reviewed from patients

chart. Twenty two patients were followed up .Duration of follow up was 24.3 ± 5.5 months. They were examined during each follow up for erectile dysfunction, curvature of penis, development of plaques.

RESULTS

Twenty nine Patients with penile fracture attended the surgery department in emergency within 6-74 hours (mean 13.2 ± 6.9 hours) having mean age of 24 ± 2.5 years (range 20-56yrs). Table 1 shows distribution of age. All patient complained of pain, swelling, hematoma [Figure 1] and 21 patients had snapping sound. Only one patient presented with bleeding per urethra. Table 2 shows the causes of penile fracture.

Table 1: Age distribution of patients with penile fracture.

Age interval (Yrs)	No of patients	Percentage (%)
<20	2	6.8
20-30	15	51.7
31-40	6	20.6
40-50	5	17.2
>50	1	3.4
Total	29	100

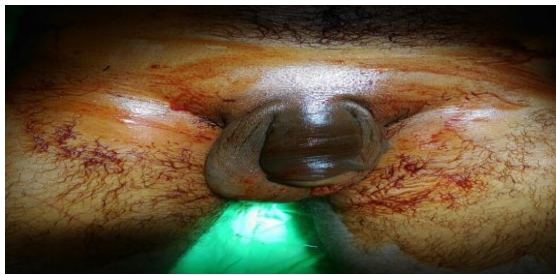

Figure 1: (Scrotal hematoma).

Table 2: Causes of penile fracture in patients.

Causes of fracture	No of patients	Percentage(%)
Sexual intercourse	16	55.1
Masturbation	7	24.1
Hitting of the penis against hard object	4	13.7
Others	2	6.8

Diagnosis was made by classical clinical presentation and verified by the ultrasonography. MRI was performed in 2 cases. Retrograde urethrogram was performed in one case. All cases were explored by circumcoronal incision. Penis degloved and rupture site were exposed.

Table 3: Operative findings of patients with penile fracture.

Site and type of tear	No of patients	Percentage(%)
Right corpus	15	51.7
Left corpus	13	44.8
Bilateral	1	3.4
Transverse tear	28	96.5
Longitudinal tear	1	3.4
Urethral involvement	1	3.4

Table 3 summarises our operative findings. Tear was found on right corpus in 15 cases. Left corpus involved in 13 cases. One case involved both corpora. Only one case had longitudinal tear [Figure 2] and all other had transverse tear. Urethra involved in only one case.

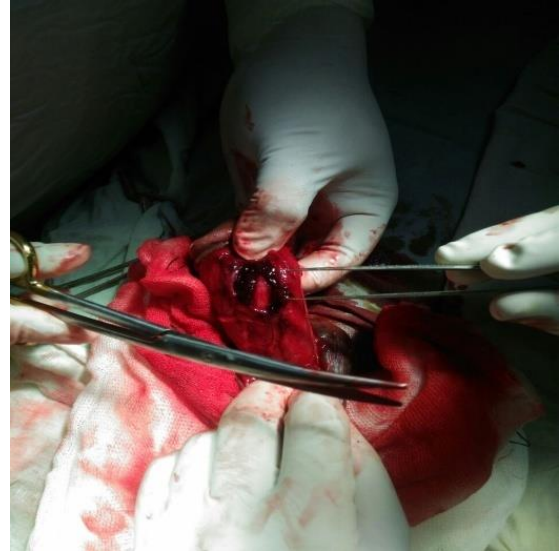


Figure 2: (Longitudinal tear).

Repair was done with absorbable (Polyglycolic acid) interrupted sutures in all cases Urethral resection and end to end anastomosis was required in one case.

No significant early post-operative complication were reported. The mean post-hospital stay was (3.2 ± 1.5) day ranging from 1 to 7 days. Patient having urethral injury was discharged with indwelling catheter for 3 weeks.

DISCUSSION

Penile fractures are an urologic emergency. The tunica albuginea measures approx. 2mm in thickness, which is thinned to 0.25mm during erection. The most frequently reported mechanism of injury is blunt trauma during sexual intercourse or penile manipulation, especially masturbation, including kneading, forcibly bending the erect penis to pass urine or rolling onto the erect penis.^[15] Twenty-nine patients with repaired penile fractures were followed in our hospital for a mean period of 24.5 months. We diagnosed with the characteristic history of snap sound, sudden detumescence followed by the development of swelling and penile deformity. Most of our patients developed this injury during sexual intercourse which agrees with published data (range 33 -60%).^[16] Masturbation and rolling over in bed constituted one third of the occasions causing penile fracture compared to the abnormally high incidence of 78% reported in the series of Asgari and his associates.^[12] Complete transection of the urethra and corpus spongiosum is rarely reported in the literature, in contrast to the many partial urethral injuries.^[16] Only one of the

patients had associated urethral injury which is less than the 10 -20% range reported in the literature.^[16] The urethral injury required resection and reanastomosis. We found that the classic presentation of penile fracture is sufficient indication for exploration, however, ultrasonography has made its use routine to confirm the diagnosis in the last 13 patients of our study. Although noninvasive sonography depends on the observers' skill and can miss the site of the tunical tear if it is too small or it is full with a clot that renders it indistinguishable from the surrounding normal tunica albuginea.^[17] On the other hand, some authors recommend cavernosography for the diagnosis of tunical rupture.^[18] However, this has been opposed by others who consider it an invasive procedure with risks of infection, priapism and allergy to iodides.^[19] More recently MRI has been advocated when the diagnosis is uncertain.^[20] Therefore, we stressed the necessity of penile ultrasonography and started recently to consider the more invasive cavernosography and /or the more costly MRI as adjunctive diagnostic modalities in atypical cases. [Figure 2] Intra-operative photograph showing the site of tear of the tunica albuginea (arrow). Surgical intervention in penile fractures MS El-Bahnasawy and MA Gomha 275 International Journal of Impotence Research Subcoronal circumferential incision has been applied in all cases due to the excellent exposure of the three corpora which avoids accidental missing of a urethral injury or multiple injuries of the tunica (one of our cases showed bilateral corporal injuries).^[21] We could not explain why the incidence of right corporal rupture is more than the left one in the cases of our study. Interrupted absorbable sutures were favored for repair of the ruptured tunica albuginea. No significant early post-operative complications were encountered. The hospital stay was short (3.2 ± 1.5 day). Patients who stayed longer in hospital were those with urethral repair. Long-term follow-up showed good functional results in terms of maintained normal sexual function and absent penile curvature or plaques in 93.1% of the followed cases. Only two patients (6.9%) had long-term complications in the form of palpable fibrous plaques (two patients). These two patients shared the problem of delayed presentation and subsequent repair (24 h delay). Non-absorbable sutures were used in all of them. Some authors considered the previous two factors to be responsible for fibrosis, curvature or Peyronie's plaques complicating their cases of penile fractures.^[22] Pryor and his associates, reported 18 cases of Peyronie's disease complicating unrepaired blunt penile trauma in 22 patients. They also found that 8% of their 222 Peyronie's disease patients were due to penile trauma.^[19] A third risk factor which could be responsible for the development of such fibrous plaque is the presence of associated cavernous tissue trauma. Such trauma may predispose to more severe

fibrosis and subsequent development of dense plaque and possible loss of erectile capacity.^[22] This incidence of complications in the range of 7% agrees with similar low figures of complications reported, with early surgical repair in different series.^[23]

CONCLUSION

The diagnosis of the penile fracture is mostly a clinical one. Early surgical exploration and repair is recommended. Most commonly the rupture occurs transversely but it can also be longitudinal. Haematuria is suspicious of associated urethral injury. Immediate surgical repair gives excellent outcome. This series supports the excellent outcome obtained by immediate operative repairs as in other studies in terms of low morbidity, short hospital stay and good functional results. The majority of the patients maintained their erectile ability without any penile angulations or deformity.

REFERENCES

- O'è zen HA et al. Fracture of the penis and long-term results of surgical treatment. *Br J Urol* 1986; 58: 551 - 552.
- Orvis BR, McAninch JW. Penile rupture. *Urol Clin North Am* 1989; 16: 369 - 375.
- Mydlo JH, Hayyeri M, Machia RK. Urethrography and cavernosography imaging in a small series of penile fracture: a comparison with surgical findings. *Urology* 1998; 51:
- Zenteno S. Fracture of the penis: a case report. *Plastic Reconst Surg* 1973; 52: 669 - 671. 616 - 619
- Penson DF et al. The hemodynamic pathophysiology of impotence following blunt trauma to the erect penis. *J Urol* 1992; 148: 1171 - 1180.
- Meares EM. Traumatic rupture of the corpus cavernosum. *J Urol* 1971; 105: 407 - 408.
- Nicolaisen G, Melamud A, Williams RD, McAninch JW. Rupture of the corpus cavernosum: surgical management. *J Urol* 1983; 130: 917 - 919
- Joos H, Kunit G, Frick J. Traumatic rupture of corpus cavernosum. *Urol Int* 1985; 40: 128 - 131.
- Davies DM, Mitchell I. Fracture of the penis. *Br J Urol* 1978; 50: 426
- Mellinger BC, Douenias R. A new surgical approach for the operative management of penile fracture and penetrating trauma. *Urology* 1992; 39: 429 - 432
- Ruckle HC, Hadley HR, Lui PD. Fracture of penis: diagnosis and management. *Urology* 1992; 40: 33 - 35.
- Thompson RF. Rupture of the penis. *J Urol* 1954; 71: 226 - 229.
- Jallu A, Wani NA, Rashid PA. Fracture of the penis. *J Urol* 1980; 123: 285 - 286.
- Anselmo G et al. Fracture of the penis: therapeutic approach and long-term results. *Br J Urol* 1991; 67: 509 - 511.
- Fedel M et al. The value of magnetic resonance imaging in the diagnosis of suspected penile fracture with atypical clinical findings. *J Urol* 1996; 155: 1924 - 1927.
- Tsang T, Dempy AM. Penile fracture with urethral injury. *J Urol* 1992; 147: 466-468.
- Dierks PR, Hawkins H. Sonography and penile trauma. *J Ultrasound Med* 1983; 2: 417 - 419.
- Maubon AJ et al. Penile fracture: MRI demonstration of a urethral tear associated with a rupture of the corpus cavernosum. *Eur Radiol* 1998; 8: 469 - 470
- Koga S et al. Sonography in fracture of the penis. *Br J Urol* 1993; 72: 228 - 229.

20. Grosman H et al. The role of corpus cavernosography in acute fracture' of the penis. Radiology 1982; 144: 787 - 788. Surgical intervention in penile fractures MS El-Bahnasawy and MA Gomha 276 International Journal of Impotence Research
21. Asgari MA et al. Penile fracture: evaluation, therapeutic approaches and long term results. J Urol 1996; 155: 148 - 149.
22. Pryor, JP, Hill JT, Packham DA, Yates-Bell AJ. Penile injuries with particular reference to injury to the erectile tissue. Br J Urol 1981; 53: 42 - 46
23. Rahmouni A et al. Magnetic resonance imaging of penile rupture: aid to diagnosis. J Urol 1995; 153: 1927 - 1928.

How to cite this article: Behera BK, Swain N. Fracture Penis: Our Experience with 29 Cases in a Tertiary Care Hospital, Odisha. Ann. Int. Med. Den. Res. 2017; 3(3): SG16-SG19.

Source of Support: Nil, **Conflict of Interest:** None declared