

## Pilonidal Disease- Review Article.

Harpreet Singh<sup>1</sup>, Malika Agrawal<sup>2</sup>, Naveen Kumar Singh<sup>3</sup>, Roop Kishan Kaul<sup>4</sup>, Ghulam Nabi<sup>5</sup>

<sup>1</sup>Associate professor, Department of General Surgery, Teerthankar Mahaveer Medical College, TMU, Moradabad.

<sup>2,4</sup>Assistant professor, Department of General Surgery, Teerthankar Mahaveer Medical College, TMU, Moradabad.

<sup>3</sup>Professor, Department of General Surgery, Teerthankar Mahaveer Medical College, TMU, Moradabad.

<sup>5</sup>Post Graduate Resident, Department of General Surgery, Teerthankar Mahaveer Medical College, TMU, Moradabad.

Received: December 2016

Accepted: January 2017

**Copyright:** © the author(s), publisher. It is an open-access article distributed under the terms of the Creative Commons Attribution Non-Commercial License, which permits unrestricted non-commercial use, distribution, and reproduction in any medium, provided the original work is properly cited.

### ABSTRACT

Pilonidal disease is a very common anorectal problem that most often arises in the hair follicles of the natal cleft of the sacrococcygeal area. Successful management depends on adherence to well-described surgical principles based on knowledge of pathogenesis and the patient's presentation. Considerable morbidity from prolonged wound Care can be avoided in these typically healthy patients when their disease is cured at initial presentation.

**Keywords:** Anorectal, Pilonidal Disease, Sacrococcygeal.

### INTRODUCTION

Pilonidal disease is a very common anorectal problem that most often arises in the hair follicles of the natal cleft of the sacrococcygeal area.<sup>[1]</sup>

During the Second World War, pilonidal disease very commonly appeared in jeep drivers, leading to the disease being known as, "jeep disease"<sup>[2]</sup>

Pilonidal sinus disease, was first described by Mayo in 1833 and named by Hodges in 1880<sup>[3]</sup>

The term pilonidal is derived from the Latin words for hair (pilus) and nest (nidus).<sup>[4]</sup>

#### Name & Address of Corresponding Author

Dr. Malika Agrawal  
Assistant professor,  
Department of General Surgery,  
Teerthankar Mahaveer Medical College, TMU, Moradabad.

#### **Incidence**

An incidence of 26 cases per 100,000 people was calculated by Sondenaa and others in a study of 322 patients with pilonidal disease.<sup>[5]</sup>

It is, however, more common in young adult men, a population with an incidence of 1.1%.<sup>[6]</sup>

#### **Sex –**

- It affects males twice as much as females<sup>[1]</sup>
- Men are thought to be at higher risk because of their hirsute nature<sup>[1]</sup>

#### **Age group –**

- Most common in young adults of working age.<sup>[1]</sup>
- Pilonidal disease affects men<sup>[7,8]</sup> between 16-25 years of age most often.

**Predisposing factors-** Pilonidal sinus is also associated with –

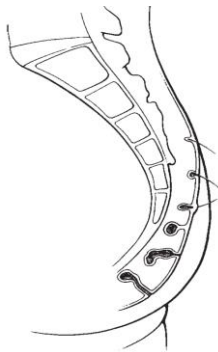
- Obesity (37%),<sup>[1,9]</sup>
- Sedentary occupation (44%)<sup>[1,9]</sup>
- Local irritation or trauma (34%)<sup>[1,5]</sup>
- Jeep drivers in World War II were subjected to this type of local irritation so frequently that Louis Buie, a Mayo Clinic proctologist, recognized the association and described it in 1944 as "jeep disease."<sup>[10]</sup>
- Personal hygiene does not seem to be implicated.<sup>[5]</sup>

Usually it is associated with obese<sup>[11,12]</sup> and hirsute individuals who experience profuse sweating and have a sedentary lifestyle.<sup>[2,13]</sup>

### PATHOGENESIS

- Today pilonidal sinuses are widely accepted to be acquired abnormalities<sup>[14,15]</sup>
- Pilonidal disease is caused by – hair invading the skin at the natal cleft.[Figure-01]<sup>[9]</sup>
  - ❖ This hair causes a foreign body reaction that commonly leads to a hair-filled abscess cavity [Figure 1].<sup>[9]</sup>
  - ❖ Midline pits are the sine qua non of pilonidal disease and represent hair follicles that have become infected or inflamed.<sup>[16]</sup> The resulting folliculitis produces edema that obstructs each follicle's opening.<sup>[9]</sup>
  - ❖ Over time, hair shafts are drawn into the pits by motion from the buttocks, which produces a vacuum effect.<sup>[9]</sup>
  - ❖ Expulsion in the reverse direction is prevented by barbs on the hair shafts.<sup>[9]</sup>

- ❖ Keratin accumulation distends the follicle, which eventually forms an epithelialized tube.<sup>[9]</sup>
- ❖ This tube may rupture into underlying subcutaneous fat, forming an abscess.<sup>[9]</sup>
- ❖ When an abscess forms, it drains back to the skin through true sinus tracts.<sup>[9]</sup>
- The etiology of pilonidal disease as a foreign body reaction is supported by histological examination.<sup>[9]</sup>
- It demonstrates foreign body giant cells associated with hair shafts that are embedded in chronic granulation tissue lining the abscess cavity and sinus tracts.<sup>[17,18]</sup>
- Hair within the abscess cavity is present in approximately two thirds of cases in men and one third of those in woman.<sup>[19]</sup>



**Figure 1: Pathogenesis. Hair invading skin at the natal cleft causes a pilonidal abscess and sinus tracts.<sup>[9]</sup>**

## CLINICAL PRESENTATION

Affected patients are typically in their middle to late 20s and have had Symptoms for 4 to 5 years at initial presentation.<sup>[5,20]</sup>

### Location -

- Generally, the disease is seen in the natal cleft in the sacrococcygeal region<sup>[21]</sup>
- It is usually located in the sacrococcygeal area, but is also found at, other sites such as in the umbilicus, the axilla, on the sole of the foot, the penis, the clitoris and in the anal canal<sup>[22]</sup>
- Midline pits are the Distinguishing feature, occurring in 100% of cases, and they can typically be identified 4 to 8 cm from the Anus.<sup>[5,19]</sup>
- Pilonidal disease may arise in one of three forms:<sup>[9]</sup>
  - ❖ Quiescent phase
  - ❖ Acute abscess<sup>[9]</sup>
  - ❖ Sinus tracts<sup>[9]</sup>
  - ❖ Complex disease characterized by chronic or recurrent abscesses with extensive, branching sinus tracts<sup>[9]</sup>

### During quiescent phase -

- Pilonidal sinus is characterized by the existence of a midline pit in the natal cleft typically identified 4 to 8 cm from the anus.<sup>[23]</sup>
- The skin enters the sinus giving the opening a smooth edge.<sup>[23]</sup>
- This primary tract leads into a subcutaneous cavity, which contains granulation tissue and usually a nest of hairs that are present in two thirds of cases in men and in one third of those in women and may be seen projecting from the skin opening.<sup>[23]</sup>
- Many patients have secondary lateral openings 2 to 5 cm above the midline pit.<sup>[23]</sup>
- The skin opening and the superficial portion of the tract are lined with squamous cell epithelium, but the deep cavity and its extensions are not.<sup>[23]</sup>

### Acute abscess formation in pilonidal sinus tract(s)

- The common form of pilonidal disease is an acute abscess along with sinus tract formation.<sup>[24]</sup>
  - ❖ This position distinguishes the disease from other common anorectal problems, Such as perirectal abscesses and anal fistulae, which are typically found near the anus.<sup>[9]</sup>
  - ❖ Symptoms related to pilonidal abscess include –<sup>[9]</sup> Fever, chills, and pain, and intermittent discharge or Bleeding is common from sinus tracts.

### Sinus tracts

As the acute abscess resolves, whether spontaneously or with treatment, chronic sinus Tracts develop toward the skin.<sup>[9]</sup>

### Complex disease

- Characterized by chronic or recurrent abscesses with extensive, branching sinus tracts<sup>[9]</sup>
- Chronic or recurrent Abscesses with extensive, branching sinus tracts develop in a small minority of patients.<sup>[9]</sup>
- This complex variant of the disease may stem from prolonged neglect of symptoms but also occurs despite appropriate treatment.<sup>[9]</sup>

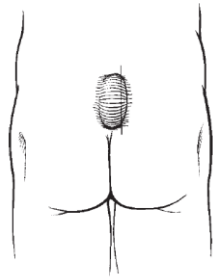
## MANAGEMENT

- Treatment of pilonidal disease depends on the presentation.<sup>[9]</sup>
- Intervention may range from simple incision and Drainage to wide excision with extensive reconstructive procedures.<sup>[9]</sup>
- The treatment of pilonidal disease is mostly surgical<sup>[23]</sup>
- Clear criteria for selecting the treatment method do not exist<sup>[25]</sup>. There is no consensus regarding the optimal surgical technique<sup>[21]</sup>

- Ideally, the selected treatment should involve a simple procedure with minimal morbidity, a short healing time, and low recurrence rates.<sup>[9]</sup>
  - Surgical principles important for successful management of pilonidal sinus disease include unroofing or excising all midline pits and sinus tracts as well as placing any surgical incision off midline.<sup>[9]</sup>
  - Flattening/lateralization of the intergluteal sulcus, prevention of seroma formation, reduction of wound tension, and prevention of wound breakdown and scar formation have been suggested to accelerate wound healing and reduce recurrence<sup>[27]</sup>
  - Tension-free wound closure was important in the surgical treatment of pilonidal sinus.<sup>[21]</sup>
  - Recurrence is affected by a deep intergluteal sulcus, the effect of vacuum developing between the buttocks, and a midline incision scar<sup>[26]</sup>.
  - Techniques such as shaving [6 art-10], phenol administration<sup>[28]</sup>, and cryosurgery<sup>[29]</sup> originally used to treat the disease were found to be inadequate.<sup>[21]</sup>
  - **Role of Antibiotics**
    - ❖ Bacterial colonization of pilonidal sinuses has historically Ranged from 50 to 70%, typical isolates including Staphylococcus aureus and anaerobes such as bacteroides<sup>[30-32]</sup>
    - ❖ Studies Suggest that there is no role for empirical antibiotics in the management of surgically excised pilonidal disease and that antibiotics should be reserved for patients with clinical evidence of infection.<sup>[9]</sup>
  - The most commonly used procedures today are:
    - ❖ Simple incision and drainage
    - ❖ Laying open the tract –
      1. Buie technique
      2. Lord and millar technique
      3. Bascom technique
    - ❖ Injecting phenol as a sclerosing agent into pilonidal Sinuses (maurice and greenwood)
    - ❖ Excision without primary closure
    - ❖ Excision and primary closure
    - ❖ Marsupialization (partial closure)
    - ❖ Fistulotomy
    - ❖ Plastic surgical procedures
      1. Fasciocutaneous flaps like the V-Y flap
      2. Rhomboid excision and the Limberg flap
      3. Karydakis procedure
      4. Z-plasty closure
      5. Gluteus maximus myocutaneous flap
      6. Modified Dufourmental flap
      7. S-type oblique excision
      8. Bascom technique
  - **Indication** - This is usually reserved for acute infective swelling<sup>[23]</sup> where relief of pain is urgent.<sup>[23]</sup> After inflammation has subsided, a permanent treatment can be applied.<sup>[23]</sup>
  - **Procedure** -
    - ❖ Simple incision implies a midline incision through the mouths of the pits and is effective in those cases of so-called raphe cannulization where infection spreads from pit to pit<sup>[33,34]</sup>. After unroofing the tract it is cleaned and drained. The final cure is done after the end of inflammation<sup>[35,36]</sup>.
    - ❖ To improve the chance of cure and decrease the risk of recurrence, many authors recommend taking measures beyond simple incision and drainage.<sup>[9]</sup> A lateral Incision should be made over the cavity so that midline pits do not interfere with the healing wound [Figure 2].<sup>[9]</sup> The cavity should also be vigorously curetted, debriding the walls of embedded hairs and the surrounding skin should be meticulously depilated at the time of operation and over subsequent weeks.<sup>[9]</sup> However, many patients describe this important phase of treatment as inconvenient and difficult<sup>[9]</sup>.
  - To improve the results, some authors recommend hair removal from natal cleft area. Techniques which can be used are –
    - ❖ Trimming, shaving, and Plucking are typically recommended for hair removal<sup>[9]</sup>
    - ❖ **Laser** depilation of the natal cleft –
      1. Laser depilation of the natal cleft has been suggested, and it has been shown to be effective.<sup>[37,38]</sup>
      2. Laser depilation has also been described as definitive nonoperative treatment of recurrent pilonidal disease.<sup>[9]</sup>
      3. although laser therapy does seem to be An effective adjunct to surgery, it is not regarded as Curative in and of itself.<sup>[38]</sup>
- Result** - Recurrence is frequent<sup>[23]</sup>. The patients who are more likely to experience failure or recurrence are predicted by significantly more midline pits and lateral sinus tracts.<sup>[39]</sup>
- Laying open the tract** –
- ❖ Buie technique
  - ❖ Lord and millar technique
  - ❖ Bascom technique
- The simplest procedure to manage pilonidal sinuses is laying open the tract.<sup>[9]</sup>
- Buie technique** –
- This was originally described by Buie in 1938.<sup>[40]</sup>

### Simple incision and drainage

- With this technique the surgeon simply unroofs the midline and lateral sinus tracts, which are allowed to heal by secondary intention.<sup>[9]</sup>



**Figure 2: Incision and drainage. The incision should be made Lateral to midline.**<sup>[9]</sup>

#### Lord and millar technique –

- Lord and millar Proposed a closed technique in which the sinus tracts are not unroofed but instead de'brided with a "bottle" Brush.<sup>[41]</sup>
- They also recognized the importance of the tiny midline pits in the pathogenesis of the disease and excised them down to the cavity, effectively unroofing them.<sup>[9]</sup>

#### Bascom technique -

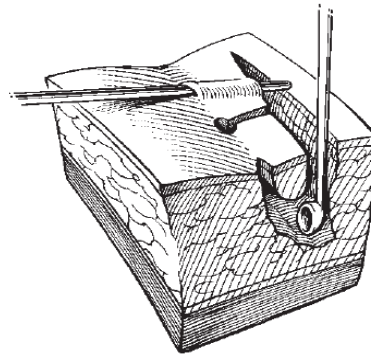
- The importance of avoiding midline incisions and placing any healing wounds off midline to reduce recurrence was recognized by bascom. [Figure 03]<sup>[16]</sup>
- In bascom's procedure, a lateral incision is made over the sinus cavity, which is curetted to remove hair and granulation tissue.<sup>[9]</sup>
- He excised the midline pits and Sinus tracts rather than simply brushing the sinus tracts as in lord's procedure<sup>[9]</sup>
- The incision is left open with a light dressing to heal by secondary intention.<sup>[9]</sup>
- Recurrence requiring reoperation occurred in 10% of Patients with a mean follow-up of 12 months.<sup>[16]</sup>
- To reduce the risk of recurrence in our practice, we lay open all midline pits And sinus tracts toward the lateral incision rather than Excising them [Figure 03].<sup>[42]</sup>

**Complications** of bascom's Procedure include a 4% risk of hemorrhage and an 8% Risk of abscess formation at the lateral incision.<sup>[9]</sup>

#### Injecting phenol as a sclerosing agent into pilonidal Sinuses (maurice and greenwood) –<sup>[9]</sup>

- Injecting phenol as a sclerosing agent into pilonidal Sinuses promotes healing by de'briding the tract.<sup>[9]</sup>
- It was first proposed by maurice and greenwood in 1964 as an alternative to more extensive surgical procedures.<sup>[9]</sup>

- Its efficacy has since been demonstrated in several studies, although overall results are mixed.<sup>[43]</sup>
- After one To two injections over 2 months, successful healing rates Of nearly 70% have been reported.<sup>[44,45]</sup>
- It is a simple Operation that can be done under local anesthesia as an Outpatient procedure.<sup>[9]</sup>
- Reported recurrence rates, however, Vary widely from 6.5% to 40.5%.<sup>[45,46]</sup>



**Figure 3: Bascom technique - Incision and drainage. Midline pits and sinus tracts are laid open toward the lateral incision, and the cavity is curetted.**<sup>[9]</sup>

#### Excision without primary closure

- **Indication** -Excision is used for chronic and recurrent pilonidal sinuses.
- **Procedure -**
  - ❖ Excision of all involved skin and subcutaneous tissue may be necessary for definitive treatment. These wounds may then be managed openly,with healing by secondary intention, allowing the wound to granulate, or is closed by primary suture<sup>[47,48]</sup>. Laying the sinus open permits adequate drainage
- **Result –**
  - ❖ Lower recurrence rates.<sup>[49]</sup>
- **Disadvantage -** The healing requires more time<sup>[49]</sup>. Patients, who are typically young, otherwise healthy, and active, these wounds cause considerable social and economic disability.<sup>[9]</sup>
- **Advantage -** The open approach has the advantage of brief hospitalization, but substantial morbidity results from prolonged healing and frequent, uncomfortable dressing changes.<sup>[9]</sup>

#### Negative pressure dressings (vac therapy)

- Negative pressure dressings, which promote granulation, have been suggested as an alternative to open packing.

- Primary vac therapy (v.a.c. Therapy 1, kinetic concepts, san antonio, tx) following excision of pilonidal disease has been reported with Favorable results.<sup>[24-26]</sup>
- Duxbury and others first described vac therapy in one patient following excision of a chronic pilonidal sinus.<sup>[24]</sup> They applied the device For 6 weeks, and the wound was completely healed by 8 weeks.
- In randomized controlled Trials compared with wet-to-dry dressing changes, vac Therapy has demonstrated significantly faster healing of Chronic wounds.<sup>[27,28]</sup>
- It may be performed as an outpatient procedure with low risk of primary failure or infection while accelerating healing and reducing the frequency of dressing changes.
- Negative pressure exerted on Wounds has been shown to increase local blood flow, Upregulate cell proliferation, decrease bacterial counts, And facilitate wound granulation.<sup>[29,30]</sup>
- The benefits of Negative pressure wound therapy should be applicable to Pilonidal disease and early reports are encouraging; however, follow-up for recurrence has not been reported.

#### Excision and primary closure -

- **Procedure** - In the primary suture the pilonidal sinus is excised and the wound sutured by using deep tension sutures tied over a gauze dressing.<sup>[23]</sup>
- **Advantage** - The advantages are quicker healing and an early return to work<sup>[50,51]</sup>
- **Result-**
  - ❖ Recurrence, however, is also more frequent in the primary closure group (10%) compared with the open (5%).<sup>[17]</sup>
  - ❖ The reported recurrence level with primary midline closure after excision is 20%–42%<sup>[52,53]</sup>
  - ❖ The reported recurrence level 0.9–5.6% in primary closure after oblique excision<sup>[27,54]</sup>

#### Marsupialization (partial closure)

**Indication** - absence of inflammation and that the case is not a recurrence<sup>[55]</sup>.

**Procedure** – Marsupialization involves milossis and opening up of the cavity<sup>[56-58]</sup>. After excision of the sinus front and lateral tracts the cavity is scrubbed to remove hair and granulation tissue. Then, the skin flaps are sutured to the presacral fascia and the wound healing is done by secondary intention<sup>[33,59]</sup>. It is vital to have a strong front tract in order to succeed.

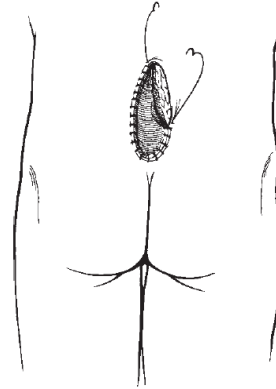
**Advantage** - Acceptably short healing period<sup>[25]</sup>. Reduces the size of pilonidal wounds and has been shown to decrease healing time.<sup>[60,61]</sup>

**Disadvantages** - This approach is preferred over standard open management but still requires multiple Dressing changes each day over a prolonged period of Time [Figure 04].<sup>[9]</sup>

**Result-** it had a low percentage of recurrence<sup>[25]</sup>

#### Fistulotomy

**Procedure** – Fistulotomy involves milossis of the cavernous resource, opening up, removal of hair and scrubbing of granulation tissue and healing by secondary intention<sup>[62,63]</sup>



**Figure 4: Marsupialization.** The skin edge is sutured to the base of the wound. Figure used by permission of mayo foundation for medical education and research. All rights reserved.<sup>[9]</sup>

#### Plastic surgical procedures –

- Infrequently, patients develop complex pilonidal disease, which is characterized by chronic or recurrent abscesses and extensive, branching sinus tracts.<sup>[9]</sup> This manifestation of the disease demands a more aggressive surgical approach, and definitive treatment requires wide excision of all involved tissue.<sup>[9]</sup> Primary closure of these wounds is not a viable option given a dehiscence rate of up to 37%, and open management with healing by secondary intention is not suitable because of the length of time that would be required for healing.<sup>[30]</sup> Reconstructive procedures are typically required in these cases.<sup>[9]</sup>
- Plastic surgery techniques that include these procedures do not only cover the wound but also, in theory, fatten the natal cleft, reduce hair accumulation, mechanical irritation and risk of recurrence<sup>[1,7]</sup>
- Several authors have maintained that the ideal treatment in pilonidal sinus surgery can be achieved with flattening and lateralization of the natal cleft<sup>[27,64]</sup>
- Historically, surgical treatment of pilonidal sinus began with excision and marsupialization or excision and primary closure. Today, these methods have been replaced by excision and closure with advancement flap techniques,

which have lower recurrence and complication rates and shorter return to work times.<sup>[21]</sup>

- Each offers Relatively short healing time but requires an extensive Operation under general anesthesia and lengthy hospitalization<sup>[9]</sup>
- Complications, including flap necrosis, wound Dehiscence, and infection, are a considerable risk<sup>[9]</sup>
- Various kinds of flaps have been used:
  - ❖ Fasciocutaneous flaps like the V-Y flap
  - ❖ Rhomboid excision and the Limberg flap
  - ❖ Karydakis procedure
  - ❖ Z-plasty closure
  - ❖ Gluteus maximus myocutaneous flap
  - ❖ Modified Dufourmental flap
  - ❖ S-type oblique excision
  - ❖ Bascom technique

#### Fasciocutaneous flaps like the V-Y flap

- Fasciocutaneous flaps like the V-Y flap (for recurrent and complicated sinus disease)<sup>[65]</sup>
- V-to-y advancement flaps likewise have been shown in several series to be reliable and effective in covering large pilonidal wounds.<sup>[9]</sup>
- Schoeller and others demonstrated a mean hospitalization of 7.3 days and Mean healing time of 15.3 days using this procedure.<sup>[47]</sup> in their series of 24 patients, there were no recurrences with A mean follow-up of 4.5 years.<sup>[9]</sup>
- To prevent recurrences in this series, the authors attempted to flatten the natal cleft by deep ithelializing the medial end of the flap and folding it under itself to fill in the wound defect.<sup>[9]</sup>

#### Rhomboid excision and the Limberg flap

1. The Limberg flap technique, first described for the surgical treatment of SPS by Azab et al.<sup>[65]</sup>, is currently one of the most widely used techniques. [Figure 05]<sup>[21]</sup>
2. Although the Limberg flap is a globally accepted technique in the treatment of pilonidal sinus, it was modified by Mentis et al. with translocation of the lower edge neighboring on the anus to 1–1.5 cm lateral to the midline<sup>[65]</sup>.
3. Recurrence rates began to decline significantly as advancement flap techniques with these fundamental properties, such as the Limberg flap, began to be used in pilonidal sinus surgery.<sup>[21]</sup>
4. The largest series reviewed 238 patients at a single center who underwent limberg flap reconstruction. It demonstrated a mean hospitalization of 2.1 days and mean Healing time of 8.0 days.<sup>[9]</sup> Recurrence occurred in 1.26% of patients with mean follow-up of 29 months.<sup>[68]</sup> These recurrences occurred early in the series, and no recurrences were found after the authors modified the procedure, placing the

rhomboid excision lateral to the natal Cleft, avoiding the midline.<sup>[9]</sup> They reported a 0.8% infection rate and no occurrences of flap necrosis, attributing these results to the tension-free suture line, which is easily achieved by mobilizing the relatively soft, loose tissue at the donor site.<sup>[9]</sup> The donor tissue is also well vascularized by musculocutaneous perforators from the superior and inferior gluteal arteries, offering a reliable fasciocutaneous flap.<sup>[9]</sup>

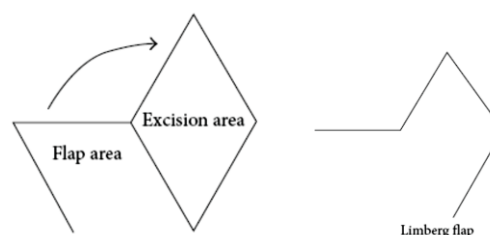


Figure 5: Limberg Flap.<sup>[21]</sup>

#### Karydakis procedure

##### Principle of surgery -

Karydakis was the first to advocate asymmetric Closure of pilonidal wounds to decrease recurrence.<sup>[9]</sup>

This technique avoids placing a wound in the midline at the Depth of the natal cleft.<sup>[9]</sup>

It also flattens the cleft, reducing hair accumulation and mechanical irritation.<sup>[9]</sup>

##### Procedure -

In his advancing flap operation, an asymmetric elliptical incision Is made around all involved tissue down to the Postsacral fascia and the wound is undermined, creating a thick flap that is closed off midline [Figure 6].<sup>[69]</sup>

**Recurrence rate** - Karydakis reviewed his 35-year experience with this Operation, which he performed on 6545 patients, and found a 1% recurrence rate.<sup>[71]</sup> Kitchen attributed Most recurrences to part of the wound encroaching on the midline.<sup>[71]</sup>

##### Z-plasty closure

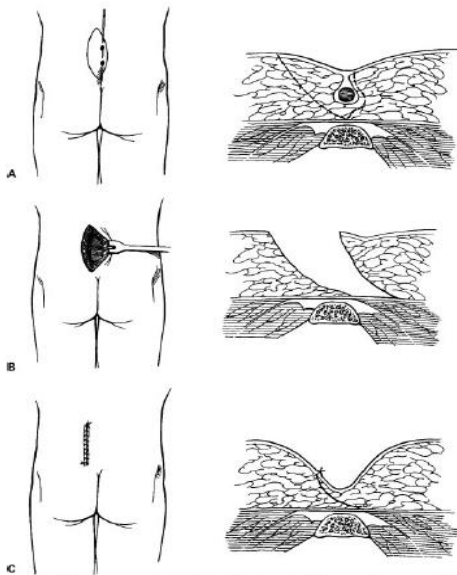
- Z-plasty closure following excision of pilonidal Sinuses was first described in the 1960s.<sup>[72]</sup>
- Disadvantages -
  - ❖ Tip necrosis. (20% incidence)<sup>[9]</sup>
  - ❖ Hypesthesia<sup>[9]</sup>
  - ❖ Discomfort<sup>[9]</sup>
  - ❖ Pruritus<sup>[9]</sup>
  - ❖ Poor cosmesis.<sup>[73]</sup>
- Healing can be achieved in 7 to 10 days. 42
- Recurrences - Very low<sup>[9]</sup>

##### Gluteus maximus myocutaneous flap<sup>[9]</sup>

- For patients in whom repeated interventions fail, Gluteus maximus myocutaneous flap

reconstruction seems to be effective with acceptable morbidity.<sup>[74,75]</sup>

- The procedure has been criticized for being too extensive because it sacrifices a deep functional muscle, but rosen and davidson performed the procedure in five young Men (mean age, 34 years) whose pilonidal disease significantly Affected their lives.<sup>[9]</sup> They found no loss of Strength or range of motion in any of the patients and Felt that in well-motivated patients plagued with Chronic, recurrent, or recalcitrant disease this extensive Reconstructive procedure offers a good chance of cure And acceptable morbidity.<sup>[75]</sup>



**Figure 6: Karydakis procedure.** (A) An asymmetric elliptical incision is carried down to the postsacral fascia. (B) The wound is undermined and (C) closed off midline.<sup>[9]</sup>

**Modified Dufourmentel flap**

A **modified Dufourmentel flap** is shown in figure in which S-type oblique excision is used<sup>[21]</sup>

It is useful in wide lesions.<sup>[21]</sup>

It flattens the intergluteal sulcus and diverts the incision scar from the midline. [Figure 07]<sup>[21]</sup>

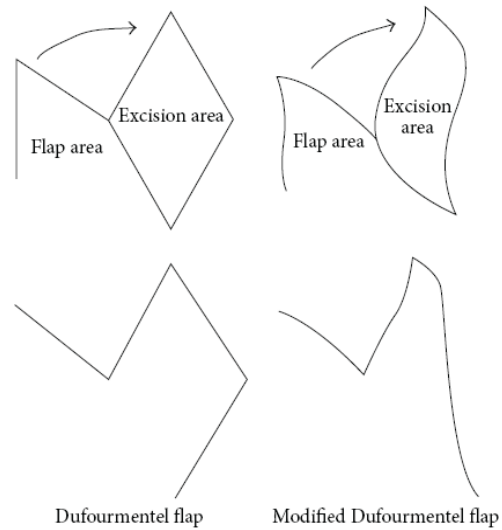
**S-type oblique excision**

Recently, the S-type oblique excision for pilonidal sinus was described, and bilateral advancement of the gluteus maximus fascia in addition to primary repair with this excision has been described as a flap reconstruction technique<sup>[27,76]</sup>. The S-type excision can be used only in lesions smaller than 3 cm with a full-thickness flap as described by Krand et al.<sup>[27]</sup>. S-type oblique excision used together with the modified Dufourmentel flap procedure can be applied to wider lesions.<sup>[21]</sup>

**Bascom technique**

Over 35 years, 37 when a midline incision is used and fails to heal, it can subsequently be placed off

midline using Cleft closure as described by bascom [Figure 08].<sup>[77]</sup>



**Figure 7: Modified Dufourmentel flap.**<sup>[21]</sup>

**Principle-**Restoration of favorable healing conditions, removing the incision from the Warm, moist, bacteria-laden environment found at The depth of the natal cleft.<sup>[78]</sup>

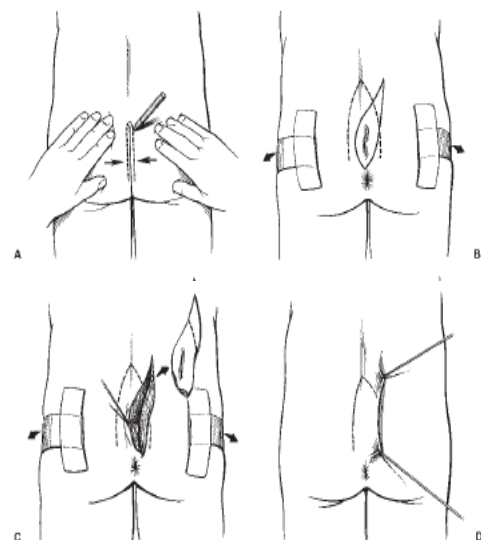
**Technique -**

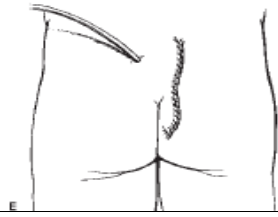
This technique is performed by making an asymmetric elliptical Incision around the wound defect.<sup>[9]</sup>

Unlike the Karydakis procedure, in this procedure no subcutaneous Tissue is excised.<sup>[9]</sup>

Dermis is undermined and a full thickness skin flap is raised and closed off midline.<sup>[9]</sup>

Leaving the subcutaneus tissue in place reduces the Depth of the natal cleft<sup>[9]</sup>





**Figure 8:** (A) The line of contact between the buttocks is marked. (B) The buttocks are taped apart and an asymmetric elliptical incision is drawn around the unhealed midline wound. (C) The incision is carried into the subcutaneous fat to wedge out the unhealed wound. (D) A dermal flap is raised, undermining the skin to the marked line of contact. (E) The skin flap is closed over suction drain.<sup>[9]</sup>

#### Complications of pilonidal sinus –

- Infection
- Chronically draining sinus/fistula
- Malignancy

**Infection**<sup>[80-82]</sup> - The disease may exist as an abscess or it may include cellulites<sup>[79]</sup>

**Chronically draining sinus/fistula**<sup>[79]</sup>

#### Malignancy –

- The first case was reported by Wolff in 1900 and an additionally 68 such cases have been reported in the world literature<sup>[83-88]</sup>.
- Extremely uncommon. Art-03. Malignant degeneration occurs in approximately 0.1% of patients with chronic untreated or recurrent pilonidal disease<sup>[89]</sup>
- The histological type of tumour that arises from a pilonidal sinus is often SCC (90%)<sup>[79,89]</sup>.
- Additionally, basal cell carcinomas, adenocarcinomas and verrucous carcinomas (an uncommon type of SCC) have also been reported.<sup>[90]</sup>
- The most important factor in the incidence of malignancy in pilonidal sinuses appears to be the Length of time that the sinus has been present.<sup>[91]</sup> Frequently pilonidal disease is present two or more decades before development of carcinoma.<sup>[90]</sup>
- The average age of presentation is 49 with an average duration of pilonidal disease of 23 years (philipshen et al., 1981).<sup>[91]</sup> The process of malignant degeneration is similar in pilonidal squamous-cell carcinomas and other chronically inflamed wounds, such as burns, osteomyelitis, scars, skin ulcers and fistulas<sup>[92, 83,84]</sup> Similar to other chronic ulcerative and scarifying cutaneous disorders, it is believed that the development of tumours due to pilonidal sinus is caused by the release of free oxygen radicals by activated inflammatory cells, inducing genetic damage and neoplastic transformation.<sup>[90]</sup> Additionally, the normal repair DNA

mechanism is impaired in chronic inflammation and predisposes patients to malignancy.<sup>[87]</sup>

- The most common presentations are an ulcerating lesion (philipshen et al., 1981) or it can be an incidental Finding at routine histology (baraldi, 1942).<sup>[91]</sup> A pilonidal carcinoma often has a distinctive appearance, and diagnosis can frequently be made on inspection.<sup>[90]</sup>
- A central ulceration is often present, with a friable, indurate, erythematous and fungating margins. Continuity with a cyst is usually easily demonstrated.<sup>[93]</sup>
- The tumour grows locally before metastasizing to inguinal lymph nodes.<sup>[90]</sup>
- Successful treatment with wide excision alone (philipshen et al., 1981) or in combination with Adjuvant chemotherapy (lerner and deitrick, 1979) has been reported.<sup>[91]</sup>
- The surgical treatment options range from observation, incision and drainage, limited excision, unroofing, adypo-lypo facial flap, z plasty, v-y plasty and aggressive excision. After excision, the wound is closed primarily or left open to heal by secondary intention.<sup>[90]</sup>
- Where possible, pilonidal sinuses should be excised early in their history and all excised tissue submitted to histological examination.<sup>[91]</sup>
- If healing is delayed after excision the possibility of malignancy must be considered and biopsy performed.<sup>[91]</sup>

## SUMMARY

Pilonidal disease is a common anorectal problem and a surgical challenge.<sup>[9]</sup> Treatment failure and disease recurrence are prevalent.<sup>[9]</sup> Successful management depends on adherence to well-described surgical principles based on knowledge of pathogenesis and the patient's presentation.<sup>[9]</sup> Abscess cavities must be vigorously debrided to remove all embedded hairs, and depilation of surrounding skin should continue for several weeks.<sup>[9]</sup> Midline pits in all cases must be meticulously sought out and laid Open or excised. Sinus tracts, when present, should be treated similarly.<sup>[9]</sup> Surgical incisions-whether for simple Incision and drainage or more extensive reconstructive procedures-should be asymmetric and closed off midline.<sup>[9]</sup> Considerable morbidity from prolonged wound Care can be avoided in these typically healthy patients when their disease is cured at initial presentation.<sup>[9]</sup>

## REFERENCES

1. Sondanaa K, Andersen E, Nesvik I, Soreide JA. Patient characteristics and symptoms in chronic pilonidal sinus disease. *Int J Colorectal Dis.* 1995;10(1):39-42.
2. Louis A. Buie. Classic articles in colonic and rectal surgery. 1890-1975: Jeep disease (pilonidal disease of mechanized warfare). *Dis Colon Rectum.* 1982;25(4):384-90.



3. T. L. Hull and J. Wu. Pilonidal disease. *Surgical Clinics of North America*. 2002; 82(6)pp. 1169–1185.
4. da Silva JH. Pilonidal cyst. Cause and treatment. *Dis Colon Rectum*. 2000; 43:1146–1156.
5. Sondenaar K, Nesvik I, Anderson E, Natas O, Soreide JA. Patient characteristics and symptoms in chronic pilonidal sinus disease. *Int J Colorectal Dis*. 1995;10:39–42
6. Dwight RW, Maloy JK. Pilonidal sinus: experience with 449 cases. *N Engl J Med*. 1953; 249:926–930
7. Karydakis GE. New approach to the problem of pilonidal sinus. *Lancet*. 1973;2(7843):1414–5.
8. Clothier PR, Haywood IR. The natural history of the post anal (pilonidal) sinus. *Ann R Coll Surg Engl*. 1984;66(3):201–3.
9. Pilonidal Disease Franklin P. Bendewald, M.D.1 and Robert R. Cima, M.D.1 *Clinics In Colon And Rectal Surgery*. 2007; 20(2). Pilonidal Disease/Bendewald, Cima
10. Buie LA. Jeep disease (pilonidal disease of mechanized warfare). *Dis Colon Rectum*. 1982;25:384–390.
11. Bascom J. Surgical treatment of pilonidal disease. *BMJ*. 2008; 336(7649):842–3.
12. Menzel T, Dörner A, Cramer J. [Excision and open wound treatment of pilonidal sinus. Rate of recurrence and duration of work incapacity]. *Dtsch Med Wochenschr*. 1997; 122(47): 1447–51.
13. Kronborg O, Christensen K, Zimmermann-Nielsen C. Chronic pilonidal disease: a randomized trial with a complete 3-year follow-up. *Br J Surg*. 1985;72(4):303–4.
14. King ES. The nature of the pilonidal sinus. *Aust N Z J Surg*. 1947; 16(3):182–92.
15. Patey DH, Scarff RW. Pathology of postanal pilonidal sinus; its bearing on treatment. *Lancet*. 1946; 2(6423):484–6
16. Bascom J. Pilonidal disease: origin from follicles of hairs and results of follicle removal as treatment. *Surgery*. 1980;87:567–572
17. Frankowiak JJ, Jackman RJ. The etiology of pilonidal sinus. *Dis Colon Rectum*. 1962;5:28–36
18. Hardaway RM. Pilonidal cyst—neither pilonidal nor cyst. *Arch Surg*. 1958;76:143–147
19. Notaras MJ. A review of three popular methods of treatment of postanal (pilonidal) sinus disease. *Br J Surg*. 1970;57:886–890
20. Kooistra HP. Pilonidal sinuses. Review of the literature and report of three hundred and fifty cases. *Am J Surg*. 1942;55:3–17
21. Clinical Study The Evaluation of a Modified Dufourmentel Flap after S-Type Excision for Pilonidal Sinus Disease Murat Yildar, Faruk Cavdar, and Mehmet Kamil Yildiz Hindawi Publishing Corporation The Scientific World Journal. 2013, Article ID 459147, 5 pages
22. Eryilmaz R, Sahin M, Okan I, Alimoglu O, Somay A. Umbilical pilonidal sinus disease: predisposing factors and treatment. *World J Surg*. 2005; 29: 1158–60.
23. Pilonidal sinus: a comparative study of treatment methods Varnalidis, I., Ioannidis, O., Paraskevas, G., Papapostolou, D., Malakozis, S.G., Gatzos, S., Tsigkriki, L, Ntoumpara, M., Papadopoulou, A, Makrantonakis, A., Makrantonakis, N. *Journal of Medicine and Life*. 2014;7(1): pp.27–30
24. Bendewald FP, Cima RR. Pilonidal disease. *Clin Colon Rectal Surg*. 2007;20(2):86–95.
25. Petersen S, Koch R, Stelzner S, Wendlandt TP, Ludwig K. Primary closure techniques in chronic pilonidal sinus: a survey of the results of different surgical approaches. *Dis Colon Rectum*. 2002;45(11):1458–67.
26. O. Menten, M. Bagci, T. Bilgin, O. Ozgul, and M. Ozdemir, “Limberg flap procedure for pilonidal sinus disease: results of 353 patients,” *Langenbeck’s Archives of Surgery*. 2008; 393(2):pp. 185–189.
27. O. Krant, T. Yalti, I. Berber, V. M. Kara, and G. Tellioglu, “Management of pilonidal sinus disease with oblique excision and bilateral gluteus maximus fascia advancing flap: result of 278 patients. *Diseases of the Colon and Rectum*. 2009;52(6):p. 1172–1177.
28. I. H. F. Schneider, K. Thaler, and F. Kockerling. Treatment of pilonidal sinuses by phenol injections,” *International Journal of Colorectal Disease*. 1994;9(4)pp. 200–202.
29. A.A. Gage and P. Dutta. Cryosurgery for pilonidal disease,” *The American Journal of Surgery*. 1977;133(2)pp. 249–254.
30. Allen-Mersh TG. Pilonidal sinus: finding the right track for treatment. *Br J Surg*. 1990;77:123–132
31. Kronborg O, Christensen K, Zimmermann-Nielsen C. Chronic pilonidal disease: a randomized trial with a complete 3-year follow-up. *Br J Surg* 1985;72:303–304
32. Marks J, Harding KG, Hughes LE, Ribeiro CD. Pilonidal sinus excision—healing by open granulation. *Br J Surg* 1985; 72:637–640.
33. Bascom J, Bascom T. Failed pilonidal surgery: new paradigm and new operation leading to cures. *Arch Surg*. 2002; 137(10): 1146–51.
34. Flannery BP, Kidd HA. A review of pilonidal sinus lesions and a method of treatment. *Postgrad Med J*. 1967;43(499):353–8
35. Bascom J, Bascom T. Utility of the cleft lift procedure in refractory pilonidal disease. *Am J Surg*. 2007;193(5):606–9.
36. Rickles JA. Ambulatory surgical management of pilonidal sinus. *Am Surg*. 1974;40(4):237–40.
37. Odili J, Gault D. Laser depilation of the natal cleft—an aid to healing the pilonidal sinus. *Ann R Coll Surg Engl* 2002; 84: 29–32
38. Schulze SM, Patel Y, Hertzog D, Fares LG 2nd. Treatment of pilonidal disease with laser epilation. *Am Surg*. 2006;72:534–537
39. Jensen SL, Harling H. Prognosis after simple incision and drainage for a first-episode acute pilonidal abscess. *Br J Surg*. 1988;75:60–61
40. Buie LA. *Practical Proctology*. Philadelphia: WB Saunders; 1938.
41. Lord PH, Millar DM. Pilonidal sinus: a simple treatment. *Br J Surg*. 1965;52:298–300.
42. Nivatvongs S. Common anorectal problems. In: Kelly KA, Sarr MG, Hinder RA, eds. *Mayo Clinic Gastrointestinal Surgery*. Philadelphia: WB Saunders; 2004:589–626
43. Maurice BA, Greenwood RK. Conservative treatment of pilonidal sinus. *Br J Surg*. 1964;51:510–512
44. Kelly SB, Graham WJ. Treatment of pilonidal sinus by phenol injection. *Ulster Med J*. 1989;58:56–59
45. Hegge HG, Vos GA, Patka P, Hoitsma HF. Treatment of complicated or infected pilonidal sinus disease by local application of phenol. *Surgery*. 1987;102:52–54
46. Scheider IHF, Thaler K, Kockerling F. Treatment of pilonidal sinuses by phenol injections. *Int J Colorectal Dis*. 1994;9:200–202
47. Armstrong JH, Barcia PJ. Pilonidal sinus disease. The conservative approach. *Arch Surg*. 1994;129(9):914–9
48. Lord PH, Millar DM. Pilonidal Sinus: A Simple Treatment. *Br J Surg*. 1965;52:298–300
49. Miocinovic M, Horzic M, Bunoza D. The treatment of pilonidal disease of the sacrococcygeal region by the method of limited excision and open wound healing. *Acta Med Croatica*. 2000;54(1):27–31.
50. Jones DJ. ABC of colorectal diseases. Pilonidal sinus. *BMJ*. 1992; 305(6850):410–2.
51. Serour F, Somekh E, Krutman B, Gorenstein A. Excision with primary closure and suction drainage for pilonidal sinus in adolescent patients. *Pediatr Surg Int*. 2002; 18(2–3):159–61.
52. H.A.I-HassanKh., I. M. Francis, and P. Neglen, “Primary closure or secondary granulation after excision of pilonidal sinus?” *Acta Chirurgica Scandinavica*. 1990;156(10): pp. 695–699.
53. I. Iesalnieks, A. Furst, M. Rentsch, and K.-W. Jauch. Primary midline closure after excision of a pilonidal sinus is associated with a high recurrence rate. *Chirurg*. 2003;74(5): pp. 461–468.

54. O. Mentés, M. Bağcı, T. Bilgin, I. Coskun, O. Özgül, and M. Özdemir. Management of pilonidal sinus disease with oblique excision and primary closure: results of 493 patients. *Diseases of the Colon and Rectum*. 2006; 49(1): pp. 104–108.
55. Akca T, Colak T, Ustunsoy B, Kanik A Aydin S. Randomized clinical trial comparing primary closure with the Limberg flap in the treatment of primary sacrococcygeal pilonidal disease. *Br J Surg*. 2005;92(9):1081-4.
56. Surrell JA. Pilonidal disease. *Surg Clin North Am*. 1994; 74 (6): 1309-15
57. Solla JA, Rothenberger DA. Chronic pilonidal disease. An assessment of 150 cases. *Dis Colon Rectum*. 1990;33(9):758-61.
58. Spivak H, Brooks VL, Nussbaum M, Friedman I. Treatment of chronic pilonidal disease. *Dis Colon Rectum*. 1996; 39(10):1136-9
59. Bascom JU. Repeat pilonidal operations. *Am J Surg*. 1987; 154(1):118-22.
60. Solla JA, Rothenberger DA. Chronic pilonidal disease: an assessment of 150 cases. *Dis Colon Rectum*. 1990;33:758–761
61. Spivak H, Brooks VL, Nussbaum M, Friedman I. Treatment of chronic pilonidal disease. *Dis Colon Rectum*. 1996; 39: 1136–1139
62. Kitchen PR. Pilonidal sinus: excision and primary closure with a lateralised wound - the Karydakís operation. *Aust N Z J Surg*. 1982;52(3):302-5.
63. Kitchen PR. Pilonidal sinus: experience with the Karydakís flap. *Br J Surg*. 1996;83(10):1452-5.
64. G. E. Karydakís. Easy and successful treatment of pilonidal sinus after explanation of its causative process. *Australian and New Zealand Journal of Surgery*. 1992; 62(5) pp. 385–389.
65. Chintapatla S, Safarani N, Kumar S, Haboubi N. Sacrococcygeal pilonidal sinus: historical review, pathological insight and surgical options. *Tech Coloproctol*. 2003;7(1):3-8
66. A. S. G. Azab, M. S. Kamal, R. A. Saad, K. A. Abou al Atta, and N. A. Ali, "Radical cure of pilonidal sinus by a transposition rhomboid flap. *British Journal of Surgery* 1984; 71(2):pp. 154–155.
67. B. B. Mentés, S. Leventoglu, A. Cihan, E. Tatlicioglu, M. Akin, and M. Oguz. Modified limberg transposition flap for sacrococcygeal pilonidal sinus. *Surgery Today*, vol. 34,no. 5, pp.419–423, 2004
68. Mentés BB, Leventoglu S, Cihan A, Tatlicioglu E, Akin M, Oguz M. Modified Limberg transposition flap for sacrococcygeal pilonidal sinus. *Surg Today* 2004;34:419–423
69. Karydakís GE. New approach to the problem of pilonidal sinus. *Lancet* 1973;2:1414–1415
70. Karydakís GE. Easy and successful treatment of pilonidal sinus after explanation of its causative process. *Aust N Z J Surg* 1992;62:385–389
71. Kitchen PR. Pilonidal sinus: experience with the Karydakís flap. *Br J Surg* 1996;83:1452–1455
72. Monro RS. A consideration of some factors in the causation of pilonidal sinus and its treatment by Z-plasty. *Am J Proctol* 1967;18:215–225
73. Tschudi J, Ris HB. Morbidity of Z-plasty in the treatment of pilonidal sinus. *Chirurg* 1988;59:486–490
74. Perez-Gurri JA, TempleWJ, Ketcham AS. Gluteus maximus myocutaneous advancement flap for the treatment of recalcitrant pilonidal disease. *Dis Colon Rectum* 1984;27: 262–264
75. Rosen W, Davidson JS. Gluteus maximus musculocutaneous flap treatment of recalcitrant pilonidal disease. *Ann Plast Surg* 1996;37:293–297
76. J. K. Kim, J. C. Jeong, J. B. Lee, K. H. Jung, and B. K. Bae, "Spasty for pilonidal disease: modified primary closure reducing tension," *Journal of the Korean Surgical Society*, vol. 82, no. 2, pp. 63–69, 2012.
77. Bascom JU. Repeat pilonidal operations. *Am J Surg* 1987;154:118–122
78. Bascom J, Bascom T. Failed pilonidal surgery: new paradigm and new operation leading to cures. *Arch Surg* 2002;137:1146–1150
79. Pekmezci S, Hiz M, Saribeyoglu K, Akbilen D, Kapan M, Nasirov C, Taşçı H. Malignant degeneration: An unusual complication of pilonidal sinus disease. *Eur J Surg*. 2001; 167: 475-477.
80. Okuş A, Sevinç B, Karahan O, Eryılmaz MA. Comparison of Limberg flap and tension-free primary closure during pilonidal sinus surgery. *World J Surg*. 2012; 36: 431-5.
81. Kaya B, Eris C, Atalay S, Bat O, Bulut NE, Mantoglu B, Karabulut K. Modified Limberg transposition flap in the treatment of pilonidal sinus disease. *Tech Coloproctol*. 2012; 16: 55-9.
82. Humphries AE, Duncan JE. Evaluation and management of pilonidal disease. *Surg Clin North Am*. 2010; 90: 113-24.
83. Abboud B, Ingea H. Recurrent squamous cell carcinoma arising sacrococcygeal pilonidal sinus tract: report of a case and review of the literature. *Dis Colon Rectum*. 1999; 42: 525-7.
84. Gur E, Neligan PC, Shafir R, Reznick R, Cohen M, Shpitzer T. Squamous cell carcinoma in perineal inflammatory disease. *Ann Plast Surg*. 1997; 38: 653-7.
85. Fasching MC, Meland NB, Woods JE, Wolff BG. Recurrent squamous-cell carcinoma arising in pilonidal sinus tract—multiple flap reconstructions. Report of case. *Dis Colon Rectum*. 1989; 32: 153-8.
86. Malek MM, Emanuel PO, Divino CM. Malignant degeneration of pilonidal disease in an immunosuppressed patient: report of a case and review of the literature. *Dis Colon Rectum*. 2007; 50: 1475-7.
87. Cilingir M, Eroğlu S, Karacaoglan N, Uysal A. Squamous carcinoma arising from chronic pilonidal disease. *Plast Reconstr Surg*. 2002; 110: 1196-8.
88. Agir H, Sen C, Cek D. Squamous cell carcinoma arising adjacent to a recurrent pilonidal disease. *Dermatol Surg*. 2006; 32: 1174-5.
89. de Bree E, Zoetmulder FA, Christodoulakis M, Aleman BM, Tsiftsis DD. Treatment of malignancy arising in pilonidal disease. *Ann Surg Oncol*. 2001; 8: 60-4.
90. Case Report; Recurrent squamous cell carcinoma arising in a neglected pilonidal sinus: report of a case and literature review Ramazan Eryılmaz1, Tuna Bilecik2, İsmail Okan3, Orhan Veli Özkan3, Aytekin Çoşkun3, Mustafa Şahin3 *Int J Clin Exp Med*. 2014;7(2):446-450  
[www.ijcem.com/ISSN:1940-5901/IJCEM1312037](http://www.ijcem.com/ISSN:1940-5901/IJCEM1312037)
91. Squamous cell carcinoma arising in a pilonidal sinus presenting with the formation of an abscess N. V. Jamieson, T. B. Goode *Postgraduate Medical Journal*. 1982;58: 720-721.
92. Velitchklov N, Vezdarova M, Losanoff J, Kjossev K, Katrov E. A fatal case of carcinoma arising from a pilonidal sinus tract. *Ulster Med J*. 2001; 70: 61-3.
93. Williamson DJ, Silverman FJ, Taft L. Fine-Needle Aspiration cytology of metastatic squamous cell carcinoma arising in a pilonidal sinus, with literature review. *Diagn Cytopathol*. 1999; 20: 367-70.

**How to cite this article:** Singh H, Agrawal M, Singh NK, Kaul RK, Nabi G. Pilonidal Disease- Review Article. *Ann. Int. Med. Den. Res.* 2017; 3(2):SG18-SG27.

**Source of Support:** Nil, **Conflict of Interest:** None declared