

# Drainage of Abdomen in Peritonitis Due to Gastrointestinal Perforations, Comparison between Tube drain and Corrugated Drain.

Vipin Kumar<sup>1</sup>, S.C. Sharma<sup>2</sup>

<sup>1</sup>Assistant Professor, department of general surgery, Teerthankar Mahaveer Medical College, Moradabad, Uttar-Pradesh, India,

<sup>2</sup>Associate Professor, department of general surgery, Teerthankar Mahaveer Medical College, Moradabad, Uttar-Pradesh, India

Received: June 2017

Accepted: July 2017

**Copyright:** © the author(s), publisher. It is an open-access article distributed under the terms of the Creative Commons Attribution Non-Commercial License, which permits unrestricted non-commercial use, distribution, and reproduction in any medium, provided the original work is properly cited.

## ABSTRACT

**Background:** We do exploratory Laprotomy for peritonitis due to gastrointestinal perforations. Usually patients come late at tertiary centres, we do peritoneal lavage, and put tube drains in one or both flanks, which has a tendency to get blocked leading to collections in different intra-abdominal spaces. **Methods:** In this study, we compared the relative safety and effect of putting the corrugated drain instead of tube drain so that it does not get blocked. Corrugated drains were put in both the flanks and right sub-hepatic space to ensure free drainage from peritoneal cavity. Study was done on 50 patients (tube drains were put on 25 patients and corrugated drains were put on the other 25). Students chi-square test was done for qualitative differences and t-test was done to assess the quantitative differences. The  $p < 0.05$  was considered statistically insignificant. **Results:** Drainage of abdominal cavity/spaces is found to be better by corrugated drain, when compared with tube drain. Complications, collection of pus, tube blockage due to flakes or exudates were more common in tube drainage. However with corrugated drain frequent change of dressing was needed. The hospital stay expenditure and intervention for removal of collection was more in tube drainage. **Conclusion:** Drainage of abdominal cavity by corrugated drains is a safe and an effective method in laparotomy done for peritonitis due to gastrointestinal perforations and should be favoured in comparison to tube drains.

**Keywords:** Exploratory laparotomy, gastrointestinal perforation, peritonitis, tube drain, corrugated drain.

## INTRODUCTION

Peritonitis due to gastrointestinal perforation is a very common disease.<sup>[1]</sup> Mostly it is bacterial, following perforations of duodenum, ileum or large intestine. Common causes are pyloric or pre-pyloric ulcer, tubercular or typhoid perforations of ileum, traumatic or ischaemic perforations.<sup>[1,2]</sup> Causes of large bowel perforations are secondary to lower gastro intestinal malignancy leading to dilatation of colon and causing caecal perforation. The common treatment we do is exploratory laparotomy with thorough abdominal lavage followed by either closure of perforation or resection and anastomosis of bowel. Sometimes we also need to do either ileostomy or colostomy followed by drainage of abdomen.

Drainage can be done by tube drain or by corrugated

drain.<sup>[4]</sup> Recently it was observed that at most centres doctors prefer tube drains as it causes less soiling of clothes, dressings and bed-sheets, with the concept of clean collection of exudates or fluids in the bag.<sup>[13]</sup> We observed that there were left out collections in abdominal cavity due to blockage of tube drains as early as 24 hours after operation so we thought of comparing tube drains with corrugated drains.<sup>[4,8-10]</sup>

## MATERIALS AND METHODS

Prospective study was conducted in the department of General Surgery Teerthankar Mahaveer Medical College and Research Center for 1 year. Fifty patients after written informed consent were selected for study. All patients of peritonitis due to gastrointestinal perforation were selected in the age group of 18 to 70 years. Patients presented with pain in abdomen, abdominal distention, unable to pass flatus faeces, fever low grade and high grade and on examination rigidity and guarding with absent bowel sound with masking of liver dullness and free gas under the right dome of diaphragm were selected for study.

All patients were subjected to exploratory laparotomy with thorough peritoneal lavage and

### Name & Address of Corresponding Author

Dr. S.C. Sharma  
Associate Professor,  
Department of general surgery,  
Teerthankar Mahaveer Medical College,  
Moradabad,  
Uttar-Pradesh,  
India.

surgery for perforation was done. Grahms omental patch in pyloric or pre-pyloric perforations, closure of ileal perforation, resection anastomosis of ileum, ileostomy, colostomy were the few surgeries done. Patients were randomly selected in 2 groups. In 1 group tube drain 36Fr was put in both flanks while in the other group corrugated drain was put in the flanks.(Left-sided was put in paracolic gutter and right sided was put in pelvis). Clinical evaluation of all patients was done in terms of fever, duration of stay , complications, minor wound dehiscence and major wound dehiscence and total expenditure of the patient . Ultrasound abdomen of all patients was done at 5th and 7th post-operative day.

### RESULTS

The prospective study was conducted in our department for the duration of 1 year. 50 patients of peritonitis due to GI perforations were included in the study, each after taking a written consent. Exploratory laparotomy with treatment of their pathology was done. Patients were divided into 2 groups. In one group tube drain was put and in the other group corrugated drain was put. [Table 1] shows the mean duration of hospital stay in 2 groups. It was significantly less in those patients where corrugated drain was put in. Mean duration of hospital stay was 16 +/- 3 days in tube drain group. Mean duration of hospital stay was 9 +/- 2 days in corrugated drain group. So, it was statistically significant.

**Table 1: Comparison of mean duration of hospital stay**

Tube Drain	Corrugated Drain	P value
16 +/- 3 days	9 +/- 2 days	<=0.05

[Table 2] Shows comparison of partial and total wound dehiscence in the two groups. 9 patients out of 25 patients develop partial dehiscence while 4 patients developed total wound dehiscence in tube drain group. Only 4 patients develop partial wound dehiscence while 1 patient developed total wound dehiscence in 25 patients of corrugated drain group. It was also statistically significant.

**Table 2: Comparison of wound dehiscence in 2 groups**

	Tube drain	Corrugated drain	p value
Total patients	25	25	
Complete wound dehiscence	5	1	Significant
Partial wound dehiscence	9	4	Significant

[Table 3] shows abdominal distention in 2 groups. It was not statistically significant (6 +/- 2 days v/s 5 +/- 2 days).

**Table 3: Abdomen Distention Days**

Tube Drains	Corrugated drains	p- value
6 +/- 2 days	5 +/- 2 days	Significant

[Table 4] Fever above 98.6F was present in both groups in post-op period. It remained there for long duration 7 +/- 2 days in tube drain patients and 3 +/- 2 days in corrugated drain group.

**Table 4: Tube and Corrugated Drains.**

Tube Drains	Corrugated drains	p- value
7 +/- 2 days	3 +/- 2 days	Significant

13 patients in tube drain group and 15 patients in corrugated drain group had not fever. So it was statistically significant difference in those who developed fever.

[Table 4] Drain site excoriation of skin was more in patients of corrugated drain compared to tube drain.

### DISCUSSION

Patients develop septic peritonitis due to various causes.<sup>[1,3]</sup> Most common are – pyloric or pre-pyloric perforation or ileum perforation or large bowel perforations.<sup>[19]</sup> Patients do come late at the tertiary centre that leads to massive contamination of peritoneal cavity leading to thick pus adhesions and flakes in the abdominal cavity.<sup>[18]</sup> So, thick pus, flakes are not drained effectively by tube drains as they tend to cause blockage of tube drain or pores present in the tube drain.<sup>[18]</sup> Hence this study was done to find out whether the corrugated drain with wide opening in peritoneal cavity will be able to draw out all the post-operative collection due to inflamed serosa oozing out fluid. Post-operative ultrasound was done in all the patients to localize the collection present in the peritoneal cavity in both the groups. Special focus was to see sub-hepatic collection, collection in the paracolic gutter and collection in pelvis.<sup>[16]</sup>

According to literature post-operative collection or oozing from the peritoneum or serosa depend upon the extent of contamination of the peritoneal cavity or delay in laparotomy after perforation leading to thick pus, flakes and multiple resistant organisms.

The reason of tube drain failing to drain the pus or secretions completely is that it gets blocked by the flakes or thick exudates. While in corrugated drain thick exudates or flakes remain there but it still drains the infected fluid due to its multiple channels and pressure effect. As soon as the pressure rises in the abdominal cavity due to collection, it will automatically come out due to its corrugated nature.<sup>[9,13,16]</sup>

Patients who were put on tube drain remained hospitalized in ICU as well as in the hospital for a longer duration.

In our study, wound dehiscence occurred in 19 patients out of 50 patients. Total 6 patients developed complete wound dehiscence, 5 in the tube drain group while just 1 in the corrugated drain group. Partial wound dehiscence was also high in tube drain group. 3 patients needed secondary

suturing in total dehiscence of group whereas 2 were put on Bagota Bag. All patients with partial dehiscence were managed by conservative treatment. Only skin suturing was done in 6 patients.

Our review of literature suggests similar success in corrugated drain but with time some surgeons preferred tube drain only because corrugated drains caused lot of soiling of dresses in the initial few days which needed frequent change of dressing bed-sheets and clothes of the people.

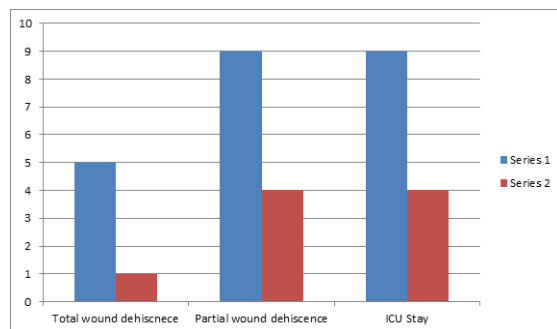


Figure 1: Complications and ICU stay

## CONCLUSION

We conclude that drainage of peritoneal cavity by corrugated drains in patients of septic peritonitis provides adequate and effective drainage as compared to tube drains. It leads to less wound dehiscence less ICU and hospital stay and earlier recovery. Although, in the first few days frequent change of dressings at the drain site is needed and more soiling of bed-sheets and clothes occurs but the advantage of less complications and better outcome outweigh the extra effort or work needed for the dressings.

## REFERENCES

1. Schein M, Saadia R. Peritonitis: contamination and infection, principles of treatment. In: Schein M, Rogers P, editors. Schein's common sense emergency abdominal surgery. 2nd. New York: Springer; 2005. pp. 95–101
2. Holzheimer RG, Gathof B. Re-operation for complicated secondary peritonitis—how to identify patients at risk for persistent sepsis. Eur J Med Res. 2003;8(3):125–34
3. Malangoni M. Contributions to the management of intra-abdominal infections. Am J Surg. 2005;190(2):255–9
4. Price J. Drainage in abdominal surgery Tr Am ass OBG 1; 84-92
5. Ansari MM, Akhtar A, Haleem S, Husain M, Kumar A. Is there a role of abdominal drainage in primarily repaired perforated peptic ulcers? J Exp Integr Med. 2011;2:47–54.
6. Surgical Vacuum Drains: Types, Uses, and Complications Rajaraman Durai, Md, Mrcs; Philip C.H. Ng, Md, Frcs
7. M & M Drains: Irish Medical Journal. June 2001
8. Memon MA, Memon MI, Donohue JH; Abdominal drains: a brief historical review. Ir Med J. 2001 Jun;94(6):164-6.
9. Memon MA, Memon B, Memon MI, et al; The uses and abuses of drains in abdominal surgery. Hosp Med. 2002 May;63(5):282-8.
10. Levy M. Intraperitoneal drainage. American journal of Surgery 1984

11. Drowning in drainage : Quinton de cock American journal of trauma Surgical Drains,Caths,Tubes and Central Lines: Al-Momtan, Ahmed T.
12. Nahai F, Brown RG, Vasconez L: Blood supply to the abdominal wall as related to planning abdominal incisions. Am Surg 1976;42:691–695
13. Moss JP. Historical and current perspectives on surgical drainage surg gynaecology 1981;152
14. Hosgood G. The history of surgical drainage. J Am Med Asso 1990
15. Rees VL, Collier FA: Anatomic and clinical study of the transverse Abdominal incision. Archives of surgery 1943;47:136–146
16. Memon MA, Memon MI, Donohue JH; Abdominal drains: a brief historical review. Ir Med J. 2001 Jun 94(6):164-6.
17. Memon MA, Memon B, Memon MI, et al; The uses and abuses of drains in abdominal surgery. Hosp Med. 2002 May 63(5):282-8.
18. Dougherty SH, Simmons RL. The biology and practice of surgical drains. Part II. Curr Probl Surg. 1992;29:633–730
19. Pai D, Sharma A, Kanungo R, Jagdish S, Gupta A. Role of abdominal drains in perforated duodenal ulcer patients: a prospective controlled study. Aust N Z J Surg. 1999;69:210–13

**How to cite this article:** Kumar V, Sharma SC. Drainage of Abdomen in Peritonitis Due to Gastrointestinal Perforations, Comparison between Tube drain and Corrugated Drain. Ann. Int. Med. Den. Res. 2017; 3(5):SG15-SG17.

**Source of Support:** Nil, **Conflict of Interest:** None declared