

Arrow Injuries in Eastern Odisha; A Series of 13 Cases.

Sudhir Kumar Mohanty¹, Bharat Kumar Behera², Shyam Sundar Behera²

¹Associate Professor, Department of Surgery, SCB Medical College, Cuttack.

²Asst. Professor, Department of Surgery, SCB Medical College, Cuttack.

Received: July 2017

Accepted: July 2017

Copyright: © the author(s), publisher. It is an open-access article distributed under the terms of the Creative Commons Attribution Non-Commercial License, which permits unrestricted non-commercial use, distribution, and reproduction in any medium, provided the original work is properly cited.

ABSTRACT

Background: Although gunshot injuries are the most common penetrating injuries in the developed world, this finding is not the case in the developing world, where knives, spears, arrows, and machetes are the preferred weapons, particularly in tribal societies. Arrow injuries are an extinct form of injuries in most of the developed countries but constitutes 0.1% of the emergency admissions in the developing world. Arrow injuries are frequently seen in tribal areas of Odisha region with homemade bows and arrow. The aim is to study the incidence, various modes of presentation, management and outcome in patients with arrow injuries. **Methods:** A retrospective review and analysis of patient records was done over a period of 3 years from April 2013 to May 2016. The injuries sustained are divided into four groups for the purpose of study. The management depended on the group of the patient. **Results:** Of the 13 patients of arrow injury treated at our hospital there was death of 1 patient (7.69%). The causes of mortality were found to be haemorrhagic shock and septicemia. **Conclusion:** The commonest complication was wound infection seen in 2 patients.

Keywords: Arrow injury, Penetrating injury, Emergency.

INTRODUCTION

Arrow injuries generally are rare on a world wide scale, but there are reports of such type of injuries in high lands of Papua New Guinea, South Africa and Niger.^[1,2] Arrow injuries are an extinct form of injuries in most of the developed countries but constitutes 0.1% of the emergency admissions in the developing world. Various factors are responsible for severity of injury such as distance of the assailant from the target, the fork and trajectory of the arrow, as well as the physical characteristics of the arrow. Despite relatively low velocity (compared to gunshots), the sharpness and propulsion fork of the crossbow may be sufficient to enable penetration. Arrow injuries are frequently seen in tribal areas of Odisha region. The patients are usually tribal who are referred from periphery and received at casualty and managed in the emergency. Patients present with various mode and clinical presentation as chest, thoracic, abdominal and limb injury. The mechanism of injury is a combination of two sharp forces penetrating action and peripheral sharp cutting action of knife. The treatment depends on site of injury, general condition of patient, presence of arrow in situ and depth of penetration.

Name & Address of Corresponding Author

Dr. Bharat Kumar Behera,
Asst Professor,
Department of Surgery,
SCB Medical College, Cuttack
Odisha, India

Acute management of arrow injury is still important in this century and greatly influences the outcome. With the limited facilities, managing patient is challenging to the surgeon. Timely intervention, proper haemostasis, repair of injuries are the components of successful management.

MATERIALS AND METHODS

A retrospective review records and analysis of the data was done extending over period of 3 years from April 2013 to May 2016. All consecutive patients with arrow injury treated after admission at S.C.B Medical College and Hospital, Cuttack were studied. The data studied included personal profile, circumstances of injury, presentation, treatment and complications. All patients were males. For purpose of analysis of data the patients were divided into four groups as follows.

1. Group I: Chest arrow injury.
2. Group II: Abdominal injury.
3. Group III: Thoraco abdominal injury.
4. Group IV: Limb & head and neck injury

RESULTS

A total 13 patients with penetrating arrow injury were managed in a 3 years period. The mean age of patients was 33. All the patients were males between 17 to 45 years of age. Age distribution is shown in [Table 1].

Table 1: Age distribution in patients with arrow injuries

Age range(years)	Number	Percentage
< 10	0	0
11-20	3	23.07%
21-30	2	15.38%
31-40	6	46.15%
41-50	2	15.38%
>50	0	0

There were 3 patients in the group 1. Lungs injury were observed in 3 cases which includes 2 cases of right lungs and one case of left lung injury [Table 2]. Upper lobe was injured most commonly (2 cases). Out of seven cases included in group 2 mesentery was most commonly injured organ seen in 4 cases [Table 3]. Group 3 and group 4 contains two cases each [Table 4 & 5].

Table 2: Injury in Group 1.

Clinical presentation	No of Patients
Lung injury	03
Right Lung	02
Left Lung	01
Upper lobe	01
Middle/Lower lobe	02

The following table shows injury of different organs included in-group 2. Mesentery was most commonly injured in this group (4 cases). Stomach, duodenum, ileum, colon, retroperitoneal hematoma, and kidney injury were observed in one case each.

Table 3: Injury in-group 2.

Organ 2	No of patients
Total no of patients	07
Stomach	01
Duodenum	01
Jejunum	00
Ileum	03
Colon	01
Liver	01
Spleen	00
Pancreas	00
Greater omentum	03
Mesentery	04
Retroperitoneal hematoma	01
Abdominal Aorta	00
Kidney	01
Ureter	00

Table 4: (group III).

Organ2	No of patients
Total no of patients	02
Pericardium	00
Right lung	01
Left lung	00
Inferior venacava	00
Diaphragm	01
Liver	01
Spleen	00
Stomach	01

Table 5: Injury in group 4

Clinical Presentation	No of patients
Total no of patients	02
Axillary wound	00
Thigh wound	01
Forearm	00
Neck	01
Buttock	00

Out of 13 patients 9 patients were farmers and 4 patients were cattle herds man. Six patients presented within 48 hours and rest 7 patients presented >48 hours. Five patients showed injuries in multiple regions of the body.

[Figure 1 & 2] shows the arrow injury of thorax and abdomen involving lungs, liver and diaphragm.

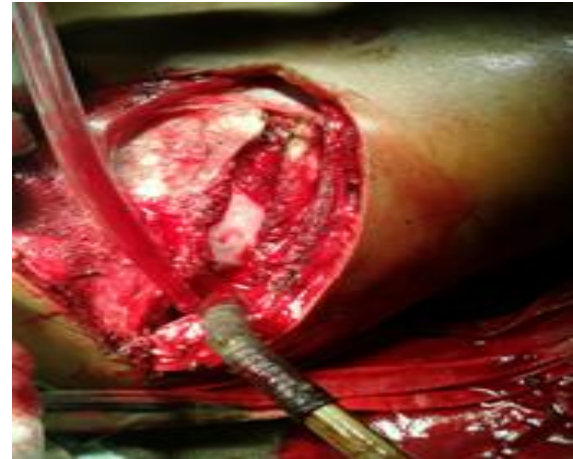


Figure 1: Arrow Injury to body viscera.

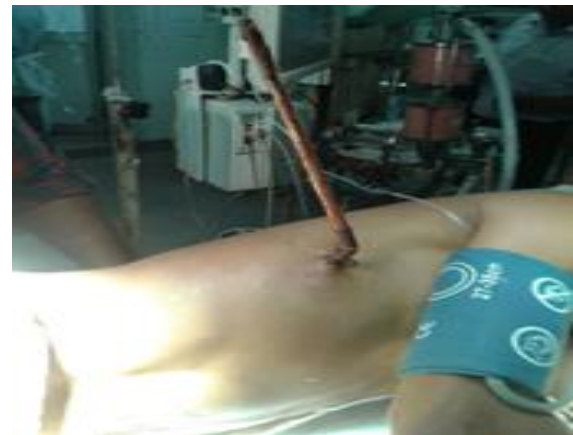

Figure 2: Arrow Injury.

One case was clinically unstable at presentation. Other cases were clinically stable. All cases had arrow in situ. Tetanus prophylaxis and antibiotics were routinely administered. All patients were explored and arrow removed carefully. Most of the patients recovered well. One patient was in shock and expired during course of treatment.

Patients presenting early had short hospital stay (mean hospital stay was 9 days). Those having delayed presentation had longer hospital stay (average 16 days).

Usually the shaft of the arrow had been broken off leaving the tip in the thorax or abdomen. Three patients presented with arrow wounds to the chest, 5 had arrows sticking out of the body. The protruding arrows were not disturbed during preparation or exposure. Three patients had antero lateral thoracotomy.

The immediate indications of thoracotomy were in those with arrow sticking out of the body, those with arrows broken off at skin level and those patients who claimed that the arrow was still inside the body.

DISCUSSION

A majority of tribes Odisha belong to the poor socio-economic group depending on farming or hunting for livelihood. The tribes are vengeful clan fighting over limited resources. The mechanism of injury by arrow is a combination of two sharp forces penetrating action of a dagger and peripheral sharp cutting action of knife.^[5] An average of 7 of the 5,200 emergencies seen in the University of Maidugury Teaching Hospital are due to arrow injuries constituting 0.1% of the emergencies and this is not insignificant considering the fact that it is virtually an extinct form of injury in most of the developed world.^[3] Arrow and spear wound epidemiology and management have been well described from Papua New Guinea.^[4]

Of the 13 patients of arrow injury treated at our hospital, there was mortality in 1 patient (7.69%). The causes of mortality were found to be haemorrhagic shock septicaemia pneumonia with respiratory failure. The commonest complication was wound infection seen in 2 patients. Those with penetrating thoracic wounds were managed conservatively with intercoastal drainage. In patients with abdominal wound, ileum was the most frequently penetrated organ (3/13 i.e. 23.07%) Exploratory Laparotomy was done in all the patients with abdominal wound.

Laceration of tissues is minimal. Because of the sharp margins and pointed ends of the arrowhead the injury is localized to the tissue in direct contact. Radiological evaluation of the patient is important. It should be noted that not all arrow or spear tips are radiopaque. The metallic head is radiopaque as seen in our case, but CT or MRI are preferred investigations in such cases rather than plain X-ray. MRI is useful in identifying wood fragments.^[5,6]

It is important to reiterate the advice of O'Neill et al. that arrows with barbs should be removed in an antero-grade direction along the line of its trajectory to avoid snagging blood vessels and other structures.^[7]

Those with arrow in situ requires careful removal without causing further injury to internal organs. Intestine, lungs and diaphragm were the organs commonly injured. The treatment depends on the site of injury, general condition of patient, presence of arrow in situ and depth of penetration. Majority of the arrow injuries to the chest can be managed with tube thoracostomy drainage alone when mediastinal, cardiac and hilar injuries can be excluded.^[8] For abdominal injuries, laparotomy is mandatory. Stomach, duodenum, jejunum and ileum perforations need to be repaired perfectly in layers.

Patients with multiple perforations in small bowel undergo resection and anastomosis. In cases of gross contamination ileostomy or colostomy were performed. Liver wounds are debrided proper haemostasis are to be achieved. Retroperitoneal haematomas are not to be disturbed unless an active bleed is present. Mesenteric and omental tears are repaired with silk suture. Postoperative drainage of the peritoneal cavity is done in all the patients. Early postoperative mobilization is encouraged and chest physiotherapy provided.

CONCLUSION

The management of arrow injury should be along the lines of standard principles of trauma management. Few patients who presented in a state of shock. Shock management were the first priority. Simple investigations like X-ray and USG usually suffice for workup and planning of the management. Penetrating trauma from arrow shot may lead to potentially life-threatening injuries. A prompt diagnosis, a systematic treatment protocol, and an experienced trauma team are necessary to prevent a potential catastrophe.

REFERENCES

1. Fingleton U. Arrow wounds to heart and mediastinum . Br J Surg 1987;74 (2):126-8.
2. SinghRJ,singhNK.Arrow injury. J Indian Med Assoc.1985;83(2):65-2.
3. VanGurpG,HutcinsonTJ,Alto WA. Arrow wound management in Papua New Guinea. J Trauma.1990;30(2):183-2.
4. Jacob OJ. Penetrating Thoraco abdominal injuries with arrows: Aus NZ J Surg 1995;65:394-7.
5. Green BF, Kraft SP, Carter KD, et al. Intraorbital wood detection by magnetic resonance imaging. Ophthalmology. 1990; 97: 608-611.
6. Specht CS. Orbitocranial wooden foreign body diagnosed by magnetic resonance imaging. Dry wood can be isodense, with air and orbital fat, by computed tomography. Surv. Ophthalmol. 1992; 36: 341-344
7. O'Neill OR, Gilliland G, Delashaw JB, Purtzer TJ. Transorbital penetrating head injury with a hunting arrow: case report. Surg. Neurol 1994; 42: 494-497.
8. Nicolas Peloponissos et al. Penetrating thoracic trauma in arrow injuries. Ann Thoracic Surg.71:1019-1021.

How to cite this article: Mohanty SK, Behera BK, Behera SS. Arrow Injuries In Eastern Odisha; A Series of 13 Cases. Ann. Int. Med. Den. Res. 2017; 3(5):SG10-SG12.

Source of Support: Nil, **Conflict of Interest:** None declared