

## Presentations and Outcomes of Diaphragmatic Injuries – A 15 Year Experience.

Manjit Singh Chahal<sup>1</sup>, Malika Agrawal<sup>2</sup>, Harpreet Singh<sup>3</sup>, Akash Jain<sup>4</sup>, Ramashankar Prasad<sup>4</sup>, Gaurav Mishra<sup>5</sup>

<sup>1</sup>Professor, Department of General Surgery, Teerthankar Mahaveer Medical College, TMU, Moradabad, India.

<sup>2</sup>Assistant Professor, Department of General Surgery, Teerthankar Mahaveer Medical College, TMU, Moradabad, India.

<sup>3</sup>Associate Professor, Department of General Surgery, Teerthankar Mahaveer Medical College, TMU, Moradabad, India.

<sup>4</sup>Senior Resident, Department of General Surgery, Teerthankar Mahaveer Medical College, TMU, Moradabad, India.

<sup>5</sup>Junior Resident, Department of General Surgery, Teerthankar Mahaveer Medical College, TMU, Moradabad, India..

Received: December 2016

Accepted: January 2017

**Copyright:** © the author(s), publisher. It is an open-access article distributed under the terms of the Creative Commons Attribution Non-Commercial License, which permits unrestricted non-commercial use, distribution, and reproduction in any medium, provided the original work is properly cited.

### ABSTRACT

Diaphragmatic rupture is a rare diagnosis and goes undiagnosed unless some complications occur. We report on cases that developed diaphragmatic hernia following complete/partial tear of diaphragm due to trauma to the abdomen.

**Keywords:** Diaphragmatic hernia, Blunt trauma abdomen, Exploratory laparotomy, Lung collapse.

### INTRODUCTION

Acquired diaphragmatic hernias result from all types of trauma, with blunt force accounting for the majority. The first traumatic diaphragmatic hernia was reported by Sennertus in 1541. Diaphragmatic hernias require a high level of suspicion to detect. Patients can be asymptomatic in as many as 53% of hernias from blunt trauma and 44% of those from penetrating trauma. Routine chest x-ray detects only 33% of hernias when interpreted by the trauma team leader at initial evaluation. Missed injuries are associated with significant morbidity and mortality.

#### **Name & Address of Corresponding Author**

Dr. Malika Agrawal  
Assistant Professor, Department of General Surgery,  
Teerthankar Mahaveer Medical College, TMU, Moradabad,  
India.

### CASE SERIES

#### **Case no. 1**

A 14 years old boy presented in the casualty with history of road traffic accident around 45 minutes before. He complained of respiratory difficulty with abdominal pain. Vitals were stable but the saturation was around 75 – 80. On examination abdomen was diffusely tender, bleeding per urethra, absent breath sounds in the left chest. Bedside X ray and USG was suggestive of bilateral hemo thorax with left lung collapse and hemoperitoneum with distended bladder. Bowel sounds were heard in the left hemithorax with absent breath sounds.

ICD was placed on the left hemithorax and Foleys catheter per urethra could not be passed, suggestive of urethral injury. As the bladder was palpable and distended, a supra pubic catheter was placed. Blood tinged urine was evacuated. Patient was shifted for CT thorax and abdomen after being stabilized. The patient gave no history suggestive of congenital nature of diaphragmatic hernia.

Investigations revealed the following injuries -

1. Complete tear of left hemi- diaphragm
2. Bilateral hemo and pneumothorax with multiple rib fracture
3. Splenic contusion
4. Left Renal grade 1 laceration
5. Complete collapse of left lung due to entry of stomach, spleen, greater omentum, left lobe of liver, transverse colon, jejunal and ileal loops into left hemithorax
6. Urinary Bladder and urethral injury (SPC was done)
7. Bilateral acetabulum fracture
8. Massive retroperitoneal hematoma
9. Left pubic bone fracture
10. Multiple spinous processes fracture of lumbar vertebrae.

An emergency laparotomy was planned. After opening the abdomen in layers findings were that stomach, spleen, greater omentum, left lobe of liver, transverse colon, jejuna and ileal loops had prolapsed into left hemithorax. The herniated organs were withdrawn out of It hemithorax; an ICD was placed and the diaphragmatic tear was identified. A linear diaphragmatic hernia measuring approximately 18cms along the central tendon area

was repaired with 2-0 prolene. Thorough peritoneal lavage was given and hemoperitoneum was evacuated. Abdomen was closed after putting drains in the pelvic and left sub diaphragmatic region. Patient was shifted to the ICU for further management. Post operative period was uneventful.

#### **Case no. 2**

A 19 yr old military recruit undergoing physical training fell flat on the ground while doing long jump practice. He developed acute diffuse pain abdomen with vomiting followed by dyspnea and later peritonitis over duration of 3 days of conservative management at primary health care.

At hospital exploratory revealed ruptured diaphragm along the central tendinous area, about 4 cm linear with herniation of entire greater omentum and antimesenteric border of transverse colon approx 6cm long segment with multiple perforations over intrathoracic antimesenteric border of transverse colon.

Resection of perforation bearing segment of transverse colon along with transverse colostomy and mucus fistula of descending colon and excision of necrosed greater omentum with peritoneal wash and drainage, wash of left hemithoracic cavity along with under water seal chest tube drainage done. Closure of diaphragm (double breasting) using 2- 0 prolene suture, saved the life of patient.

#### **Case no. 3**

A 45 Year old male patient having mild upper abdomen pain with radiation to left shoulder of 3 weeks duration, with 3 days history of exacerbation of pain abdomen with high grade fever with chills/rigor, vomiting and septic shock with cardiovascular collapse.

Exploratory laparotomy revealed rupture left dome of diaphragm 4 cm linear tear in transverse direction leading to herniation of stomach, T.colon, G.omentum & spleen, with severe constriction at its neck. Tear required extension of diaphragmatic tear in transverse direction. Two thirds of T.colon was strangulated with distention of necrotic walls. Left hemithorax contained serosanguinous foul smelling fluid with collapse of lung. Excision of necrosed transverse colon along with diversion colostomy and mucous fistula of splenic flexure of colon, omentectomy, wash of left hemithorax and peritoneal cavity with drainage, with ICD placement and repair of tear of diaphragm done with 2-0 prolene suture. Post operative period was stormy due to toxemia and SIRS and early MODS, however patient recovered slowly. Closure of colostomy after 10 weeks was done. Patient was discharged in good condition and he joined back his job.

#### **Case no. 4**

A 24 yr old male patient sustained gun shot wound right lower chest and right upper abdomen, admitted

with complains of pain in entire abdomen and right hemithorax and symptoms of hemorrhagic shock.

Surgical intervention revealed right lung laceration at its inferior most part with tear in pleura along with haemo pneumothorax and collapse of right lung.

Abdominal findings revealed a lacerated wound over right dome of diaphragm towards lateral side, (2 cm linear) communicating with pleural cavity. Underlying liver injury in segment VII, V and a cavity linear lesion tracking through parenchyma of liver with bullet lodged in subcutaneous tissue of posterior abdomen wall with evidence of bleeding from liver along with bile leakage giving rise to haemo – biliary peritoneum.

Penetrating injury of right dome of diaphragm required two interrupted sutures with 2- 0 prolene. Drainage of pleural and peritoneal cavity done, haemostasis achieved with ab-gel packing into bullet's track of liver. A right sided ICD and peritoneal drain in right subphrenic & subhepatic space saved the patients life. Patient fully recovered with no biliary leakage and full expansion of right lung and was back at his profession.

## **DISCUSSION**

### **Pathophysiology**

The pathophysiology of acquired diaphragmatic hernias includes circulatory and respiratory depression secondary to decreased function of the diaphragm, intrathoracic abdominal contents leading to compression of the lungs, shifting of the mediastinum, and cardiac compromise. Smaller diaphragmatic hernias are often not found until months or years later, when patients present with strangulation of intra-abdominal organs, dyspnea, or nonspecific gastrointestinal complaints.

### **Etiology**

By far the most common cause of acquired diaphragmatic disorders is trauma, either blunt or penetrating. Motor vehicle accidents are the leading cause of blunt diaphragmatic injury, whereas penetrating injuries result from gunshot or stab wounds. In contrast to earlier work, several more recent retrospective studies found 75% of their patients to have tears from penetrating injuries. This may result from increasing awareness of the part of providers or the ability to detect small tears via minimally invasive methods.

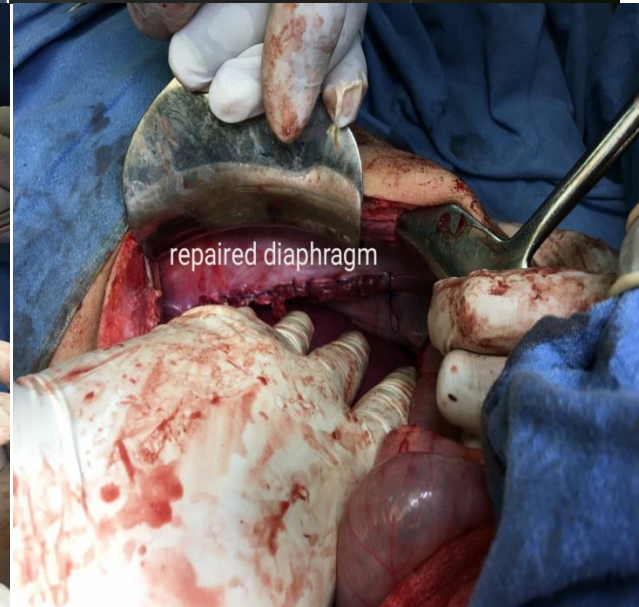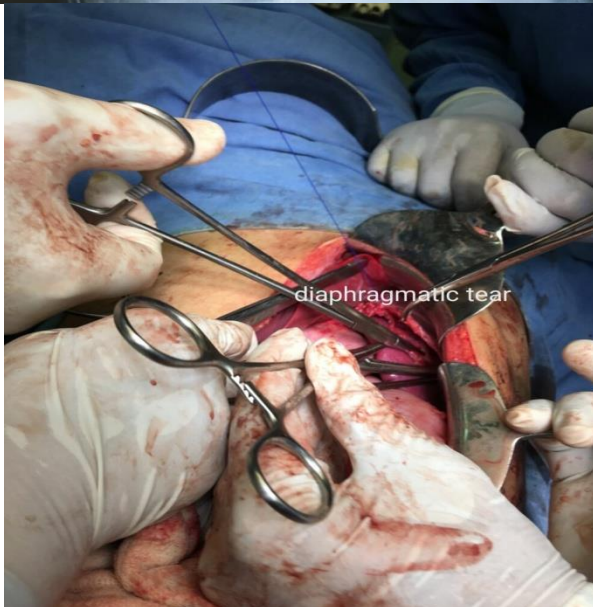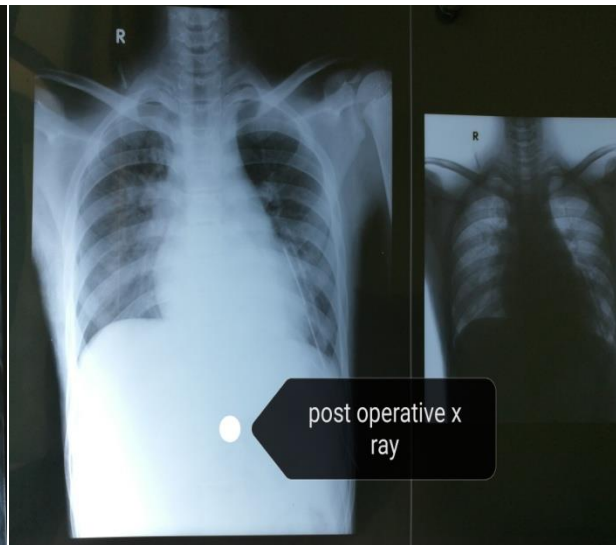
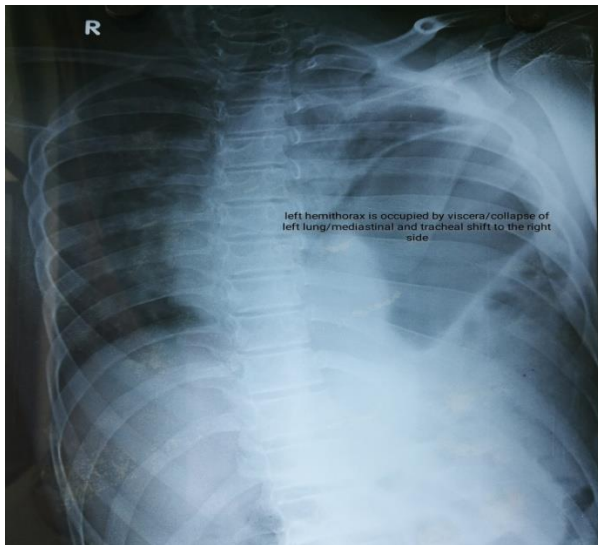
Other rare causes of traumatic rupture include labor in women with prior diaphragmatic hernia repair and barotrauma during underwater dives in patients with history of Nissen funduplications.

The following theories have been postulated to explain the mechanism of rupture for blunt injuries:

- Shearing of a stretched membrane
- Avulsion of the diaphragm from its points of attachment

- Sudden increase in the transdiaphragmatic pleuroperitoneal pressure gradient. The resting pressure differential between the pleural (-5 to -10 cm H<sub>2</sub>O) and peritoneal (+2 to +10 cm

H<sub>2</sub>O) cavities rises to 100-150 cm H<sub>2</sub>O with a large cough and does not injure the diaphragm. Forces transmitted to the abdomen from blunt trauma can raise the pressure gradient to 1000 cm H<sub>2</sub>O.



Left-side rupture is more common than right-side rupture (68.5% vs 24.2%), owing to hepatic protection and increased strength of the right hemidiaphragm. However, the increased prevalence of left-side hernias may also result from weaknesses in points of diaphragmatic embryologic fusion.

Current thought is that the right side has more protection than the left and that it may be slightly stronger than the left. In addition, the liver may provide another protection for the right hemidiaphragm. Children have equal rates of rupture per side, likely because of laxity of liver attachments.

Blunt trauma typically produces large radial tears measuring 5-15 cm, most often at the posterolateral aspect of the diaphragm. In contrast, penetrating trauma can create small linear incisions or holes,

which are less than 2 cm in size and may present late after years of gradual herniation and enlargement. Penetrating injuries to the chest or abdomen also may injure the diaphragm. This specific injury is seen commonly where penetrating trauma is prevalent. This occurs most often from gunshot wounds but can result from knife wounds. Typically, the wounds are small, although occasionally a shotgun blast or an impalement causes a large defect.

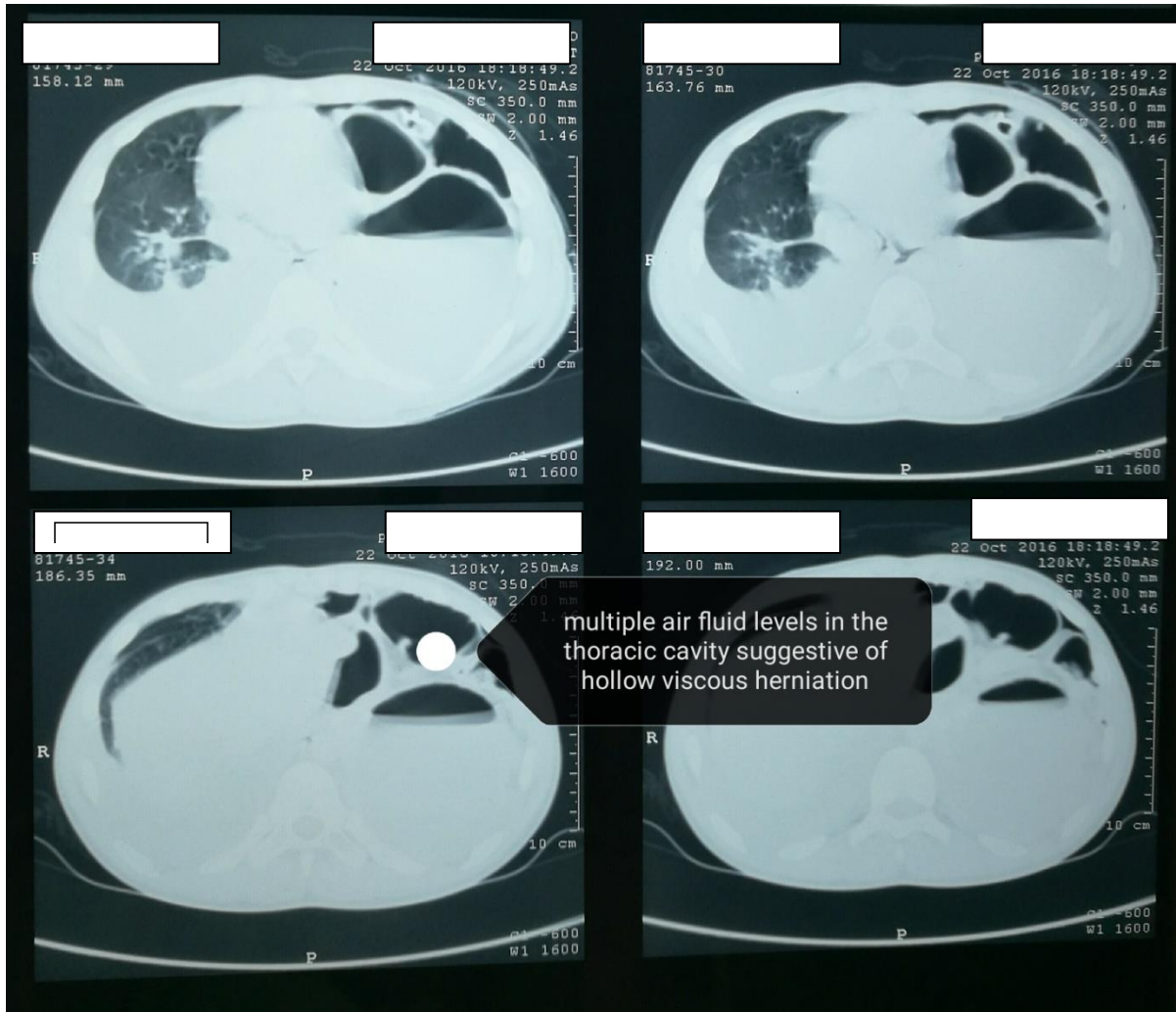
#### **Physical Examination**

Clinical findings in patients with acquired diaphragmatic hernia may include the following:

- Marked respiratory distress
- Decreased breath sounds on the affected side
- Palpation of abdominal contents upon insertion of a chest tube
- Auscultation of bowel sounds in the chest

- Paradoxical movement of the abdomen with breathing

- Diffuse abdominal pain.



### Imaging Studies

#### Chest radiography

Chest radiography is standard in the Advanced Trauma Life Support (ATLS) protocol for a trauma workup. Approximately 23-73% of traumatic diaphragmatic ruptures will be detected by initial chest radiography, with an additional 25% found with subsequent films. Chest radiography is most sensitive for detecting left-side hernias. Chest radiographic findings that indicate traumatic rupture include the following:

- Abdominal contents in the thorax, with or without signs of focal constriction ("collar sign")
- Nasogastric tube seen in the thorax (see the image below)
- Elevated hemidiaphragm (>4 cm higher on the left than on the right)
- Distortion of diaphragmatic margin

#### Computed tomography

Conventional computed tomography (CT) has been reported to have a sensitivity of 14-82%, with a specificity of 87%. [12] Helical (spiral) CT has

increased sensitivity, 71-100%, with higher sensitivity on the left than on the right. [11] CT findings indicative of rupture include the following:

- Direct visualization of injury
- Segmental diaphragm nonvisualization
- Intrathoracic herniation of viscera
- "Collar sign"
- Peridiaphragmatic active contrast extravasation

#### Ultrasonography

Ultrasonography (focused assessment with sonography for trauma [FAST]) has been reported to detect diaphragmatic hernias. During visualization of each upper quadrant, the movement of the diaphragm was noted to be decreased in patients with diaphragmatic hernias. This technique is limited in patients who are on mechanical ventilation because of the positive pressure of the thoracic cavity.

#### Approach Considerations

In traumatic rupture of the diaphragm, surgical intervention is mandatory, whether the patient presents immediately or some time after the trauma. The high incidence of concomitant intra-abdominal injuries dictates the need for emergency abdominal exploration in the acute trauma setting after initial resuscitation is accomplished.

Patients who present in the latent phase or long after the trauma require repair because the hernia contents may become strangulated, leading to dead gut, stomach, liver, spleen, or other organs.

Relatively no contraindications have been reported for repair of an acquired diaphragmatic hernia. In the trauma setting, the patient must be adequately resuscitated before he or she is transported to the operating room. Many small injuries are discovered during exploratory laparotomy for the repair of other intra-abdominal injuries.

Diaphragmatic hernias should always be repaired. Lack of repair of a diaphragmatic hernia can lead to incarceration and strangulation of intra-abdominal contents or respiratory dysfunction.

### **Surgical Therapy**

If the diaphragmatic injury is discovered during the acute phase of trauma, the standard surgical approach is laparotomy or, less commonly, thoracotomy. The generally accepted protocol in the acute setting is that a diaphragmatic rupture is approached via a celiotomy because concomitant intra-abdominal injuries are more likely to be present than thoracic injuries are (84% vs 53%).

The problem regarding which approach to use arises when the diaphragmatic injury goes unnoticed for months or years. More surgeons approach long-standing hernias via a transthoracic or thoracoabdominal approach because the herniated intra-abdominal contents tend to be firmly attached to intrathoracic structures, making a transabdominal approach difficult.

Minimally invasive techniques for diaphragmatic repair are becoming more common than before. With advances in technology and surgical skills, repairing both acute and chronic diaphragmatic hernias is possible with laparoscopic, thoracoscopic, or combined approaches.

### **Operative details**

As in any case of trauma, the patient's condition must be stabilized, and he or she must be resuscitated to the extent possible before operative treatment. People with traumatic hernias frequently have concomitant injuries and require emergency exploration.

With traumatic ruptures, the surgical approach depends on the timing of the diagnosis with the surgical intervention. In the acute phase of trauma, an abdominal approach is preferred. In the latent phase of trauma, a transthoracic approach may be

necessary because patients often have adhesions to intrathoracic organs.

Acute injuries are repaired with monofilament permanent sutures. Small lacerations may be repaired by using interrupted, horizontal mattress, or figure-eight stitches; larger lacerations may be repaired with continuous or double-layered closures. Absorbable sutures are associated with a high rate of recurrence. There is some limited evidence to suggest that the use of biologic mesh in traumatic diaphragmatic repair may be feasible, at least in chronic cases.

Laparoscopic abdominal exploration in the setting of trauma is becoming a popular way to determine whether diaphragmatic integrity is retained. It provides a minimally invasive mechanism by which the diaphragm can be directly viewed to determine if an injury has occurred. In the absence of other intra-abdominal injuries, the diaphragm can easily be repaired by applying laparoscopic techniques.

The best utility of laparoscopy is with penetrating thoracic and flank injuries when intraperitoneal penetration is being considered and if a projectile injured the diaphragm.

### **Long-Term Monitoring**

Recurrence is possible after traumatic herniation or a congenital diaphragmatic hernia that was repaired in an adult. Therefore, after an anatomic defect is corrected, periodic assessments of pulmonary function and chest radiography are important (see the image below). Although the spontaneous recurrence rate for repaired diaphragmatic hernias is low, small defects in the repair site have been reported; therefore, surveillance is crucial.

## **REFERENCES**

1. Carter BN, Giuseffi J, Felson B. Traumatic diaphragmatic hernia. *Am J Roentgenol Radium Ther Nucl Med.* 1951 Jan. 65(1):56-72.
2. Baloyiannis I, Kouritas VK, Karagiannis K, Spyridakis M, Efthimiou M. Isolated right diaphragmatic rupture following blunt trauma. *Gen Thorac Cardiovasc Surg.* 2011 Nov. 59(11):760-2.
3. Melo EL, de Menezes MR, Cerri GG. Abdominal gunshot wounds: multi-detector-row CT findings compared with laparotomy-a prospective study. *Emerg Radiol.* 2011 Dec 2.
4. Berardoni NE, Kopelman TR, O'Neill PJ, August DL, Vail SJ, Pieri PG, et al. Use of computed tomography in the initial evaluation of anterior abdominal stab wounds. *Am J Surg.* 2011 Oct 27.
5. Rizoli SB, Brenneman FD, Boulanger BR, Maggisano R. Blunt diaphragmatic and thoracic aortic rupture: an emerging injury complex. *Ann Thorac Surg.* 1994 Nov. 58(5):1404-8.
6. Grimes OF. Traumatic injuries of the diaphragm. *Diaphragmatic hernia.* *Am J Surg.* 1974 Aug. 128(2):175-81.
7. Dreizin D, Bergquist PJ, Taner AT, Bodanapally UK, Tirada N, Munera F. Evolving concepts in MDCT diagnosis of penetrating diaphragmatic injury. *Emerg Radiol.* 2015 Apr. 22(2):149-56.

8. Patlas MN, Leung VA, Romano L, Gagliardi N, Ponticello G, Scaglione M. Diaphragmatic injuries: why do we struggle to detect them?. *Radiol Med*. 2015 Jan. 120 (1):12-20.
9. Leung VA, Patlas MN, Reid S, Coates A, Nicolaou S. Imaging of Traumatic Diaphragmatic Rupture: Evaluation of Diagnostic Accuracy at a Level 1 Trauma Centre. *Can Assoc Radiol J*. 2015 Jun 19.
10. Athanassiadi K, Kalavrouziotis G, Athanassiou M, et al. Blunt diaphragmatic rupture. *Eur J Cardiothorac Surg*. 1999 Apr. 15(4):469-74.
11. Barbiera F, Nicastro N, Finazzo M, et al. The role of MRI in traumatic rupture of the diaphragm. Our experience in three cases and review of the literature. *Radiol Med (Torino)*. 2003 Mar. 105(3):188-94.
12. Barsness KA, Bensard DD, Ciesla D, et al. Blunt diaphragmatic rupture in children. *J Trauma*. 2004 Jan. 56(1):80-2.
13. Bergqvist D, Dahlgren S, Hedelin H. Rupture of the diaphragm in patients wearing seatbelts. *J Trauma*. 1978 Nov. 18(11):781-3.
14. Bocchini G, Guida F, Sica G, Codella U, Scaglione M. Diaphragmatic injuries after blunt trauma: are they still a challenge? Reviewing CT findings and integrated imaging. *Emerg Radiol*. 2012 Jun. 19(3):225-35.
15. Boulanger BR, Milzman DP, Rosati C, Rodriguez A. A comparison of right and left blunt traumatic diaphragmatic rupture. *J Trauma*. 1993 Aug. 35(2):255-60.
16. Boulanger BR, Mirvis SE, Rodriguez A. Magnetic resonance imaging in traumatic diaphragmatic rupture: case reports. *J Trauma*. 1992 Jan. 32(1):89-93.
17. Guth AA, Pachter HL, Kim U. Pitfalls in the diagnosis of blunt diaphragmatic injury. *Am J Surg*. 1995 Jul. 170(1):5-9.
18. Hanna WC, Ferri LE, Fata P, Razek T, Mulder DS. The current status of traumatic diaphragmatic injury: lessons learned from 105 patients over 13 years. *Ann Thorac Surg*. 2008 Mar. 85(3):1044-8.
19. Jarrett F, Bernhardt LC. Right-sided diaphragmatic injury: rarity or overlooked diagnosis?. *Arch Surg*. 1978 Jun. 113(6):737-9.
20. Leaman PL. Rupture of the right hemidiaphragm due to blunt trauma. *Ann Emerg Med*. 1983 Jun. 12(6):351-7.
21. Leppaniemi A, Haapiainen R. Occult diaphragmatic injuries caused by stab wounds. *J Trauma*. 2003 Oct. 55(4):646-50.
22. Matsevych OY. Blunt diaphragmatic rupture: four year's experience. *Hernia*. 2008 Feb. 12(1):73-8.
23. Mihos P, Potaris K, Gakidis J, et al. Traumatic rupture of the diaphragm: experience with 65 patients. *Injury*. 2003 Mar. 34(3):169-72.
24. Nau T, Seitz H, Mousavi M, Vecsei V. The diagnostic dilemma of traumatic rupture of the diaphragm. *Surg Endosc*. 2001 Sep. 15(9):992-6.
25. Patselas TN, Gallagher EG. The diagnostic dilemma of diaphragm injury. *Am Surg*. 2002 Jul. 68(7):633-9.
26. Powell BS, Magnotti LJ, Schroepel TJ, Finnell CW, Savage SA, Fischer PE, et al. Diagnostic laparoscopy for the evaluation of occult diaphragmatic injury following penetrating thoracoabdominal trauma. *Injury*. 2008 May. 39(5):530-4.

**How to cite this article:** Chahal MS, Agrawal M, Singh H, Jain A, Prasad R, Mishra G. Presentations and Outcomes of Diaphragmatic Injuries – A 15 Year Experience. *Ann. Int. Med. Den. Res*. 2017; 3(2):SG08-SG13.

**Source of Support:** Nil, **Conflict of Interest:** None declared