

A Case Report on Perforated Meckel's Diverticulitis Mimicking Acute Appendicitis.

Jayant Kumar Biswal¹, Jino Sebastian², Tanmaya Mahapatra², Jitendra Kumar Soren²

¹Associate Professor, Department of General Surgery, S.C.B Medical College and Hospital Cuttack, Odisha, India.

²Junior Resident, Department of General Surgery, S.C.B Medical College and Hospital Cuttack, Odisha, India.

Received: April 2017

Accepted: May 2017

Copyright: © the author(s), publisher. It is an open-access article distributed under the terms of the Creative Commons Attribution Non-Commercial License, which permits unrestricted non-commercial use, distribution, and reproduction in any medium, provided the original work is properly cited.

ABSTRACT

Meckel's diverticulum, the most common congenital anomaly of small bowel although usually silent, can cause complications like intestinal obstruction, bleeding, diverticulitis, perforation etc. We report a case, which presented with acute onset of abdominal pain which was clinically and sonographically diagnosed as acute appendicitis. Abdomen was explored with a midline incision, as X-ray abdomen showed free gas under diaphragm and a perforated Meckel's diverticulum was found which was managed by resection of the same with adjacent ileum and end to end anastomosis. For preoperative diagnosis of Meckel's diverticulitis with perforation clinical suspicion should be high, especially when diffuse peritonitis and gas under right dome of diaphragm is seen in X - ray of abdomen.

Keywords: Congenital anomaly, Meckel's diverticulum, Perforation, Peritonitis.

INTRODUCTION

In 1598 a German surgeon, Wilhem Fabricus Hildanus first described Meckel's diverticulum (MD) but it was described in detail by Hohann Friedrich Meckel in 1808, hence it was named after him.^[1,2] It is the most common congenital anomaly of the small intestine, which is the remnant of vitelline (omphalomesenteric) duct and is seen in approximately 2% of the population. Although presence of MD can result in complications like bleeding, obstruction, diverticulitis etc, they are rare and most patients remain asymptomatic for life.^[3] Also perforation of a Meckel's diverticulum which is a rare complication may mimic acute appendicitis and present as an acute abdomen.^[4] Cause of perforation is usually presence of gastric mucosa but rarely foreign bodies, fecoliths and trauma.^[5,6]

Name & Address of Corresponding Author

Dr. Jino Sebastian
Junior Resident,
Department of General Surgery,
S.C.B Medical College and Hospital Cuttack, Odisha, India.

Our patient presented with acute abdomen and was diagnosed clinically and sonographically as acute appendicitis and by X-ray as hollow viscus perforation. On laparotomy it was found to be a perforated Meckel's diverticulum. Complications of MD can be even life threatening as in our case. Since clinical features of this condition is overlapping with a spectrum of other similar abdominal conditions, a proper preoperative diagnosis is challenging.

CASE REPORT

A 52 year old man presented with gradually increasing pain in central and lower abdomen for last 5 days with history of distension of abdomen and absolute constipation for the same period of time. The pain aggravated during the last 24 hours for which he was admitted to the hospital. On examination he was febrile (102 degree F) with pulse rate of 120 per minute and BP 128/90 mmHg. All hematological parameters (except leucocytosis) were within normal limits. Abdominal examination showed distension of abdomen with rebound tenderness and rigidity all over. X-ray of abdomen in erect posture showed free gas under right dome of diaphragm [Figure 1]. Ultrasonography of the abdomen revealed presence of an inflamed appendix in the right iliac fossa [Figure 2]. A provisional diagnosis of perforated appendicitis was made with gas under diaphragm as an unusual finding. After resuscitation of the patient abdomen was explored by midline incision. Peritoneal cavity contained mild to moderate collection of puss and peritoneal fluid with presence of a perforated Meckel's diverticulum with a narrow base and length of 5 cm in the right lower abdomen and the appendix was found to be normal [Figure 3]. The adjacent ileum with the perforated Meckel's was resected and end to end anastomosis was done. The specimen was sent for HP study. And report showed presence of all layers of intestine with inflammatory cell infiltrate, focal ulceration of mucosa, congested blood vessels, necrosis at the site of perforation and absence of any ectopic mucosae.

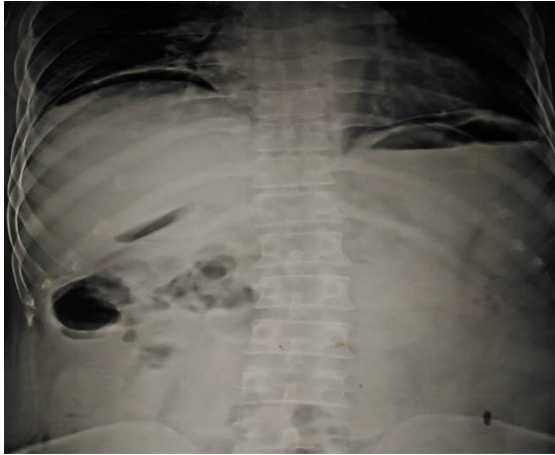


Figure 1: Erect X-ray abdomen showing free gas under right dome of diaphragm.

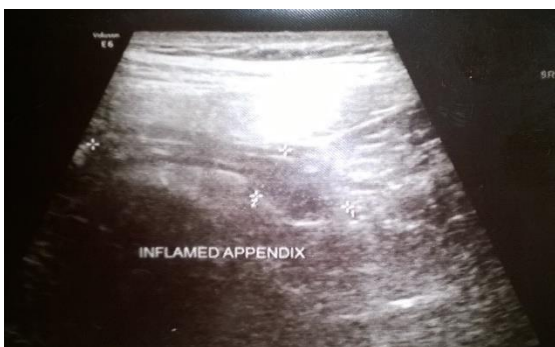

Figure 2: Ultrasonogram showing features suggestive of appendicitis.

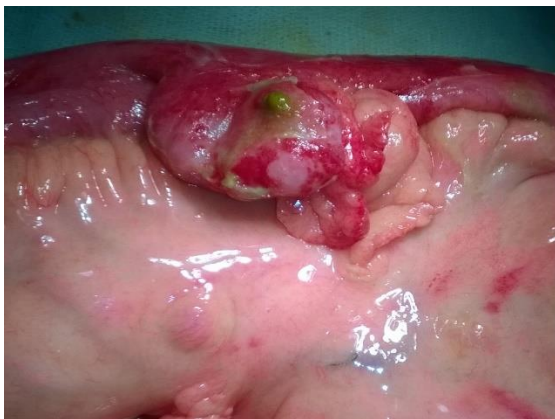

Figure 3: Inflamed and perforated Meckel's diverticulum.

DISCUSSION

Most common presentation of MD in adults is intestinal obstruction and in young patients it is haemorrhage.^[7,8] MD if present can also lead to its inflammation, perforation, intussusception and volvulus. 60% of Meckel's diverticula contain heterotopic mucosa, of which over 60% consist of gastric mucosa and others like pancreatic mucosa (5%) and less commonly colonic mucosa, endometriosis, hepatobiliary tissue may also be present rarely.^[9-11] Presence of these is the cause of

complications like haemorrhage, chronic peptic ulceration and perforation in many cases. Interestingly, our patient's Meckel's diverticulum did not contain ectopic gastric or pancreatic mucosa on histologic examination.

As it is known that risk of perforation is high in MD with narrow base and length more than 2cm,^[12] in our case also same is proved again. Other rare causes of perforation of MD are Littre's hernia and leiomyosarcoma.^[13]

Plain radiographs are although not very useful, it can almost rule out appendicitis if gas under diaphragm is present, as it is very rare in appendicular perforation. The ultrasonographic features of M.D are variable especially if complications are present and can be easily confused with appendicitis or duplication cyst of ileum.^[14,15] From various data it is also understood that a conventional C.T scan also cannot diagnose this condition confidently, as MD appears as a physiological bowel loop in it.^[14,15] Technetium 99 pertechnetate scintigraphy is the investigation of choice in paediatric patients with gastrointestinal bleeding and suspected Meckel's diverticulum. As incidence of presence of heterotopic gastric mucosa (HGM) is low in adults, its sensitivity and accuracy reduces from 85% and 95% (in paediatric population) to 63% and 46% in adults respectively.^[16]

Mortality rate from MD related complications is around 5% and is due to delay in diagnosis. So several newer diagnostic modalities are developed such as double balloon enteroscopy, capsule endoscopy, multidetector CT, CT enterography, CT enteroclysis, MR enteroclysis and diagnostic laparoscopy.

Double balloon enteroscopy and capsule endoscopy are used to detect occult bleeding from gastrointestinal tract and the same due to MD is more common in paediatric population. Multidetector CT with two-dimensional array of detector elements replaces the linear array of detector elements used in typical conventional and helical CT. A blind ending pouch with fluid collection and mural thickness is the typical appearance of Meckel's diverticulitis in Multidetector CT. Presence of extra luminal air or particulate materials is suggestive of perforation.^[16,17] Both CT enterography (CT with oral neutral contrast) and CT enteroclysis (CT with small bowel contrast enema), are new and useful modalities which can enhance the mucosa and bowel lumen in detail and helps in localising bleeding and detecting perforation. MR enterography, eventhough more costly and not much helpful than CT enterography in detecting complications associated with MD, can be ordered for those in which radiation exposure is contraindicated. Diagnostic laparoscopy is very useful when above investigations gives inconclusive results and a suspicion of MD still remains and if present can be

removed laparoscopically either by diverticulectomy or segmental resection. It is very useful in case of perforation but in case of bleeding, because of the inability to palpate the base and adjacent ileum to check for the presence of HGM, its use is debated. If bleeding is present, base is inflamed or perforated, segmental resection and end to end anastomosis is the preferred choice of surgery as bleeding point is not exactly in the diverticulum but usually in the adjacent ileum. But if the tip is perforated diverticulectomy is sufficient. Also for long diverticulae with narrow base (in which HGM is usually in tip), diverticulectomy and for short one's with broad base segmental resection is recommended. This is because in the later ones there is more incidence of HGM in the base and of haemorrhage.^[18] In case of incidentally found MD diverticulectomy is recommended as studies have shown that incidence of complications from surgery is less than that from left alone MD.^[19]

CONCLUSION

From our case following conclusions can be obtained:

1. Features of perforated meckels diverticulitis will closely mimic that of acute appendicitis and is not possible to differentiate both clinically.
2. USG findings can also confuse Meckel's diverticulitis with acute appendicitis and it is difficult for even an experienced sonologist to differentiate one from other.
3. Even when both clinical and sonological features are suggesting acute appendicitis, presence of gas under diaphragm in X-ray will make the diagnosis more in favour of perforated meckel's diverticulitis.
4. In the presence of gas under diaphragm in X-ray with sonographic findings of acute appendicitis it is better to explore the abdomen by a midline incision than by a gridiron incision.
5. Perforation of meckels diverticulum can occur even without the presence of heterotopic gastric mucosa.

Acknowledgment

We thank Dr. R.N. Mallick, our pathologist for his co-operation.

REFERENCES

1. Edmonson JM. Johann Friedrich Meckel the younger. Meckel's diverticulum. *Gastrointest Endosc.* 2001;54:19A-20A
2. Ajaz A. Malik, Shams-ul-Bari, Khurshid A. Wani, Abdul R. Khaja. Meckel's diverticulum – Revisited. *Saudi J Gastro.* 2010;16(1):3-7
3. Park JJ, Wolff BG, Tollefson MK, Walsh EE, Larson DR. Meckel diverticulum: the Mayo Clinic experience with 1476 patients (1950-2002). *Ann Surg.* 2005;241(3):529-533.

4. Bani-Hani KE, Shatnawi NJ. Meckel's diverticulum: comparison of incidental and symptomatic cases. *World J Surg.* 2004;28(9):917-920.
5. Kazemi K, Jalaiean H, Fattahi MR, Hosseini SV, Shafiee M, Roshan N. Ruptured Meckel's mesodiverticulum and Meckel's diverticulum following blunt abdominal trauma. *Med Princ Pract.* 2008;17:161-163.
6. Greenspan L, Abramovitch A, Tomarken J, Cohen Z. Perforation of a Meckel's diverticulum by a foreign body. *Can J Surg.* 1983;26(2):184-185
7. Sharma RK, Jain VK. Emergency surgery for Meckel's diverticulum. *World J Emerg Surg.* 2008;3:27
8. Rutherford RB, Akers DR. Meckel diverticulum: a review of 148 pediatric patients with specific reference to the pattern of bleeding and to mesodiverticular vascular bands. *Surgery* 1966;59:618-626
9. Dimitriou I, Evaggelou N, Tavaki E, Chatzitheoklytos E. Perforation of Meckel's diverticulum by a fish bone presenting as acute appendicitis: a case report. *J Med Case Rep.* 2013oct;2(7):231.
10. Sharma RK, Jain VK. Emergency surgery for Meckel's diverticulum. *World J Emerg Surg.* 2008Aug;13(3):27.
11. Dumper J, Mackenzie S, Mitchell P, Sutherland F, Quan ML, Mew D. Complications of Meckel's diverticula in adults. *Can J Surg.* 2006 Oct;49(5):353-7.
12. Yinlu Ding, Yong Zhou, Zhipeng Ji et al. Laparoscopic Management of Perforated Meckel's Diverticulum in Adults. *J Med Sci.* 2012;9(3):243-247.
13. Hager M, Maier H, Eberwein M. et al. Perforated Meckel's diverticulum presenting as a gastrointestinal stromal tumor: a case report. *J Gastrointest Surg.* 2005;9(6):809-811
14. Thurley PD, Halliday KE, Somers JM, Al-Daraji WI, Ilyas M, Broderick NJ. Radiological features of Meckel's diverticulum and its complications. *Clinical Radiology.* 2009;64(2):109-18
15. Baldisserotto M, Maffazzoni DR, Dora MD. Sonographic findings of Meckel's diverticulitis in children. *AJR Am J Roentgenol.* 2003;180:425-8
16. Levy AD, Hobbs CM. From the archives of the AFIP. Meckel diverticulum: radiologic features with pathologic correlation. *Radiographics.* 2004;24(2):565-587
17. Elsayes KM, Menias CO, Harvin HJ, Francis IR. Imaging manifestations of Meckel's diverticulum. *Am J Roentgenol.* 2007;189(1):81-88
18. Feller AA, Movson J, Shah SA. Meckel diverticulum: a geriatric disease masquerading as common gastrointestinal tract disorders. *Arch Intern Med.* 2003;163(17):2093-2096
19. Cullen JJ, Kelly KA, Moir CR, et al. Surgical management of Meckel's diverticulum. An epidemiologic, population-based study. *Ann Surg.* 1994;220(4):564-568.

How to cite this article: Biswal JK, Sebastian J, Mahapatra T, Soren JK. A Case Report on Perforated Meckel's Diverticulitis Mimicking Acute Appendicitis. *Ann. Int. Med. Den. Res.* 2017; 3(4):SG08-SG10.

Source of Support: Nil. **Conflict of Interest:** None declared