

# A Misdiagnosed Case of Anal Canal Malignant Melanoma: A Case Report.

Nandkishore Jaiswal<sup>1</sup>, Aniket B Payagude<sup>2</sup>

<sup>1</sup>Associate Professor, Department of Surgery, Government Medical College and Hospital, Nagpur.

<sup>2</sup>Post Graduate Student, Department of Surgery, Government Medical College and Hospital, Nagpur.

Received: December 2016

Accepted: December 2016

**Copyright:** © the author(s), publisher. It is an open-access article distributed under the terms of the Creative Commons Attribution Non-Commercial License, which permits unrestricted non-commercial use, distribution, and reproduction in any medium, provided the original work is properly cited.

## ABSTRACT

Anal canal malignant melanoma is an uncommon malignancy. It is a highly aggressive tumor that tends to spread early in the course and present with distant metastasis. Due to the rarity of the condition, treatment is yet to be standardized. We report a case of a 47-y ear-old male patient who presented with the history of mass coming out of anus for 6 months, which was misdiagnosed as a case of hemorrhoids. Abdominoperineal resection was done based on tissue biopsy which suggested it to be a primary anal canal malignant melanoma. The diagnosis was later confirmed by histopathological and immunohistochemistry studies, which was strongly positive for HMB 45 AND Melan-A.

**Keywords:** Anal canal malignant melanoma, Abdominoperineal resection, HMB 45, Immunohistochemistry, Melan-A.

## INTRODUCTION

Primary Anorectal malignant melanoma is a very rare tumor with high malignant potential that tends to spread early with poor overall outcome.<sup>[1]</sup> It accounts for 1% of all melanomas and 0.5- 2% of all melanomas arise in the anorectal region.<sup>[2, 3]</sup> After skin and retina, anal canal is the third most frequent site where melanomas are found.<sup>[4]</sup> It typically presents in fifth or sixth decades of life, with female preponderance.<sup>[5]</sup> To the best of our knowledge, till date only 640 cases have been reported in the literature.<sup>[6]</sup> A non-specific presenting symptom of anal melanoma makes early diagnosis difficult. Early diagnosis is crucial so that treatment can be standardized.

### Name & Address of Corresponding Author

Dr. Aniket B Payagude  
Post Graduate Student,  
Department of Surgery,  
Government Medical College and Hospital, Nagpur.

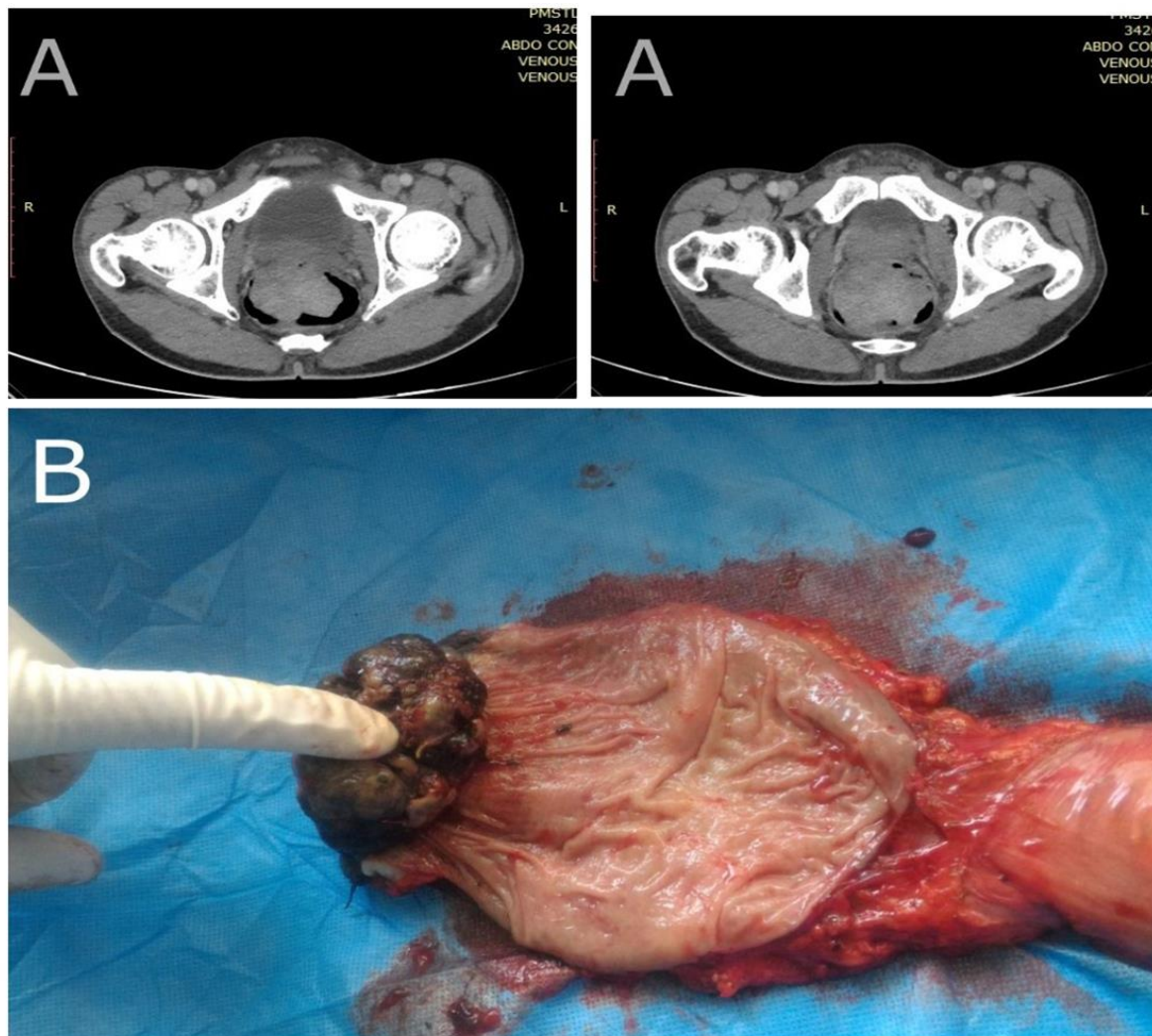
## CASE REPORT

A 47-year-old male patient presented with a complaint of passing blood in stools associated with mass coming out of anus since 6 months. The patient was in follow up since then misdiagnosed as hemorrhoids by a general practitioner. The patient was then referred to us for further management. Past medical and personal history of the patient was insignificant. On rectal examination, there was a large polypoidal pedunculated friable mass present on the anterior surface of anal canal approx. 1 cm

from the anal verge, which was resembling thrombosed hemorrhoids. The biopsy was taken as mass was suspicious for malignancy. Biopsy report suggested it to be a primary malignant melanoma. CECT abdomen [Figure 1A.] demonstrated heterogeneously enhancing intraluminal polypoidal lesion of approx. size 5.7×5×4.1 cm, the length of involvement was approx. 4 cm, fat planes were maintained with surrounding structure with perirectal fat stranding with few necrotic inguinal lymph nodes and no distant metastasis. The patient was planned for surgical intervention. Accordingly, the patient was evaluated with complete blood count, renal function test, liver function test, chest radiograph, echocardiography, pulmonary function test for major surgery. Abdominoperineal resection was done with a permanent colostomy. Gross examination of the specimen showed a black mass of size 5×5×5 cm with an irregular surface which was solid and friable, 1.5 cm from anal verge [Figure 1B]. On microscopic examination [Figure 2A-B], tumor cells were round, polygonal and spindle-shaped with abundant cytoplasm and prominent nucleoli containing coarse black pigment suggestive of malignant melanoma (section from the skin with tumor mass shows epidermis with tumor infiltration) with serosal and lymph node involvement. The diagnosis was further confirmed by immunohistochemistry, strongly positive for Melan-A and HMB 45 [Figure 2C-D]. The patient recovered uneventfully from the surgery and then was managed post-operatively with radiotherapy. Follow up CECT abdomen was done after six months which demonstrated hypodense lesion in right lobe of liver

with features suggestive of metastasis. The patient is

now on chemotherapy.



**Figure 1:** CECT ABDOMEN: Heterogeneously enhancing intraluminal polypoid lesion of approx. size 5.7×5×4.1 cm, the length of involvement was approx. 4 cm (A). Gross examination: showed a black mass of size 5×5×5 cm with an irregular surface which was solid and friable (B).

## DISCUSSION

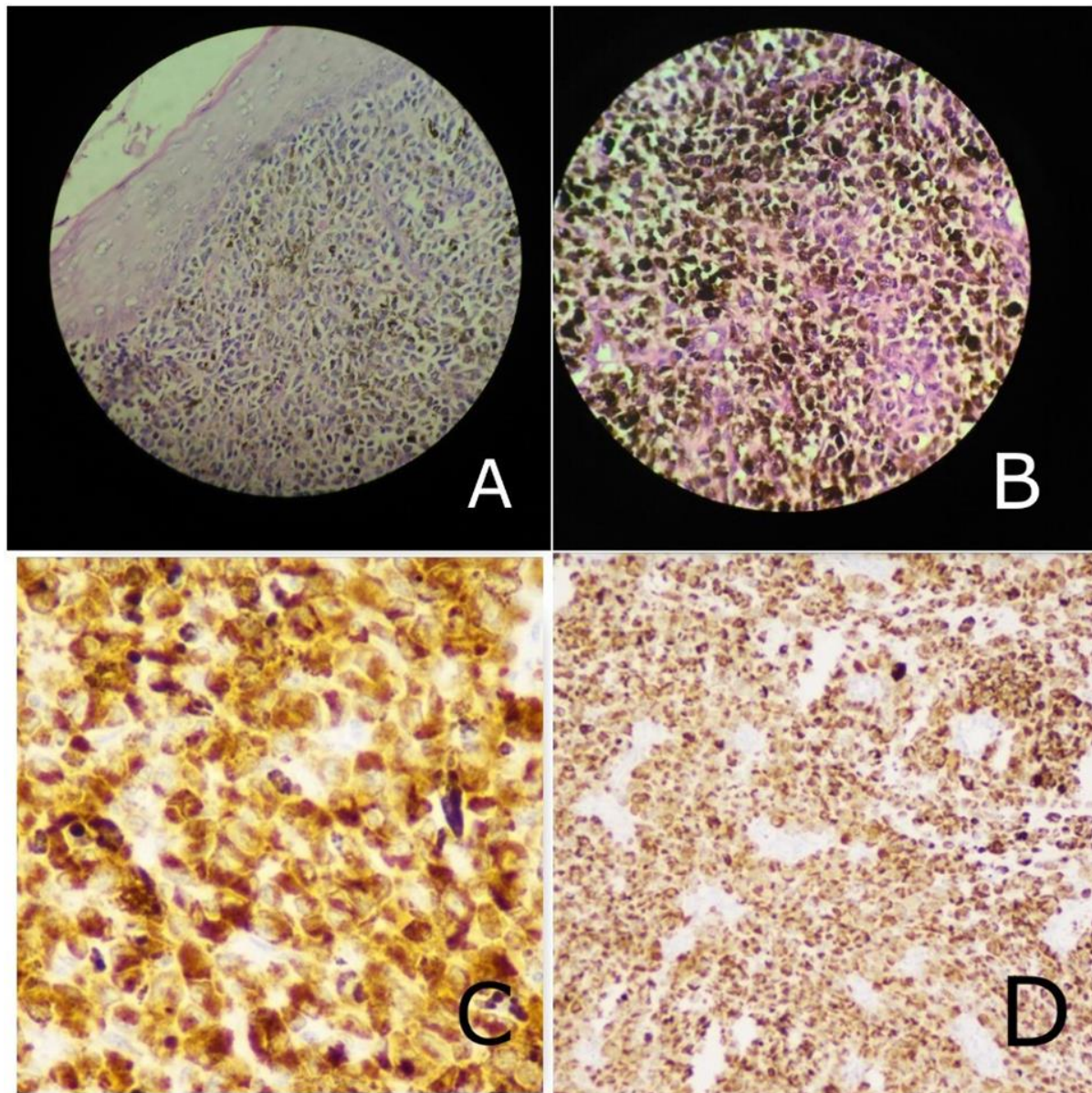
Anal canal malignant melanoma is an uncommon malignancy of gastrointestinal tract. It was first reported by Moore DW in 1857<sup>[7]</sup>, since then to best of our knowledge only 640 cases of anorectal melanomas have been reported in the literature of which 375 cases were anal melanoma.<sup>[6]</sup> Due to its relative rarity, it is difficult to determine the exact Incidence of the disease<sup>[2]</sup>, Incidence rate of anorectal melanoma is about 2.7 per million per year in the United States.<sup>[8]</sup> It accounts for 1% of all melanomas and 0.5- 2% of all melanomas arise in the anorectal region.<sup>[2, 3]</sup>

Anorectal melanomas arise from the melanocytes found in the intestinal mucosa below the dentate line extending proximally into the rectum, hence also identified as primary anorectal melanomas.<sup>[9,10]</sup> Unlike cutaneous melanoma, there is no risk factor for the development of mucosal melanoma.<sup>[2]</sup>

Anorectal melanoma patient usually presents with per rectal bleeding, rectal pain, tenesmus, mass coming out of anus and change in bowel habit's.<sup>[2]</sup> Presenting symptoms of anal canal malignant melanoma is non-specific and most of the cases are initially diagnosed and managed as benign conditions, more commonly being internal hemorrhoids. Patients of anal canal malignant melanoma usually present in the later stage of the disease.<sup>[11]</sup> We hereby report a case of an adult male who presented with bleeding per rectum with an anal mass protruding out and was managed as internal hemorrhoid, which later turned out to be malignant melanoma on tissue biopsy. Approximately 61% of the patients already have lymph node involvement or distant at the time of diagnosis.<sup>[12]</sup> Our patient was free of distant metastasis at the time of diagnosis, but lymph nodes were positive for the malignant cell in pathological specimen. This is important as overall prognosis for

anorectal malignant melanoma is poor with overall 5 year survival rate of less than 20%<sup>[13]</sup>, the five-year survival rate depends on the extent of the disease and

is 32%, 17% and 0% for local, regional and, distant disease, respectively.<sup>[1]</sup>



**Figure 2:** Microscopy examination: Round, polygonal and spindle-shaped tumor cells with abundant cytoplasm and prominent nucleoli containing coarse black pigment (A & B) Immunohistochemistry findings: (C) HMB-45 and (D) Melan-A.

On microscopic examination presence of melanin in the tumor cell and on immunohistochemistry expression of HMB 45 and Melan-A are strongly suggestive of melanoma<sup>[14]</sup> additionally anal melanoma will stain for S-100, Vimentin, microphthalmia-associated transcription factor proteins, and, Carcinoembryonic antigen.<sup>[12]</sup>

Treatment of anorectal melanoma is controversial.<sup>[15]</sup> Abdominoperineal resection [APR] with or without inguinal lymph node dissection OR wide local excision [WLE] are the treatment options available.<sup>[3]</sup> But, due to the relative rarity of the disease and lack of randomized clinical trials consensus on preferred surgical approach has not

been reached.<sup>[5]</sup> The difference in Five-year survival rate between patients undergoing APR versus WLE (17% & 19%, respectively) is not significant, Iddings et al.<sup>[16,17]</sup> As overall prognosis of anorectal melanoma is poor, the surgical approach is to be individualized. The postoperative role of adjuvant chemo-radiotherapy has not been well established, but there are studies to support the role of radiotherapy for local control<sup>[3, 18]</sup> and, chemotherapy in the management of metastatic disease.<sup>[3,19]</sup> Our patients received postoperative radiotherapy after which patient was followed up for 6 months, Repeat CECT abdomen was done which suggested liver

metastasis and patient is now being advised chemotherapy.

## CONCLUSION

Primary Anal canal malignant melanoma is rare and has high malignant potential. Although a rare presentation, diagnosis of anorectal melanoma should be one of the differential diagnoses in the management of benign conditions, particularly hemorrhoids. As there is no consensus regarding management of Anorectal melanoma and its management should be individualized.

## REFERENCES

- Podnos YD, Tsai NC, Smith D, Ellenhorn JD. Factors affecting survival in patients with anal melanoma. *Am. Surg.* 2006; 72: 917-920.
- Singer M, Mutch MG: Anal melanoma. *Clin Colon Rectal Surg* 2006; 19:78-87.
- Khan M, Butcher N, Elhassan A, et al. Primary Anorectal melanoma. *Case reports in Oncology*, 2014; 7(1) 164-170.
- Bell F, Gallino GF, Lo Vullo S, Marriani L, Poiasina E, Leo E. melanoma of the anorectal region. The experience of the National Cancer Institute of Milano. *EJSO*. 2009; 35: 757-62.
- Van Schaik P, Ernst M, Meijer H, Bosscha K. Melanoma of the rectum: A rare entity. *World Journal of Gastroenterology: WJG*. 2008; 14(10): 1633-1635.
- Haiyan Chen, MM, Yibo Cai, Yue Liu, MM, Jinjie He, MM, Yeting Hu, MM, Qian Xiao, MD Wangxiong Hu, PhD, and Kefeng Ding, MD. Incidence, Surgical Treatment, and Prognosis of Anorectal Melanoma from 1973 to 2011. A Population – Based SEER Analysis. Volume 95, Number 7, February 2016.
- Moore WD. Recurrent melanosis of the rectum after the previous removal from the verge of the anus in a managed 65. *Lancet*. 1857; 1:290-4.
- Coté TR, Robin LH. Primary melanomas of the esophagus and anorectum: epidemiologic comparison with melanoma of the skin. *Melanoma Res*. 2009; 19:58-60.
- Morson BC, Volkstadt H: Malignant melanoma of the anal canal. *J Clin. Pathology* 1963; 16:126-132.
- Nicholson AG, Cox PM, Marks CG, Cook MG. Primary malignant melanoma of the rectum. *Histopathology*. 1993; 22: 261-4.
- Mulder SP, Veldsman JJ: Malignant melanoma of the anal canal. A case report and review. *S Afr Med J* 67(3): 101, 1985
- Limketkai BN, Chandrasekhara V, Milligan F. Primary anorectal amelanotic melanoma presenting as internal hemorrhoids. *Gastroenterology and Hepatology*. 2009 Jul; 5(7):516-518.
- Ragnarsson-Olding, B.K., Nilsson, P.J., Olding, L.B., Nikson, B.R. Primary ano-rectal malignant melanomas within a population-based national patient series in Sweden during 40 years. *Acta Oncol*. 2009; 48:125–131.
- Buissin D, Sterle A, Schmiegelow P, Wassenberg D, Ambe PC. Primary anorectal malignant melanoma: a rare but aggressive tumor: report of a case. *World Journal of Surgical Oncology*. 2015; 13:12.
- Gavriilidis P, Moula E, Nikolaidou A. Primary rectal malignant melanoma—case report. *Hippokratia*. 2013; 17:380–1.
- Iddings DM, Fleisig AJ, Chen SL, Faries MB, Morton DL. Practice Patterns and Outcomes for Anorectal Melanoma in the United States; is more extensive surgical resection beneficial in all patients? *Annals of surgical oncology*. 2010; 17(1):40-44.
- Carcoforo P, Raiji MT, Palini GM, et al. Primary anorectal melanoma: an update. *J Cancer*. 2012; 3: 449–53.
- Kelly P, Zagars GK, Cormier JN, et al. Sphincter-sparing local excision and hypofractionated radiation therapy for anorectal melanoma: a 20-year experience. *Cancer*. 2011; 117:4747–55.
- Kim KB, Legha SS, Gonzalez R, et al. A randomized phase III trial of biochemotherapy versus interferon-alpha-2b for adjuvant therapy in patients at high risk for melanoma recurrence. *Melanoma Res*. 2009; 19: 42–49.

**How to cite this article:** Jaiswal NK, Payagude AB. A Misdiagnosed Case of Anal Canal Malignant Melanoma: A Case Report. *Ann. Int. Med. Den. Res.* 2017; 3(1):SG04-SG07.

**Source of Support:** Nil, **Conflict of Interest:** None declared