

# Evaluation and Management of Post-Operative Enterocutaneous Fistula.

Sudhir Kumar Mohanty<sup>1</sup>, Ramakanta Mohanty<sup>2</sup>

<sup>1</sup>Associate Professor, Department of General Surgery, SCB Medical College, Cuttack, Odisha, India.

<sup>2</sup>Assistant Professor, Department of General Surgery, SCB Medical College, Cuttack, Odisha, India.

Received: April 2017

Accepted: April 2017

**Copyright:** © the author(s), publisher. It is an open-access article distributed under the terms of the Creative Commons Attribution Non-Commercial License, which permits unrestricted non-commercial use, distribution, and reproduction in any medium, provided the original work is properly cited.

## ABSTRACT

**Background:** An enterocutaneous fistula is the abnormal communication between two epithelialized surfaces, one of which is a hollow organ. The discharge of intestinal content into the skin constitutes major nursing challenge. The most important complications include infection and sepsis, electrolyte imbalances and malnutrition, which when not managed properly will lead to grave outcome. Aims: To evaluate the causative factors, the various modes of management and the outcome of such intervention. **Methods:** Retrospective study of the patients admitted and treated for enterocutaneous fistula due to operative causes were evaluated in Dept of General Surgery S.C.B. Medical College and Hospital, Cuttack from 2014 to 2016. **Results:** Enterocutaneous fistula frequently follow emergency surgery on gastrointestinal tract, particularly the ileum, duodenum and colon, usually occurring around the 7th postoperative day and most end in spontaneous closure with conservative therapy. Surgery should be restricted to treatment of specially indicated patients like prolonged continuous fistulous discharge, abdominal wound dehiscence and deep seated intra peritoneal abscess. **Conclusions:** The total management of enterocutaneous fistula involves skilled nutritional support, stoma therapy, elimination of sepsis and finally a carefully timed, well-judged and well carried out surgery which will result in favourable outcome in patients with this dreaded complication.

**Keywords:** Enterocutaneous, Fistula, Evaluation.

## INTRODUCTION

The enterocutaneous fistula is an abnormal communication between intestinal tract and the skin. It is the abnormal communication between two epithelialized surfaces, one of which is a hollow organ (Sabiston 18edn).<sup>[1]</sup> It depresses the surgeon's as well as patient's psychology. The discharge of intestinal content into the skin constitutes major nursing challenge. Passage of gastrointestinal contents through the fistula can lead to three major problems:

- Portion of gut below the fistula is bypassed and preventing from carrying out normal absorptive functions and thus resulting in nutritional disorders.
- Losses of gastrointestinal secretions lead to water, electrolyte and acid base imbalance.
- Fistulous tract may not effectively walled off from the surrounding structures which cause escape of enteric contents to normal sterile areas of peritoneal cavity and lead to serious septic complications.<sup>[2-4]</sup>

These three factors determine the morbidity and mortality in enterocutaneous fistula. If skin is not properly protected, severe excoriations will occur and subsequent stoma management will be more

difficult. The total management of enterocutaneous fistulae involves skilled nutritional support, stoma therapy, elimination of sepsis and finally a carefully timed, well-judged and well carried out surgery.<sup>[5-7]</sup>

### Name & Address of Corresponding Author

Dr. Sudhir Kumar Mohanty.  
Associate Professor  
Department of Surgery  
SCB Medical College, Cuttack Odisha, India.

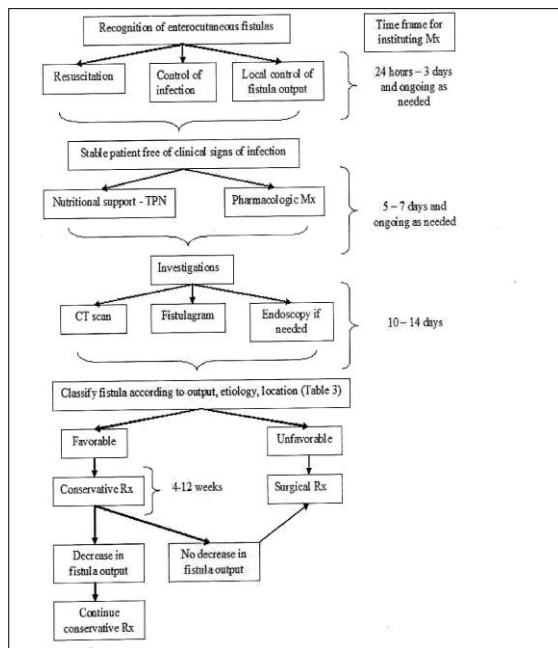
Our interest in this subject has grown out of the conviction that the patients suffering from this condition, on one side are being practically given up as lost and since majority come from poor areas, it is a pitiable sight to witness. On other hand not much work seems to have been made on this problem in our country and that too in this state as is apparent from the paucity of reports in our literature. The most important complications include infection and sepsis, electrolyte imbalances and malnutrition, which when not managed properly will lead to grave outcome.

## MATERIALS AND METHODS

The study on "Evaluation and management of enterocutaneous fistula" was conducted in the

department of surgery in S.C.B Medical College, Cuttack, during the period from November 2014 to November 2016. Thirty cases of enterocutaneous fistula occurring as postoperative complication among the patients admitted and operated in our hospital for various gastrointestinal conditions as emergency or routine surgery and also referred cases from other centres were the subjects of the study.

The diagnosis was based on comprehensive clinical history of the cases, thorough physical examination, routine laboratory investigations, and radiological examination, and endoscopic studies where needed. [Figure 1] 8 Operative findings were carefully noted. If enterocutaneous fistula developed during post operative follow up were watched carefully and treated conservatively or by surgery as required. Utmost attention was given to management of electrolyte imbalances, control of sepsis, nutritional resuscitation either with total parenteral nutrition or enteral nutrition and finally the care of the cutaneous stoma.



## RESULTS

During this period of study 30 cases of enterocutaneous fistulae were retrospectively evaluated, who were admitted and operated for various gastrointestinal conditions as emergency or routine cases and also patients referred from other centres for such complication occurred. [Table 1-3] The maximum number of cases (36.7%) that is 11 out of 30 belonged to 4th decade and minimum was in between 40 to 60 years (6.7%). The youngest in the series was 15 years old and the eldest was aged 79 years. 80% cases were male and 20% were female. The ratio between male and female was 4:1.

**Table 1: Etiologies for Which Operation Were Performed.**

Primary disease of the gastrointestinal tract	Number of cases	Percentage
Peptic perforation	5	16.7
Intestinal obstruction	9	30
Acute appendicitis	2	6.7
Abdominal trauma	14	6.7

**Table 2: Incidence of Routine and Emergency Operations Causing Enterocutaneous Fistula.**

Type of operation	Number of Cases	Percentage
Routine	4	13.3
Emergency	26	86.7
Total	30	100

**Table 3: Site of Enterocutaneous Fistula.**

Site of fistula	No. of cases	Percentage
Stomach	1	3.3
Duodenum	6	20
Jejunum	7	23.3
Ileum	8	26.7
Appendix	2	6.7
Colon	6	20

The highest incidence was seen in 5 cases (16.7%) of enterocutaneous fistula were encountered on 7th post-operative day. However, in three case leaks occurred on 2nd post-operative day. The maximum time for occurrence of fistula was 15th post-operative day which occurred in only one case in this series. [Table 4]

**Table 4: Output of fistula.**

Output	No. of cases	Percentage
High (>500ml/24 hours)	8	26.7
Moderate (200-500ml/24 hours)	12	40
Low (<200ml/24 hours)	10	33.3
Total	30	100

**Table 5: Number of Patients Receiving Conservative and / or Operative Treatment.**

Site of fistula (total)	Conservative treatment		Operative treatment	
	Number	Percentage	Number	Percentage
Stomach (1)	-	-	1	3.3
Duodenum(6)	3	10	3	10
Jejunum(7)	4	13.3	3	10
Ileum (8)	6	20	2	6.7
Appendix(2)	1	3.3	1	3.3
Colon (6)	5	16.7	1	3.3
Total	19	63.4	11	36.6

19 cases (63.4%) of enterocutaneous fistula of various types were treated by conservative method

and rest 11 (36.6%) were treated by operative treatment. The result of conservative treatment. Total of 19 cases were managed conservatively out of which 17 cases (89%) showed spontaneous closure of fistulae. However 2 cases (11%) did not improve and died. Fistulae from duodenum, ileum and appendix had a spontaneous closure rate of 100% in the conservative group. Fistulae from jejunum and colon had spontaneous closure rates of 75% and 80% respectively. The average number days taken by the fistula to close were highest (82 days) for ileum and lowest (22 days) also for ileal fistula. [Table 5] Indications for operative management: Most common was persistent discharge from the fistula for more than 6 weeks in 7 cases, followed by abdominal wound dehiscence in 3 cases. Results of operative treatment: Total of 11 cases was subjected to surgical treatment. Out of which 8 cases (72.3%) had successful closure of fistula. However 3 cases (27.3%) died even after they were subjected to operation. 66.7% cases of duodenal and jejunal fistula showed successful results after operation. Fistula from stomach, ileum and appendix showed 100% results and were cured by operative treatment. Complications of enterocutaneous fistula: Most of the fistulae about (53.4%) 16 cases had moderate to severe weight loss. About 13 cases (43.3%) had mild complications like skin excoriation and mild weight loss only. One patient developed haemorrhage from the fistula site. Abdominal wound dehiscence which was observed in (10%) 3 cases.

### DISCUSSION

Enterocutaneous fistula were common in 4th, 5th and 6th decade of life with maximum number of cases in 4th decade.<sup>[9]</sup> The ratio of male and female was 4: 1. The highest incidence (46.7%) of enterocutaneous fistula was observed in cases operated for abdominal trauma. 9 cases (30%) developed following operation for intestinal obstruction. 5 cases (16.7%) following peptic perforation operation. The maximum cases of enterocutaneous fistula which occurred after operation for injury of intestine was following blunt injury of abdomen in 64.3% of cases and 21.4% in penetrating injury cases.<sup>[10]</sup> Maximum number of fistula (86.7%) developed after emergency surgery and 13.3% after routine surgery. The highest incidence (30%) of enterocutaneous fistula occurred following resection anastomosis of ileum, followed by resection anastomosis of jejunum (23.3%). 16.7% and 10 % cases occurred following duodenal perforation closure and pelvic colectomy and anastomosis respectively. The maximum incidence (26.7%) of enterocutaneous fistula occurred on 7th postoperative day. 26.6% of cases were found to be having a fistula from ileum, 23.3% cases from jejunum and 20% from duodenum.<sup>[11,12]</sup> Majority (40%) fistula were of moderate output. 33.3 % cases

were with low output and 26.6% cases were of high output. 63.4% were treated by conservative method alone and 36.6% needed operative treatment in addition to conservative treatment. In 56.6% of cases fistulae closed spontaneously by conservative treatment only. Persistent discharge from fistula (63.3% cases) and abdominal wound dehiscence (27.2%) were the most important indications for operative treatment. In 9 % cases deep seated abscess was indication for operative treatment.<sup>[13,14]</sup> In 54.6% cases fistulaectomy and reanastomosis was done. In 27.3% cases tension suture for abdominal wound dehiscence was given, in 9 % cases drainage of deep seated abscess was done. 72.7% closure rate was observed in cases receiving operative treatment in addition to conservative treatment. The commonest complication seen was moderate to severe weight loss which was present in 16 patients (53.3%). In 13 cases (43.3%) there was only localized skin excoriation and mild weight loss. Abdominal wound dehiscence was seen in (10%) 3 cases. Infections like abdominal abscess and peritonitis occurred in (6.7%) 2 cases. One patient (3.3%) died of haemorrhage from the fistula site. The overall mortality in cases of enterocutaneous fistula was 20%. Maximum number of cases (15) had to stay in hospital for up to two months. 11 cases up to 1 month and 4 cases for more than 2 months.<sup>[15]</sup>

### CONCLUSION

It is concluded that enterocutaneous fistula frequently follow emergency surgery on gastrointestinal tract, particularly the ileum, duodenum and colon, usually occurring around the 7th postoperative day and most end in spontaneous closure with conservative therapy. Surgery should be restricted to treatment of specially indicated patients like prolonged continuous fistulous discharge, abdominal wound dehiscence and deep seated intraperitoneal abscess. The common complications occur are weight loss, infection, skin excoriation, abdominal wound dehiscence. Total management of an enterocutaneous fistula involves skilled nutritional support, stoma therapy, elimination of sepsis and carefully timed, well judged and well carried out surgery. Prompt attention, sustained enteral or parenteral nutritional support and improvement of general condition of the patient are important factors for better result.

### REFERENCES

1. Chapman R et al: Management of intestinal fistulas: Am. Jr. Surg, 108: 157-164, 1964.
2. Edmunds LH Jr et al: External fistulas arising from GI tract. Am. Jr. Surg, 152: 445-471, 1960.
3. Elhence JP et al: In. Jr. Surg, 42: 528, 1980.

4. Fisher JE: The pathophysiology of enterocutaneous fistula. *World Jr. Surg.* 446-450, 1983.
5. Halvesen RC et al: Gastric and small bowel fistulas: *Am. Jr. Surg.* 118: 968, 1969.
6. Krasner D: Managing draining wounds: Fistula leaking tube and drains, *wound management*, 19:79, 1988.
7. Levy E et al: high output external fistula from small bowel: management with continuous external nutrition. *Br. Jr. Surg.* 76: 676, 1989.
8. Hollander LF et al: Post operative fistula of small intestine. Therapeutic principle. *World Jr. Surg.* 474-480, 1983.
9. Ian C Levery: Colonic fistula: *Surg. North Am*, 1183-1189. 1996.
10. Irving M, Beadle C: External intestinal fistulas: Nursing care and surgical procedures. *Clin. Gastrent*, 11: 327-336, 1982.
11. Nasso TP, Brash JW: External small bowel fistulas: current treatment and result, *Surg. Clin. North Am.* 51: 687, 1971.
12. Oetman B et al: Innovative pouch modification for high output ostomy drainage. *Nursing*, 21: 34-37, 1994.
13. Reber HA, Roberts C: Management of external gastroent fistula. *Ann. Surg.* 188:460-467, 1978.
14. Wolfe BM et al: Complications of parenteral nutrition, *Am. Jr. Surg.* 152: 93-99, 1986.
15. Scott M Berry and Josef E Fisher: Classification and pathophysiology of enterocutaneous fistulas. *Surg. Clin. North Am*, 76: 1009-1015, 1996.

**How to cite this article:** Mohanty SK, Mohanty R. Evaluation and Management of Post-Operative Enterocutaneous Fistula. *Ann. Int. Med. Den. Res.* 2017; 3(4):SG01-SG04.

**Source of Support:** Nil, **Conflict of Interest:** None declared