

## Imaging of Emphysematous Osteomyelitis: A case Report.

Rajesh Shanklesha<sup>1</sup>, Yadav Shashibala Jayanarayan<sup>2</sup>, Abhishek Jain<sup>3</sup>, Pratik Raiththa<sup>4</sup>

<sup>1</sup>Fellow in body imaging, B.Y.L. Nair Charitable Hospital, Mumbai.

<sup>2</sup>Fellow in Diagnostic Radiology, B.Y.L. Nair Charitable Hospital, Mumbai.

<sup>3</sup>Resident, Department of Radio-Diagnosis, T.N.M.C. & B.Y.L.Nair Charitable Hospital, Mumbai.

<sup>4</sup>Clinical associate, global hospital, Mumbai.

Received: February 2017

Accepted: February 2017

**Copyright:** © the author(s), publisher. It is an open-access article distributed under the terms of the Creative Commons Attribution Non-Commercial License, which permits unrestricted non-commercial use, distribution, and reproduction in any medium, provided the original work is properly cited.

### ABSTRACT

Presence of intraosseous gas in absence of any obvious fracture or history of surgery specially if present in extra-axial skeleton suggest emphysematous osteomyelitis. Though rare it is a serious infection which needs immediate diagnosis and prompt treatment. The organisms usually causing emphysematous osteomyelitis include staphylococcus, streptococcus, klebsiella, E.coli and sometimes Mycobacterium tuberculosis. In some cases the cause may be polymicrobial. The radiological differential diagnoses of emphysematous osteomyelitis include trauma, post-surgical change, degenerative diseases, osteonecrosis, post-biopsy and malignant bone lesions. The patients having immunodeficiency are prone to develop emphysematous osteomyelitis. The mechanism of infection is usually hematogenous spread. In rare instances it may spread from a local infection like from skin or soft tissue. The diagnosis of emphysematous osteomyelitis depends upon constitutional symptoms like fever, malaise, leukocytosis and presence of intraosseous air. In some cases surrounding soft tissue may also show presence of gas. CT scan can depict presence of intraosseous air more precisely. It may also show presence of any adjacent abscesses. Early diagnosis and immediate treatment is required and antibiotics should not be withheld even if microbiology culture and sensitivity reports are awaited. We report here a case of emphysematous osteomyelitis caused predominantly by Group B streptococci. The imaging findings of intraosseous gas in Head of femur, humerus, iliac bone and vertebral bodies on computed tomography aided in early diagnosis and treatment.

**Keywords:** Emphysematous osteomyelitis, Imaging features, Computed Tomography, Antibiotics.

### INTRODUCTION

In 1981 Ram et al first described radiological finding of intraosseous gas as a sign of osteomyelitis on computed tomography.<sup>[1]</sup> Subsequently in 1983, Patton and colleagues described intramedullary gas within the femur on plain film.<sup>[2]</sup> When present in the extra-axial skeleton, intraosseous gas is virtually diagnostic of emphysematous osteomyelitis. The organisms causing emphysematous osteomyelitis include staphylococcus, streptococcus, klebsiella, E.coli and sometimes Mycobacterium tuberculosis. Though the presence of intraosseous gas is pathognomic of emphysematous osteomyelitis certain differential diagnosis like post-traumatic intraosseous gas should be considered when history of trauma is present.

#### Name & Address of Corresponding Author

Dr. Abhishek Jain  
Resident,  
Department of Radio-Diagnosis,  
T.N.M.C. & B.Y.L.Nair Charitable Hospital,  
Mumbai.

Co-morbid conditions causing immunosuppression like acquired Immunodeficiency syndrome, diabetes

mellitus, primary immunodeficiency states, and prolonged steroid therapy predispose patients for developing emphysematous osteomyelitis.<sup>[4]</sup> The mechanism of infection is usually haematogenous. However, some cases of

emphysematous osteomyelitis following local spread from an adjacent site like skin or subcutaneous tissue, from intra-abdominal infection, following major surgeries have also been reported. Early diagnosis of emphysematous osteomyelitis is essential and depends upon constitutional symptoms like fever, malaise, and leukocytosis.

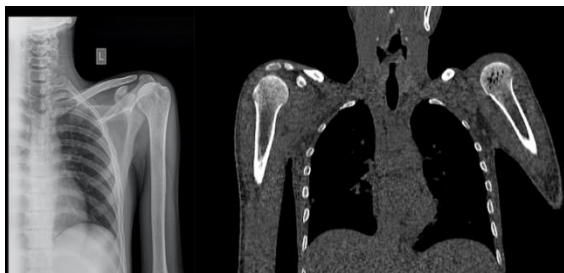The finding of intraosseous gas with constitutional symptoms is highly suggestive of emphysematous osteomyelitis. Though the intraosseous gas can be detected on Plain X-ray, Computed tomography and MRI, it is very difficult to demonstrate intraosseous gas on plain X-ray films especially in early stages. Computed tomography can detect early signs of emphysematous osteomyelitis. Magnetic resonance imaging may give the advantage of showing soft tissue changes in addition to better depiction of marrow signal abnormalities.<sup>[5]</sup> Since emphysematous osteomyelitis is associated with high morbidity and mortality early diagnosis and prompt treatment is a prerequisite to management.

## CASE REPORT

A 21 year old male patient was admitted with complaints of high grade fever, chills, yellowish discoloration of eyes and pain in the left thigh. Patient had a family history of sickle cell anemia. Patient also had a past history of recurrent joint pains, low backache and generalized weakness. For these complaints the patient consulted a local hospital where he was given some injection after which he felt relief of pain for sometime but again he started getting fever with chills and recurrence of pain in left thigh.

On admission the patient had a high grade fever (103<sup>0</sup> F). Patient was conscious and oriented. General examination showed redness and swelling in the medial aspect of left thigh. There was a partially healed wound of tarsometatarsal amputation on left side. The amputation was done 2 months back for gangrene. There was tenderness on palpation at L4-L5 vertebra. Systemic examination was normal. Complete blood count revealed leukocytosis (TLC-16000/mm<sup>3</sup>), elevated ESR (50mm/hr), Anemia (Hb-8.2gms), Elevated liver enzymes and raised bilirubin levels (7.8 gms). Renal Function tests were normal. Blood culture and a sample of pus were sent for culture and sensitivity tests before beginning the treatment.

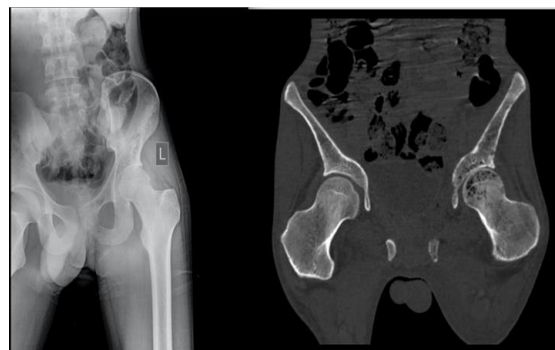In view of pain, tenderness and swelling of left thigh an initial plain X-Ray of left thigh was done which showed lucent foci in the left iliac bone. Similar lucent foci were also noted in the head of left humerus on left shoulder X-ray [Figure 1].



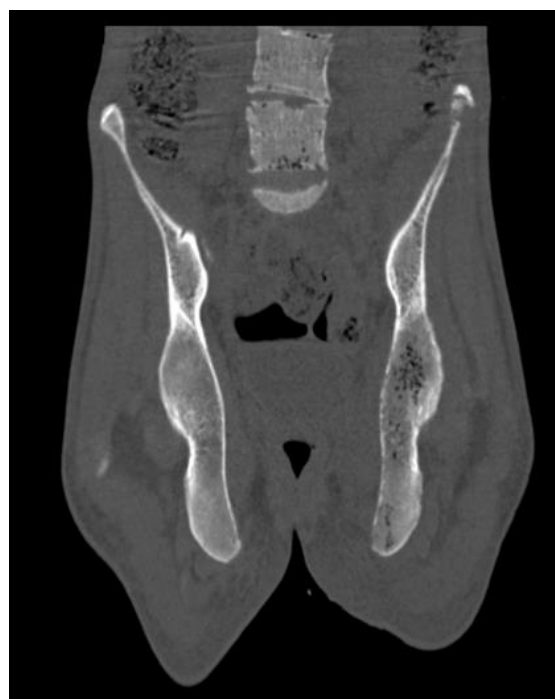**Figure 1:** Left humeral head showing lucent foci. CT confirmed presence of intraosseous gas within humeral head.

In view of leukocytosis with raise ESR and presence of lucent foci a possibility of intraosseous gas secondary to emphysematous osteomyelitis was considered and computed tomography was done which confirmed the presence of multiple foci of gas within left humeral head, left iliac bone, left femoral head, L4 and L5 vertebral bodies [Figure 2,3].

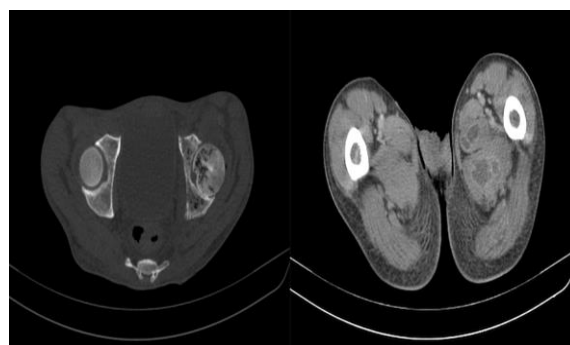
Computed tomography also revealed loculated fluid collections in the soft tissues medial to the proximal shaft of left femur with few foci of air and enhancement of walls on post contrast study suggestive of abscesses [Figure 4].



**Figure 2:** X ray showing lucent foci in left iliac bone and femoral head. Computed tomography confirmed presence of gas confirming the diagnosis of emphysematous osteomyelitis.



**Figure 3:** Intraosseous gas in vertebral bodies of L4 and L5 seen on computed tomography. Note uneven and bubbly appearance of gas within vertebral bodies.



**Figure 4:** Computed tomography showing loculated fluid collections in the soft tissues medial to shaft of femur on left side s/o abscess formation.

In view of characteristic imaging finding a diagnosis of emphysematous osteomyelitis was done and

intravenous antibiotics were started. Culture and sensitivity of clinical sample collected from medial aspect of upper thigh showed isolate of streptococci and Klebsiella species sensitive to amikacin and imipenem hence the antibiotic therapy was switched to amikacin and imipenem. The patient responded well to surgical debridement and IV antibiotic therapy. He became afebrile within 48 hours of starting amikacin and imipenem. Later patient was discharged with an advice to follow up.

## DISCUSSION

Emphysematous osteomyelitis is a rare but serious condition. Since first described by Ram and colleagues the prevalence has been very low, and only few cases have been reported in English literature. All reported cases have been in either one or more of the following locations: thoracic and lumbar vertebrae, sacral bones, femur, pelvis, tibia, or fibula.<sup>[6]</sup> Conditions causing immunosuppression like primary immunodeficiency syndromes, diabetes mellitus, HIV infection and malignancies predispose patients for development of emphysematous osteomyelitis. In our patient, immunosuppression due to poorly controlled diabetes mellitus, splenectomy (Non functional spleen secondary to sickle cell anemia) and alcohol abuse likely played an important role in the development of this serious infection. The most common cause of emphysematous osteomyelitis is hematogenous spread. In this case, a partially open wound from previous transmetatarsal amputation was the probable portal of infection, progressing to necrotizing fasciitis and subsequently emphysematous osteomyelitis.

Causative organisms include a range of both aerobic and anaerobic bacteria. Most commonly cultured organisms from both mono- and polymicrobial reported cases of emphysematous osteomyelitis include an anaerobe or a member of the Enterobacteriaceae family. In our case, Gram staining of the pus suggested a polymicrobial infection with abundant gram-positive cocci, and the culture indicated that Group G *Streptococcus* was the predominant organism. Growth of the gram negative bacilli seen on Gram stain, and potentially anaerobes, may have been suppressed by prior antibiotic therapy. Interestingly, this is the first reported case of emphysematous osteomyelitis to isolate Group G *Streptococcus*. Lancefield Group G streptococci have been identified as part of the normal microbial flora of the pharynx, skin, vagina, and gastrointestinal tract. It is known to cause a spectrum of invasive infections, including necrotizing fasciitis and osteomyelitis, usually in patients with significant underlying disease such as diabetes mellitus and malignancy.<sup>[7]</sup> Therefore, given the virulence of this organism, it would seem reasonable to conclude that our patient developed

necrotizing fasciitis and emphysematous osteomyelitis predominantly, if not entirely, due to Group G *Streptococcus* infection.

The radiological differential diagnosis for the presence of intraosseous gas includes osteonecrosis, bone malignancy, post-biopsy, penetrating wounds, compound fractures, and lymphangiomatosis of the bone. Gas may also accumulate anywhere in the body where substantial negative pressure develops. Intravertebral gas may be seen when negative pressure develops in the intervertebral disc as a manifestation of disc degeneration. On the other hand, extensive intravertebral gas associated with bone edema and/or fluid collections should raise suspicion of emphysematous osteomyelitis. One of the important and close differential diagnoses to emphysematous osteomyelitis is vacuum phenomenon seen in degenerative conditions of spine. The distribution of gas is linear and well demarcated in degenerative conditions where as in emphysematous osteomyelitis the distribution of gas is uneven and bubbly. Extension into adjacent soft tissue also favours the diagnosis of emphysematous osteomyelitis rather than degenerative changes.<sup>[8]</sup> Radiological examination played a critical role in determining the nature and extent of infection in our patient and enabled the implementation of an aggressive treatment plan. Plain films suggested the rare finding of intraosseous locules of air as well as significant soft tissue gas, prompting the diagnosis of a serious infection, initially considered to represent necrotizing fasciitis. CT not only confirmed the X-ray findings, but also revealed the extent of intraosseous gas and depicted soft tissue abscesses. Surgical intervention is the cornerstone of treatment of both emphysematous osteomyelitis and necrotizing fasciitis.<sup>[9]</sup>

Emphysematous osteomyelitis is associated with high mortality and significant morbidity, especially in diabetic patients. Early diagnosis and immediate treatment are crucial in preventing the potentially devastating consequences of the disease.<sup>[10]</sup>

Treatment in our patient required below-knee amputation in an attempt to remove all infected bone and soft tissue. Ultimately, surgical debridement and intravenous antibiotic therapy proved successful in controlling the spread of the infection and in preventing further tissue loss.

## CONCLUSION

Emphysematous osteomyelitis is a rare but serious condition carrying considerable morbidity and mortality. It can present as lucent foci on X-ray. The diagnosis can be confirmed by demonstration of intraosseous gas by computed tomography. The role of radiologist in reporting presence of intraosseous gas as first sign of emphysematous osteomyelitis leading to early antimicrobial and surgical management cannot be overemphasized.

## REFERENCES

1. Ram PC, Martinez S, Korobkin M, Breiman RS, Gallis HR, Harrelson JM. CT detection of intraosseous gas: a new sign of osteomyelitis. *The American Journal of Roentgenology*. 1981;137(4):721-723.
2. Patton HM, Conlan JK, Long RF, Waller JT. Unusual presentation of anaerobic osteomyelitis. *The American Journal of Medicine*. 1983;75(4):724-726.
3. Aiyappan SK, Ranga U, Veeraiyan S. Spontaneous emphysematous osteomyelitis of spine detected by computed tomography: Report of two cases. *Journal of Craniovertebral Junction and Spine*. 2014;5(2):90-92.
4. O. McDonnell and Z. Khaleel, "Emphysematous osteomyelitis," *JAMA Neurology*, vol. 71, no. 4, 2014.
5. Lee YJ, Sadigh S, Mankad K, Kapse N, Rajeswaran G. The imaging of osteomyelitis. *Quantitative Imaging in Medicine and Surgery*. 2016;6(2):184-198.
6. Luey C, Tooley D, Briggs S. Emphysematous osteomyelitis: a case report and review of the literature. *Int J Infect Dis*. 2012 Mar;16(3): e216-20.
7. Wong SS, Lin YS, Mathew L, Rajagopal L, Sepkowitz D. Increase in Group G Streptococcal Infections in a Community Hospital, New York, USA. *Emerging Infectious Diseases*. 2009;15(6):991-993.
8. Feng SW, Chang MC, Wu HT, Yu JK, Wang ST, Liu CL. Are intravertebral vacuum phenomena benign lesions? *Eur Spine J*. 2011 Aug;20(8):1341-8
9. Cierny G 3rd. Surgical treatment of osteomyelitis. *Plast Reconstr Surg*. 2011 Jan;127 Suppl 1:190S-204S.
10. Fritz JM, McDonald JR. Osteomyelitis: Approach to Diagnosis and Treatment. *The Physician and sportsmedicine*. 2008;36(1):nihpa116823.

**How to cite this article:** Shanklesha R, Jayanarayan YS, Jain A, Raiththa P. Imaging of Emphysematous Osteomyelitis: A case Report. *Ann. Int. Med. Den. Res*. 2017;3(2):RD26-RD29.

**Source of Support:** Nil, **Conflict of Interest:** None declared