

# Role of Magnetic Resonance Imaging in Fetal Ventriculomegaly.

Praveen Bhosale<sup>1</sup>, Manohar B Kachare<sup>2</sup>

<sup>1</sup>Assistant Professor, Department Of Radiodiagnosis, Government Medical College Miraj- MS (India).

<sup>2</sup>Professor and Head, Department Of Radiodiagnosis, Government Medical College Miraj- MS (India).

Received: August 2017

Accepted: August 2017

**Copyright:**© the author(s), publisher. It is an open-access article distributed under the terms of the Creative Commons Attribution Non-Commercial License, which permits unrestricted non-commercial use, distribution, and reproduction in any medium, provided the original work is properly cited.

## ABSTRACT

**Background:** Fetal ventriculomegaly is diagnosed when maximal diameter of the atrium of the lateral ventricles exceeds 10 mm. The overall prevalence of fetal ventriculomegaly ranges between 1-2 per 1000. The etiopathogenesis of fetal ventriculomegaly can be either due to imbalance between production and absorption of CSF or abnormal cerebral development. In addition to these 2 mechanisms destructive disease processes, vascular insults and intrauterine infections can also cause fetal ventriculomegaly. In addition to objectively assessing the severity of fetal ventriculomegaly MRI can also detect structural anomalies, white matter pathologies and destructive lesions affecting fetal brain. This study was performed to evaluate the utility of fetal MRI for prenatal assessment of fetal ventriculomegaly. **Aims and Objectives:** To evaluate the utility of fetal MRI for prenatal assessment of fetal ventriculomegaly. **Methods:** This was a prospective cohort study conducted in the department of radio-diagnosis in a tertiary care hospital situated in a metropolitan city over a period of 24 months. All pregnant women who have been referred for fetal MRI after a diagnosis of fetal ventriculomegaly on ultrasound were included in this study. MRI was done using GE 1.5 Tesla TWIN SPEED, HDX MRI machine using pre-defined protocol. The data was collected on pre-designed study pro forma. The data was entered in Microsoft Excel Program and checked for any inconsistencies. Data was analysed using SPSS 16.0 version. **Results:** The prevalence of ventriculomegaly was found to be 40% (12 out of 30). Out of this bilateral ventriculomegaly was seen in 8 cases (66.66%) while unilateral ventriculomegaly was seen in 4 cases (33.33%). Isolated ventriculomegaly was seen in 6 cases (50%) while ventriculomegaly was associated with other CNS anomalies in rest (50%). Out of 12 cases with ventriculomegaly 7 patients (58.33%) had mild ventriculomegaly and moderate and severe ventriculomegaly was seen in 3 (25%) and 2 (16.67%) patients respectively. **Conclusions:** MRI is a valuable imaging modality for the diagnosis of fetal ventriculomegaly. It can reliably diagnose ventriculomegaly as well as any associated abnormalities. It can be further used to decide management and predict the outcome of patients with fetal ventriculomegaly.

**Keywords:** Fetal Ventriculomegaly, Magnetic Resonance Imaging, CNS malformations.

## INTRODUCTION

Fetal ventriculomegaly is defined as dilatation of lateral cerebral ventricle > 10 mm at the level of atrium irrespective of the gestational age.<sup>[1]</sup> The incidence of fetal ventriculomegaly is reported to be approximately 1 out of 1000 live births.<sup>[2]</sup> The common causes of such ventricular dilatation include obstructive hydrocephalus, cerebral dysgenesis, intrauterine infections and post-inflammatory dilatation.<sup>[3]</sup> The fetal ventriculomegaly can be an isolated feature with no other associated anomaly or it may be associated with various congenital malformations like Arnold Chiari malformation, Dandy walker malformation,

Agenesis of corpus callosum or chromosomal anomalies like Down syndrome.<sup>[4]</sup> It is important to comprehend that ventriculomegaly is not always associated with macrocephaly and many times fetal head circumference may be within 2 standard deviations of the mean despite the presence of ventriculomegaly.<sup>[5]</sup>

Despite the practical difficulties of doing MRI in a pregnant woman like accessibility, cost and availability of radiologists in reporting fetal MRI it is recommended in cases of fetal ventriculomegaly because of its ability to detect any additional abnormalities, which might give insight into the etiology of the ventriculomegaly as well as neurodevelopmental outcome for the fetus.<sup>[6]</sup> Fetal MRI can detect additional abnormalities which include agenesis of the corpus callosum, cortical malformations, periventricular heterotopias, cerebellar malformations, hemimegalencephaly, periventricular white matter injury, porencephaly, multicystic encephalomalacia, intraventricular hemorrhage and germinal matrix hemorrhage.<sup>[7]</sup> The neurodevelopmental outcome of fetal

### Name & Address of Corresponding Author

Dr Manohar B Kachare  
Professor and Head,  
Department Of Radiodiagnosis,  
Government Medical College Miraj-  
MS (India).

ventriculomegaly is better when the ventricles are only mildly dilated and when no additional sonographic and genetic abnormalities are identified prenatally or at birth. Ventriculomegaly is measured at the posterior margin of the glomus of the choroid plexus on an axial image through the thalami. This measurement can be obtained on MR images in a manner similar to that with ultrasound. The ventriculomegaly is said to be mild, moderate or severe if dilatation of lateral cerebral ventricle is between 10-15 mm at the level of atrium, >15 mm and with 3 mm of adjacent cortical thickness and ventricular dilatation of >15mm with <2 mm of adjacent cortical thickness respectively.<sup>[8]</sup>

Though severe ventriculomegaly is more likely to be associated with other associated congenital anomalies or chromosomal defects it is important to know that fetal ventriculomegaly is the consequence of many evolving pathologies and many a times associated defects will only become visible over a period of time. The classical example of such an eventuality is migration abnormalities which become evident late during gestation or in postnatal life. This feature makes it difficult to predict about the prognosis of an individual fetus with ventriculomegaly making it difficult to provide counseling to prospective parents at the time of initial diagnosis.<sup>[9]</sup>

When evaluating the brain in cases of isolated mild ventriculomegaly, the walls of the ventricles should be carefully examined for any areas of irregularity or modularity that might indicate periventricular nodular heterotopias or subependymal hemorrhage. Germinal matrix hemorrhage is best detected as an area of marked decreased signal on gradient EPI & SSFSE images in the ventricular germinal matrix, which may also appear abnormally thickened for the fetus's gestational age, or as an area of increased signal on T1-weighted images.<sup>[10]</sup> Focal cysts in the region of the germinal matrix can result from prior germinal matrix hemorrhage, congenital infection, or certain metabolic disorders. The ventricles should also be evaluated for intraventricular hemorrhage, which can result in ventriculomegaly.<sup>[11]</sup> The developing white matter should also be carefully examined for evidence of diminished parenchymal thickness as well as destructive lesions. More subtle irregularity of the ventricular margin might also be an indication of injury to the overlying developing white matter. The corpus callosum should be directly visualized and measured on midline sagittal fetal MRI images because sonographically diagnosed ventriculomegaly can actually be a result of abnormalities of the corpus callosum.<sup>[12]</sup> More specifically callosal hypogenesis or callosal agenesis can result in dilation of the posterior lateral ventricles, leading to the appearance of isolated ventriculomegaly on prenatal US. Fetal MRI can also detect cortical malformations, which can be seen in association with ventriculomegaly. These

include but are not limited to lissencephaly, schizencephaly, and polymicrogyria.<sup>[13]</sup>

## MATERIALS & METHODS

This was a prospective cohort study comprising of 30 pregnant females who were referred for further evaluation by fetal MRI. The study was conducted over a period of 2 years in the Department of Radio Diagnosis and Imaging at a tertiary care hospital situated in a metropolitan city. The sample size is justifiable if study of Hosny IA et al is taken in account (In this study the sample size was 25). MRI brain was done on GE 1.5 Tesla TWIN SPEED, HDX MRI machine in all the patients. The non-imaging data (Demography, gestational age, findings of antenatal ultrasound scans etc) was collected as described in Pro forma.

Institutional Ethical committee approved the study. Written informed consent was taken before doing MRI in all the patients. All patients were scanned in supine position after making them comfortable. Most fetal MRIs were primarily performed using an initial localizer obtained in three orthogonal planes with respect to the mother, using 6- to 8-mm thick slices with a 1 to 2 mm gap and a large field of view. The localizer is used to visualize the position of the fetus and determine fetal sidedness, as well as to ensure that the coil is centered over the region of interest. Typically, 3-mm thick ultrafast T2-W images of the fetal brain were then prescribed from the localizer with no skip. Images were acquired during maternal free breathing and in an interleaved fashion in order to reduce signal loss due to cross-talk between adjacent slices. Images were acquired in the axial, sagittal, and coronal planes. Diffusion-weighted imaging (DWI) used to identify focal areas of injury as well as to assess brain development. Gradients are applied in three orthogonal directions using a b value of 0 s/mm<sup>2</sup> and 600 s/mm<sup>2</sup>. The data was collected on pre-designed study pro forma. All the data was entered in Microsoft Excel Program and checked for any inconsistencies. Data was presented in terms of percentages and proportions.

### Inclusion Criteria

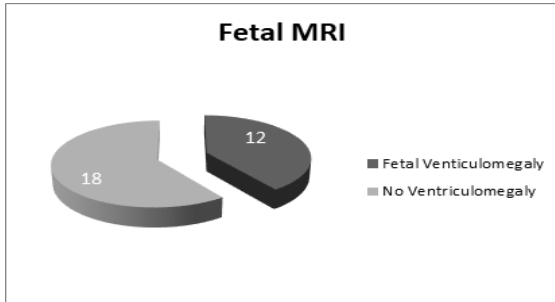
- All pregnant women with suspected fetal brain anomalies on Ultrasound.
- Pregnant women with previous history of fetal congenital anomalies involving brain.
- Pregnant women with confirmed diagnosis of congenital anomalies of fetus in utero who are less than 18 weeks and are scheduled for termination.

### Exclusion Criteria

- Those patients who refused consent.
- Pregnant women in whom MRI was contraindicated like claustrophobic patients, patients with pacemakers or cochlear implants.
- Pregnant women who required sedation.

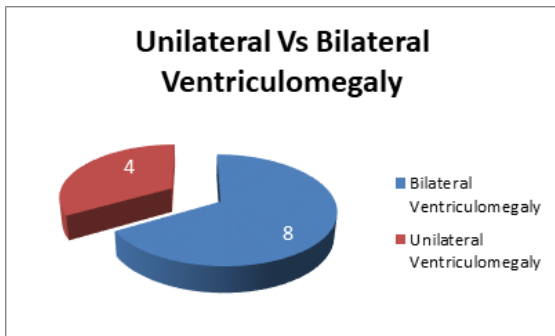
**RESULTS**

This study was a prospective cohort study comprising of pregnant women referred to our department for fetal MRI scan for further evaluation during the study period. A total of 30 patients underwent fetal MRI. Out of these 30 patients 12 (40%) fetuses were found to be having ventriculomegaly.



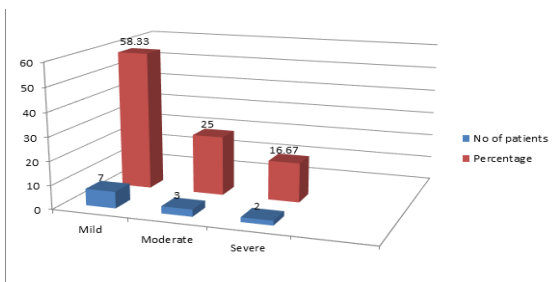
**Figure 1: Presence of fetal ventriculomegaly in studied cases.**

Out of the 12 patients who had fetal ventriculomegaly 8 (66.66%) had bilateral ventriculomegaly while 4 (33.33%) had unilateral ventriculomegaly.



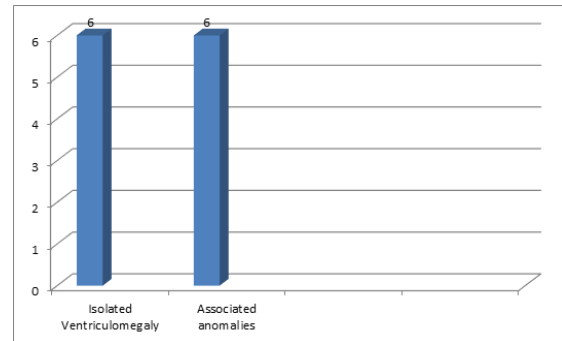
**Figure 2: Bilateral Vs Unilateral Ventriculomegaly in studied cases.**

The analysis of severity of the ventriculomegaly revealed that 2 out of 12 cases (17%) of ventriculomegaly were of severe category. 3 out of 12 (25%) were of moderate category while 7 out of 12 (58%) cases had mild ventriculomegaly. Majority of the studied patients has mild type of fetal ventriculomegaly.



**Figure 3: Severity of fetal ventriculomegaly in the studied cases.**

In 6 out of 12 cases (50%) we have found various associated central nervous system anomalies which included sulcation abnormalities, Agenesis of corpus callosum and germinal matrix hemorrhage. Majority of the patients (3/12) with associated anomalies belonged to mild ventriculomegaly group while moderate and severe ventriculomegaly was associated with associated anomalies in 2 (2/12) and 1(1/12) patients respectively.



**Figure 4: Isolated ventriculomegaly Vs Associated anomalies.**

The analysis of the outcome of the patients with fetal ventriculomegaly revealed that out of the 12 patients 4 (33.33%) opted and underwent termination of pregnancy. In 3 (25%) patients pregnancy was continued till the last follow up and out of these 3 patients 1 belonged to mild ventriculomegaly and 2 belonged to moderate ventriculomegaly. Fetal loss (either IUFD or stillbirth was seen in) occurred in 2 patients (one belonging to mild ventriculomegaly and another one had severe ventriculomegaly). Out of remaining 3 patients 1 was lost to follow up and 2 gave birth to normal full term babies without any apparent congenital anomalies. The details of the studied cases are given in tabulated form below.

**DISCUSSION**

Fetal ventriculomegaly has drawn attention of many radiologists and geneticists as a marker of plethora of CNS abnormalities. It is one of the common intracranial pathologies seen on routine antenatal scans. It is demonstrated in many studies that the ventricle size remain fairly constant in second and third trimesters and this finding is used to determine the cut-off of 10 mm for the diagnosis of fetal ventriculomegaly. Since in most of the instances the severity of ventricular dilatation determines whether other associated anomalies or chromosomal defects will be present or not it is of paramount importance to accurately measure size of ventricles at the level of atrium.<sup>[14]</sup>

Fetal ventriculomegaly is first encountered or detected at the time of antenatal scan. Ideally during sonography the measurement of ventricle should be done in true axial plane at the level of atria of lateral ventricle and gloms of choroid plexus. When detected on ultrasound it is considered as soft marker

for chromosomal anomalies and it should prompt the radiologist to look for presence of other anomalies.<sup>[15]</sup> While mild ventriculomegaly without presence of chromosomal defects or associated anomalies is expected to regress on its own severe ventriculomegaly is more likely to be associated with additional anomalies and chromosomal defects.<sup>[16]</sup>

There has been a great deal of scholarly work correlating prenatal factors in foetuses with ventriculomegaly and final postnatal outcome. Factors like severity of ventriculomegaly, presence of associated anomalies. P.Gaglioti et al conducted a

study comprising of 176 cases having fetal cerebral ventriculomegaly and found that measurement above 12 mm and less than 15 mm were more commonly associated with associated structural abnormalities. Various associated anomalies in this associated were found to be heart diseases, spina bifida, Dandy walker syndrome, dysmorphia, sacral agenesis, dysmorphia, agenesis of corpus collasum and club foot. The authors recommended that the patients with fetal ventriculomegaly should undergo targeted ultrasound examination, fetal echocardiography and MRI.<sup>[17]</sup>

**Table 1: Details of Ventriculomegaly cases, severity, associated finding and outcome of the studied cases.**

VM Present=1 Absent=0	Laterality Bilateral=1 Unilateral=0	severity Mild=1; Moderate=2; Severe=3	Associated findings	Follow Up
1	1	3	Restricted diffusion and possible hemorrhagic focus in periventricular area of right lateral ventricle suggestive of destructive VM.Sulcation lag behind gestational age(nonappearance of sylvian fissure)	TOP
1	1	3	-	LSCS with Still borne child
1	1	2	Interhemispheric cyst with few thin septa	TOP
1	1	2	Agenesis of corpus collasum	Ongoing Pregnancy
1	1	2	-	Ongoing Pregnancy
1	1	1	Grade I subacute right germinal matrix bleed	Spontaneous IUFD
1	1	1	Multiple foci of T2 hypointensity around lateral ventricles .DD- old hemorrhage or small tubers .Poorly visualised posterior CC.	Normal Delivery.Female child.
1	1	1	Non-visualisation of CC in posterior aspect-consistent with partial ACC.	Lost to follow up
1	0	1	-	Delivered Full term baby.
1	0	1	-	Ongoing Pregnancy
1	0	1	-	TOP
1	0	1	-	TOP

MRI is definitely better than ultrasonographic examination for the diagnosis of associated anomalies in fetuses with ventriculomegaly. Moreover Ultrasound is operator dependant and the features are difficult to appreciate in obese patients. MRI is beneficial in the diagnosis of fetal ventriculomegaly as it is highly sensitive and specific and can detect associated anomalies fairly reliably. Ultrasound sulcus visualization lags behind MRI sulcus visualization and more sulci are seen at an earlier age of gestation by Magnetic resonance imaging than ultrasound. It is found that sulcal visualization was comparatively more delayed in fetuses with associated CNS anomalies than in fetuses with isolated ventriculomegaly.<sup>[18]</sup>

The outcome of moderate to severe ventriculomegaly is worse with studies reporting up to 60%-80% of abnormal outcome in these children. Though it is widely reported that the mild ventriculomegaly is usually associated with a normal neurodevelopment outcome this inference should be taken with a little caution as many studies have put forth contrary views. A study by John H Gilmore in which the authors followed up 5 children with mild

enlargement of lateral ventricles on prenatal scans found that 1 of those children developed attention deficit hyperactive disorder, one child became autistic and 2 had evidence of learning disability. The authors showed that the primary pathology in these disorders causes mild ventricular dilatation which can be picked up on antenatal ultrasound. According to authors in these cases fetal ventriculomegaly is the consequence and not the cause of these disorders. Finally they concluded that the study of fetal ventricle development with ultrasound and MRI can provide important insights into neurodevelopmental disorders and allow the identification of children at high risk.<sup>[19]</sup>

To conclude it can be safely said that MRI is a better imaging modality than ultrasound in detecting presence and severity of fetal ventriculomegaly. It can better demonstrate other associated CNS anomalies. It moreover adds additional information about cortical maturation and sulcation which is difficult to be appreciated on ultrasound. Moreover the sulcation is appreciated on MRI at an earlier stage. The information provided by MRI will definitely be helpful in determining the outcome of

the fetus with ventriculomegaly. MRI features can be helpful in counselling the parents and help them decide to undergo further tests like amniocentesis and karyotyping. A comprehensive workup of the patients with fetal ventriculomegaly which may include targeted ultrasound, Antenatal MR, fetal echocardiography, amniocentesis with karyotyping and postnatal imaging and neurodevelopmental follow up all are essential in comprehensive management of fetal ventriculomegaly.<sup>[20]</sup>

## CONCLUSION

MRI is an indispensable imaging modality for diagnosis and evaluation of fetal ventriculomegaly. It can reliably demonstrate additional abnormalities of fetal brain. Role of MRI for diagnosis, prognosis and management of fetal ventriculomegaly cannot be overemphasized.

## REFERENCES

- Parilla BV, Endres LK, Dinsmoor MJ, Curran L. In utero progression of mild fetal ventriculomegaly. *Int J Gynaecol Obstet.* 2006 May;93(2):106-9. Epub 2006 Mar 20.
- Pilu G, Perolo A, Falco P, Visentin A, Gabrielli S, Bovicelli L. Ultrasound of the fetal central nervous system. *Current opinion in obstetrics & gynecology.* 2000;12:93-103.
- Valat AS, Dehouck MB, Dufour P, Dubos JP, Djebara AE, Dewismes L, Robert Y, Puech F. [Fetal cerebral ventriculomegaly. Etiology and outcome, report of 141 cases]. *J Gynecol Obstet Biol Reprod (Paris).* 1998 Dec;27(8):782-9.
- Farrell SA. Down syndrome and fetal ventriculomegaly. *Prenat Diagn.* 1994 Jul;14(7):647-9.
- Kazan-Tannus JF, Dialani V, Chiang G, Feldman HA, Brown J, Levine D. Brain volumetry in fetuses referred for ventriculomegaly. *AJR American journal of roentgenology.* 2007;189(1):145-151.
- Saleem SN. Fetal MRI: An approach to practice: A review. *Journal of Advanced Research.* 2014;5(5):507-523.
- Glenn OA. MR imaging of the fetal brain. *Pediatric Radiology.* 2010;40(1):68-81.
- Cardoen L, De Catte L, Demaerel P, et al. The role of magnetic resonance imaging in the diagnostic work-up of fetal ventriculomegaly. *Facts, Views & Vision in ObGyn.* 2011;3(3):159-163.
- Sefidbakht S, Dehghani S, Safari M, Vafaei H, Kasraeian M. Fetal Central Nervous System Anomalies Detected by Magnetic Resonance Imaging: A Two-Year Experience. *Iranian Journal of Pediatrics.* 2016;26(4):e4589.
- Morioka T, Hashiguchi K, Nagata S, Miyagi Y, Mihara F, Hikino S, Tsukimori K, Sasaki T. Fetal germinal matrix and intraventricular hemorrhage. *Pediatr Neurosurg.* 2006;42(6):354-61.
- Elchalal U, Yagel S, Gomori JM, Porat S, Beni-Adani L, Yanai N, Nadjari M. Fetal intracranial hemorrhage (fetal stroke): does grade matter? *Ultrasound Obstet Gynecol.* 2005 Sep;26(3):233-43.
- Santo S, D'Antonio F, Homfray T, Rich P, Pilu G, Bhide A, Thilaganathan B, Papageorgiou AT. Counseling in fetal medicine: agenesis of the corpus callosum. *Ultrasound Obstet Gynecol.* 2012 Nov;40(5):513-21.
- Glenn OA, Cuneo AA, Barkovich AJ, Hashemi Z, Bartha AI, Xu D. Malformations of Cortical Development: Diagnostic Accuracy of Fetal MR Imaging. *Radiology.* 2012;263(3):843-855.
- Pretorius DH, Drose JA, Manco-Johnson ML. Fetal lateral ventricular ratio determination during the second trimester. *J Ultrasound Med.* 1986 Mar;5(3):121-4.
- Manegold-Brauer G, Oseledchik A, Floeck A, Berg C, Gembruch U, Geipel A. Approach to the sonographic evaluation of fetal ventriculomegaly at 11 to 14 weeks gestation. *BMC Pregnancy and Childbirth.* 2016;16:3. doi:10.1186/s12884-016-0797-z.
- Kandula T, Fahey M, Chalmers R, Edwards A, Shekleton P, Teoh M, Clark J, Goergen SK. Isolated ventriculomegaly on prenatal ultrasound: what does fetal MRI add? *J Med Imaging Radiat Oncol.* 2015 Apr;59(2):154-62.
- Gaglioti P, Danelon D, Bontempo S, Mombrò M, Cardaropoli S, Todros T. Fetal cerebral ventriculomegaly: outcome in 176 cases. *Ultrasound Obstet Gynecol.* 2005 Apr;25(4):372-7.
- Malinger G, Ben-Sira L, Lev D, Ben-Aroya Z, Kidron D, Lerman-Sagie T. Fetal brain imaging: a comparison between magnetic resonance imaging and dedicated neurosonography. *Ultrasound Obstet Gynecol.* 2004 Apr;23(4):333-40.
- Gilmore JH, van Tol JJ, Lewis Streicher H, Williamson K, Cohen SB, Greenwood RS, Charles HC, Kliewer MA, Whitt JK, Silva SG, Hertzberg BS, Chescheir NC. Outcome in children with fetal mild ventriculomegaly: a case series. *Schizophr Res.* 2001 Mar 30;48(2-3):219-26.
- Rosseau GL, McCullough DC, Joseph AL. Current prognosis in fetal ventriculomegaly. *J Neurosurg.* 1992 Oct;77(4):551-5

**How to cite this article:** Bhosale P, Kachare MB. Role Of Magnetic Resonance Imaging in Fetal Ventriculomegaly. *Ann. Int. Med. Den. Res.* 2017; 3(5):RD16-RD20.

**Source of Support:** Nil, **Conflict of Interest:** None declared