

# Role of Imaging in the Evaluation of Non-Palpable Testes: A Rare Case of Ectopic and Undescended Testes in an Adult.

Reddy Ravikanth<sup>1</sup>, Partha Sarathi Sarkar<sup>2</sup>, Rakesh CA<sup>2</sup>, Babu Philip<sup>3</sup>

<sup>1</sup>Post-graduate student, Dept. Of Radiology, St. John's Medical College, Bangalore – 560034.

<sup>2</sup>Senior Resident, Dept. Of Radiology, St. John's Medical College, Bangalore – 560034.

<sup>3</sup>Professor, Dept. Of Radiology, St. John's Medical College, Bangalore – 560034.

Received: January 2017

Accepted: January 2017

**Copyright:** © the author(s), publisher. It is an open-access article distributed under the terms of the Creative Commons Attribution Non-Commercial License, which permits unrestricted non-commercial use, distribution, and reproduction in any medium, provided the original work is properly cited.

## ABSTRACT

Undescended testis is one of the most common pediatric disorder of the male endocrine glands and the most common genital disorder identified at birth. The undescended testis may be palpable or non-palpable. Approximately 20% of undescended testis are non-palpable and either located in the abdomen or the canaliculi, or atrophic or are completely absent. Identifying the location of ectopic and undescended testes can aid in presurgical planning and help determine the optimal type of surgical correction procedure to be performed. Ultrasound and MRI are the most common imaging exams ordered to detect and locate these two variants. Testicular tissue at ectopic site was identified by presence of characteristic signal intensity pattern, mediastinum testis and its location along empty spermatic canal in cases of inguinal testis either singly or in combination. We conclude that MR imaging is useful in the localization and tissue characterization of non-palpable testes.

**Keywords:** non-palpable testes, ectopic, undescended, imaging.

## INTRODUCTION

The incidence of clinically impalpable testes is approximately 20% of an undescended testis population.<sup>[1]</sup> Testes are impalpable when they are intra-canalicular or intra-abdominal and never emerge through the external inguinal ring, or when they are atrophic, dysgenetic or absent.<sup>[2]</sup> The intra-abdominal testis usually poses a diagnostic and therapeutic problem. Although ultrasound remains the mainstay of scrotal imaging, MR imaging can provide additional useful information in approximately 80% of the cases where ultrasound findings are indeterminate.<sup>[3]</sup>

### Name & Address of Corresponding Author

Dr. Partha Sarathi Sarkar,  
Senior Resident, Dept. of Radiology  
St. John's Medical College, Bangalore – 560034.

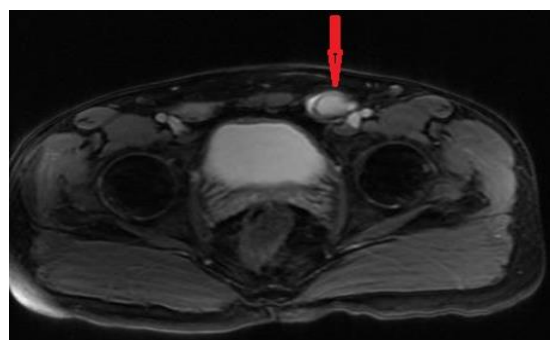
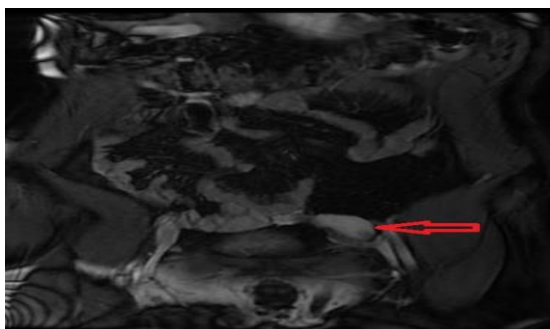
Early diagnosis and management of the undescended testicle are needed to preserve fertility and improve early detection of testicular malignancy. Physical examination of the testicle can be difficult; consultation should be considered if a normal testis cannot be definitely identified. Observation is not recommended beyond one year of age because it delays treatment, lowers the rate of surgical success and probably impairs spermatogenesis.<sup>[4]</sup> By six

months of age, patients with undescended testicles should be evaluated by a pediatric urologist or other qualified subspecialist who can assist with diagnosis and treatment. Earlier referral may be warranted for bilateral non-palpable testes in the newborn or for any child with both hypospadias and an undescended testis. Therapy for an undescended testicle should begin between six months and two years of age and may consist of hormone or surgical treatment.<sup>[5]</sup> The success of either form of treatment depends on the position of the testicle at diagnosis. Recent improvements in surgical technique, including laparoscopic approaches to diagnosis and treatment, hold the promise of improved outcomes. While orchiopexy may not protect patients from developing testicular malignancy, the procedure allows for earlier detection through self examination of the testicles.<sup>[6]</sup> Here, we describe a rare case of ectopic and undescended testes in an adult.

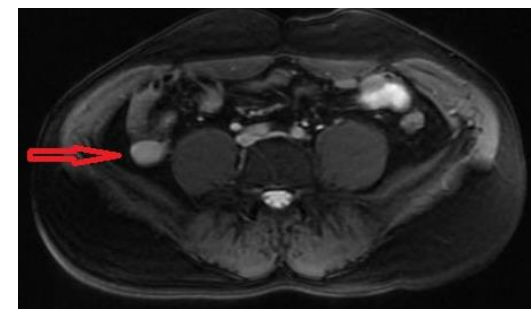
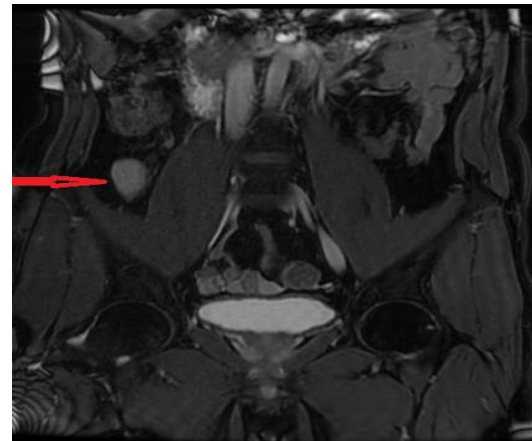
## CASE REPORT

A 33 year old male patient presented with complaints of non-visualization of bilateral testes. Left and right hemiscrotum was empty with no palpable testes in bilateral inguinal regions. Pre-operative pelvis ultrasonography and MRI of the abdomen and pelvis were done to rule out Mullerian

duct remnants and other anomalies. Ultrasonography revealed a hypoechoic ovoid structure at the left deep inguinal ring which was identified as testis. However, the right testis could not be localized. Subsequently patient was referred for MRI scan. MRI showed a well defined T2 hyperintense and T1 hypointense ovoid structure with a T2 hypointense tunica vaginalis surrounding it, identified to be the testis at the deep inguinal ring on the left. T2 hypointense ligament was noted to bridge the undescended testis with the left hemiscrotum which was identified as the gubernaculum. Another similar intensity structure was identified in the right lumbar region classified as the high intra-abdominal location. Gubernaculum remnant was noted to bridge the right testis and the right hemiscrotum. Both testis were noted to show true diffusion restriction with post-contrast enhancement. We used conventional MRI for anatomic localization of hyperintense elliptic areas on the DW images. On conventional MRI, elliptic areas that appear hypo/isointense on T1WI and hyperintense on T2WI were reported as testes. For localization we followed the scheme used by Kantarci et al. in which undescended testes were classified into three anatomic regions: intra-canalicular, low intra-abdominal, and high intra-abdominal. Testes close to and below the inguinal ring were considered intra-canalicular, testes above and close to the internal ring were classified as having a low intra-abdominal location around the iliac vessels, testes more than 3 cm from the internal ring were classified as high intra-abdominal location. MRI showed no pelvic or renal anomalies.



**Figure 1a and 1b: MR 2D FIESTA coronal and axial images demonstrating the left undescended testis at the deep inguinal ring.**



**Figure 2a and 2b: MR 2D FIESTA coronal and axial images demonstrating the right ectopic testis in the right lumbar region.**

## DISCUSSION

Testicular development and descent from abdomen to scrotum is a complex and multistage process which starts from 7th to 35th week of gestation.<sup>[7]</sup> Normally, the testis follows the course of scrotal extension of gubernaculum, but occasionally, it follows one of the other tails of the gubernaculum to an ectopic location in the perineum, suprapubic, femoral or contralateral hemiscrotal areas. Normal migration of the testis is thought to be under the influence of androgenic hormones and certain mechanical factors, any disturbance in this process leads to maldescent that could be in its normal pathway (true undescended testis) or an abnormal pathway (ectopic testis).<sup>[8]</sup> The cause of testicular ectopia is unknown but it is thought to be due to abnormal position of genito-femoral nerve which leads to an abnormal migration of gubernaculum and thus takes testis to abnormal position.<sup>[9]</sup> When the testis is not found in its normal anatomical location, it can either be palpable elsewhere or nonpalpable. When palpated outside the scrotum, the testis may be cryptorchoid, ectopic or retractile, while a nonpalpable testis may be cryptorchoid, atrophic or absent.<sup>[10]</sup> Cryptorchidism occurs when the testis fails to descend into its normal postnatal location and may be found in the abdomen, in the inguinal region, or at the external ring (prescrotal). The ectopic location of the testes are associated with a number of complications like

trauma, torsion and infertility (in cases of bilateral cases).<sup>[11]</sup>

Undescended testis or cryptorchidism, a condition in which one or both testicles are not appropriately positioned in the scrotum at birth. It is the most common congenital genitourinary anomaly in boys and has an incidence of 1–3% in term and 15–30% in premature male infants.<sup>[12]</sup> The etiology of cryptorchidism is not well understood. The undescended testicles may be palpable or non-palpable, approximately 20% of undescended testes are non-palpable and either located in the abdomen or the canaliculi, or atrophic or are completely absent.<sup>[11]</sup> Cryptorchidism is associated with impaired fertility, inguinal hernia, and increased risk of testis cancer. Proper diagnosis and localization of undescended testis is essential for appropriate management which may include watchful waiting, hormonal treatment, or surgery.<sup>[13]</sup> Accurate pre-surgical diagnosis of an absent testis would spare a child an operation, and correct localization of a testis could limit the extent of surgery and anesthesia time. At present, ultrasonography (US) and magnetic resonance imaging (MRI) are used for diagnosing a non-palpable testis, because they are basically non-invasive, and do not involve ionizing radiation.<sup>[14]</sup> MRI also yields excellent soft tissue contrast even on unenhanced images. The accuracy rates of diagnosis and localization of a non-palpable testis with MRI (85%) and ultrasound (84%) are nearly equally with no statistically significant differences.<sup>[15]</sup> Diagnostic laparoscopy has been established as the most reliable diagnostic technique for localizing non-palpable testes with nearly 100% sensitivity and specificity.<sup>[16]</sup> However, it is an invasive technique.

Many syndromes may be associated with cryptorchidism, namely, Prune belly, Noonan, Prader -Willi, Kallman's, Lawrence Moon-Biedel and Arthrogyposis Multiplex Congenita.<sup>[17]</sup> The genitalia should be examined for evidence of hypospadias or ambiguity. Hypospadias and undescended testes are commonly associated with a state of intersexuality especially "mixed gonadal dysgenesis" and "true hermaphroditism."<sup>[18]</sup> Preoperative awareness of the testicular position in cases of non-palpable undescended testis is valuable for planning surgical strategy, facilitating the placement of the surgical incision, as well as the choice of operative technique, especially when performing laparoscopic orchiopexy and in the first step of the Fowler–Stephens maneuver in cases of intra-abdominal gonads.

Ultrasound is the examination of choice for locating an undescended testis, since most will be located in the inguinal canal. A testis higher in the pelvis or in the retroperitoneum may be difficult to identify sonographically, and CT or MR may be necessary to identify the testis. Adesanya et al.<sup>[19]</sup> found that ultrasonography is more accurate (86.5%) than clinical examination in the preoperative localization

of undescended testes in children, this is true for intra-canalicular testis, however ultrasonography cannot reliably localize abdominal testis or atrophic testis. Conventional MRI is moderately specific in identifying absent testicles but poorly sensitive in identifying the presence of non-palpable testicles. MRI is less efficient in locating intra-abdominal functioning testicles and performs modestly well in locating those in inguino-scrotal regions, but it fails to locate most of the atrophied testicles, which makes MRI a less reliable technique in providing guidance to differentiate those children needing surgery from those who do not.<sup>[20]</sup> In a 2013 meta-analysis study, Krishnaswami et al.<sup>[21]</sup> reported that MRI correctly identified non-palpable cryptorchid testicles with a median sensitivity of 62%. MRI located intra-abdominal testicles with a sensitivity of 55% and inguino-scrotal testicles with a sensitivity of 86%.

## CONCLUSION

Muscular lesions of cystic echinococcosis are rare even in endemic areas. Several patterns of disease have been recognized using various imaging techniques. However, echinococcosis should be always suspected in the differential diagnosis of cystic lesions in soft tissues. Once the diagnosis is established, the surgeon should consider performing a radical procedure aiming in minimizing the possibility of recurrence.

## REFERENCES

1. John Radcliffe Hospital Cryptorchidism Study Group. Cryptorchidism: a prospective study of 7500 consecutive male births, 1984–8. *Arch Dis Child.* 1992; 67:892–9.
2. Williams EV, Appanna T, Foster ME. Management of the impalpable testis: a six year review together with a national experience. *Postgrad Med J.* 2001; 77:320–2.
3. Kato T, Kojima Y, Kamisawa H, Takeuchi M, Mizuno K. Findings of fat-suppressed T2-weighted and diffusion-weighted magnetic resonance imaging in the diagnosis of non-palpable testes. *BJU Int.* 2010;107:290–4.
4. Gatti JM, Ostlie DJ. The use of laparoscopy in the management of non-palpable undescended testes. *Curr Opin Pediatr.* 2007; 19:349–353.
5. Schneck FX, Bellinger MF. Abnormalities of the testes and scrotum and their surgical management. In Wein AJ, Kavoussi LR, Novick AC, Partin AW, Peters CA eds. *Campbell-Walsh Urology*, 9th edn, Vol. IV. Chapt 127. Philadelphia: Saunders Company. 2007; 3761–98.
6. Argos Rodriguez MD, Unda Freire A, Ruiz Orpez A, Garcia Lorenzo C. Diagnostic and therapeutic laparoscopy for nonpalpable testis. *Surg Endosc.* 2003; 17:1756–1758.
7. Berkowitz GS, Lapinski RH, Dolgin SE, Gazella JG, Bodian CA, Holzman IR. Prevalence and natural history of cryptorchidism. *Pediatrics.* 1993; 92(1):44–49.
8. Smolko MJ, Kaplan GW, Brock WA. Location and fate of the non-palpable testis in children. *Journal of Urology.* 2007; 14: 616-21.
9. Barthold JS. Abnormalities of the testis and scrotum and their surgical management. In: Wein AJ, Kavoussi LR, Novick AC,

- et al. eds. Campbell-Walsh Urology. 10th ed. Philadelphia, PA: Saunders Elsevier. 2011:3557-95.
10. Gapany C, Frey P, Cachat F, et al. Management of cryptorchidism in children: guidelines. *Swiss Med Wkly*. 2008; 138:492-8.
  11. Tasian GE, Hittelman AB, Kim GE, et al. Age at orchiopexy and testis palpability predicts germ and Leydig cell loss: clinical predictors of adverse histological features of cryptorchidism. *J Urol*. 2009; 182: 704-9.
  12. Sijstermans K, Hack WW, Meijer RW, et al. The frequency of undescended testis from birth to adulthood: a review. *Int J Androl*. 2008;31:1-11.
  13. Lotan G, Klin B, Efrati Y, et al. Laparoscopic evaluation and management of nonpalpable testis in children. *World J Surg*. 2001; 25:1542-5.
  14. Siemer S, Humke U, Uder M, Hildebrandt U, Karadiakos N, Ziegler M. Diagnosis of nonpalpable testes in childhood: comparison of magnetic resonance imaging and laparoscopy in a prospective study. *Eur J Pediatr Surg*. 2000;10(2):114–118.
  15. Kanemoto K, Hayashi Y, Kojima Y, Maruyama T, Ito M, Kohri K. Accuracy of ultrasonography and magnetic resonance imaging in the diagnosis of non-palpable testis. *Int J Urol*. 2005; 12(7):668–672.
  16. Al-Shareef ZH, Al-Shlash S, Koneru SR, TowuE, Al-Dhohayan A, Al-Brekett K. Laparoscopic orchidopexy: one-stage alternative for nonpalpable testes. *Ann R Coll Surg Engl*. 1996; 78(2):115–118.
  17. Elder JS. Ultrasonography is unnecessary in evaluating boys with a nonpalpable testis. *Pediatrics*. 2002; 110: 748-51.
  18. Nakhla et al, Evaluation of Retained Testes in Adolescent Girls and Women with Complete Androgen Insensitivity Syndrome. *Radiology*: Vol 268: No. 1- July 2013.
  19. Adesanya OA, Ademuyiwa AO, Evbuomwan O, Adeyomoye AA, Bode CO. Preoperative localization of undescended testes in children: comparison of clinical examination and ultrasonography. *J Pediatr Urol*. 2014;10:237–40.
  20. Maghnie M, Vanzulli A, Paesano P, et al. The accuracy of magnetic resonance imaging and ultrasonography compared with surgical findings in the localization of the undescended testis. *Arch Pediatr Adolesc Med*. 1994;148:699-703.
  21. Krishnaswami S, Fannesbeck C, Penson D, McPheeters ML. Magnetic resonance imaging for locating nonpalpable undescended testicles: a meta-analysis. *Pediatrics*. 2013; 131: e1908–16.

**How to cite this article:** Ravikanth R, Sarkar PS, Rakesh CA, Philip B. Role of Imaging in the Evaluation of Non-Palpable Testes: A Rare Case of Ectopic and Undescended Testes in an Adult. *Ann. Int. Med. Den. Res*. 2017; 3(2): RD10-RD13.

**Source of Support:** Nil, **Conflict of Interest:** None declared