

Imaging of Primary Hydatid of the Psoas Muscle.

Reddy Ravikanth¹, Partha Sarathi Sarkar², Nidhi Kumar², Babu Philip³

¹Post-graduate student, Dept. Of Radiology, St. John's Medical College, Bangalore – 560034.

²Senior Resident, Dept. Of Radiology, St. John's Medical College, Bangalore – 560034.

³Professor, Dept. Of Radiology, St. John's Medical College, Bangalore – 560034.

Received: January 2017

Accepted: January 2017

Copyright: © the author(s), publisher. It is an open-access article distributed under the terms of the Creative Commons Attribution Non-Commercial License, which permits unrestricted non-commercial use, distribution, and reproduction in any medium, provided the original work is properly cited.

ABSTRACT

Hydatid cyst is a cosmopolitan parasitic infection that constitutes a problem of public health in developing countries. The incidence of unusual site is about 8-10%. The psoas muscle is an uncommon location for hydatid cyst accounting for only 1-3 % of cases. The clinical picture depends upon the involved organs, its effects on adjacent structures, complications due to secondary infection, rupture and anaphylaxis caused by hydatid cysts. We report a rare case of hydatid cyst of the psoas muscle in a 44 year old gentleman excised via extra-peritoneal approach.

Keywords: atypical location, hydatid, psoas muscle, echinococcus, extraperitoneal approach.

INTRODUCTION

The hydatid cyst is a parasitosis due to the development of the embryonic shape of echinococcus granulosus.^[1] The usual host is the dog, the man being the intermediate host. The localizations at the man are varied, single or multiple, isolated or associated. The liver and lungs are the organs most frequently affected.^[2] The muscular hydatidosis is a rare affection and the infringement of the psoas countered exceptional, even in country of endemic disease. The rarity of this localization and its clinical polymorphism makes the interest of this study.

Name & Address of Corresponding Author

Dr. Partha Sarathi Sarkar,
Senior Resident, Dept. of Radiology
St. John's Medical College, Bangalore – 560034.

CASE REPORT

A 44 year old gentleman presented with pain in the left lower quadrant of the abdomen of 2 months duration. There was no history of trauma or fever. General physical examination was unremarkable. Abdominal examination on deep palpation revealed a swelling which was firm, non-tender, globular non-compressible with negative cough impulse in the left lower abdomen. Ultrasonography abdomen revealed a cystic multiloculated swelling arising from the left psoas muscle with absent vascularity on color Doppler [Figure 1] and pulsed wave Doppler imaging [Figure 2]. Abdomino-pelvic CT scan showed a cystic swelling measuring 4.5 x 6.6 x 5.4

cm arising from the left psoas muscle and was suggestive of a hydatid cyst [Figure 3]. There was no other evidence of hydatid disease on computed tomography of abdomen and chest. Hydatid serology was negative. By extraperitoneal approach via left iliac fossa region, total cystectomy was done. Post-operative period was uneventful. Patient was discharged with four weeks on albendazole therapy with no recurrence seen in follow-up.

DISCUSSION

Isolated retroperitoneal location of hydatid cyst has been reported to be very exceptional, even in endemic areas. Location in the muscular tissue accounts for 2-3% of all cases in the body. Psoas muscle is an unusual location for hydatid cyst accounting for only 1-3% of cases and can be unilateral or bilateral.^[3] Hydatid of the psoas muscle can be isolated or associated with hydatid disease elsewhere in the body. Hydatid disease in the muscle progresses slowly and is rarely life threatening. Because of location, hydatid of psoas muscle may remain asymptomatic or may present with pain or obstructive symptoms of the ureter.^[4] Hydatid serology in confirming diagnosis is often seen negative.

A high suspicion of clinical index is prime in suspecting hydatid psoas in endemic areas.^[5] Ultrasonography, computed tomography and the magnetic resonance imaging delineating soft tissue extent are sufficient for diagnosis. Psoas abscess, retroperitoneal cystic tumours and tuberculosis are common differential diagnosis.^[6] Intramuscular infestation may mimic a soft tissue tumor leading to

inappropriate cyst rupture with the attendant risks of anaphylaxis and dissemination to other organs, so a preoperative correct diagnosis is important.

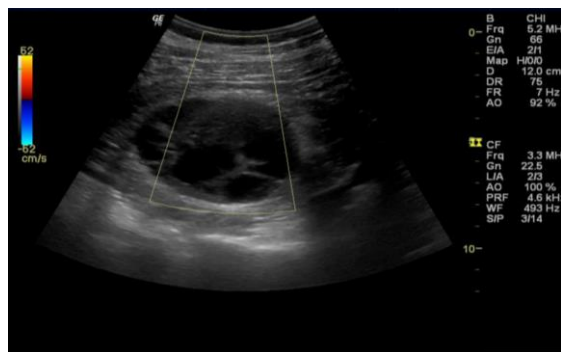


Figure 1: Multiseptated appearance of the hydatid cyst with absent color uptake on color Doppler imaging.

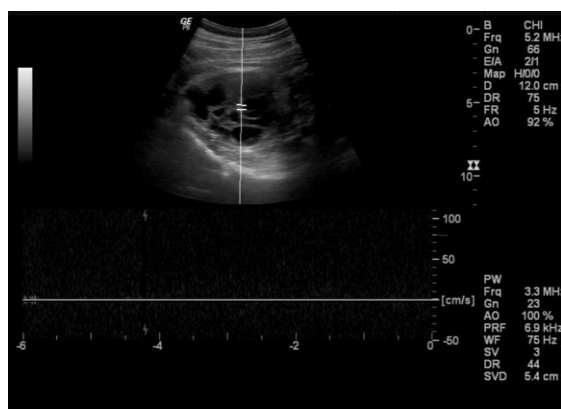


Figure 2: Hydatid cyst displaying absent vascularity on pulsed wave Doppler imaging.

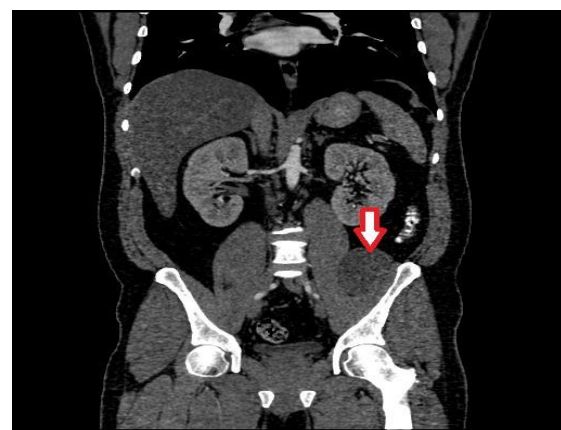


Figure 3: Coronal CT image of the abdomen-pelvis demonstrating hydatid cyst of the left psoas muscle.

Preoperatively percutaneous aspiration drainage and the medical therapy are done to reduce the size of the cyst. In order to prevent intraperitoneal dissemination of cyst, extraperitoneal approach is preferred.^[7] Treatment involves partial cystectomy or the total cystectomy depending on the muscular extent of disease

CONCLUSION

Muscular lesions of cystic echinococcosis are rare even in endemic areas. Several patterns of disease have been recognized using various imaging techniques. However, echinococcosis should be always suspected in the differential diagnosis of cystic lesions in soft tissues. Once the diagnosis is established, the surgeon should consider performing a radical procedure aiming in minimizing the possibility of recurrence.

REFERENCES

1. Junghans T, da Silva AM, Horton J, Chiodini PL, Brunetti E. Clinical management of cystic echinococcosis: state of the art, problems, and perspectives. *Am J Trop Med Hyg.* 2008; 79 (3): 301-11. [Medline].
2. WHO Informal Working Group. International classification of ultrasound images in cystic echinococcosis for application in clinical and field epidemiological settings. *Acta Trop.* 2003; 85(2):253-61. [Medline].
3. Kouskos E, Chatziantoniou J, Chrissafis I, Anitsakis C, Zamtrakis S. Uncommon locations of hydatid cysts. *Singapore Med J.* 2007;48:119-21.
4. Pedrosa I, Saíz A, Arrazola J, Ferreirós J, Pedrosa CS. Hydatid disease: Radiologic and pathologic features and complications. *Radiographics.* 2000;20:795-817.
5. Eckert J, Deplazes P. Biological, epidemiological, and clinical aspects of echinococcosis, a zoonosis of increasing concern. *Clin Microbiol Rev.* 2004;17:107-35.
6. Pedrosa I, Saiz A, Arrozo I, Ferreirós J, Pedrosa CS. Hydatid disease: Radiologic and pathologic features and complications. *Radiographics.* 2000;20:795-817.
7. Hatipoglu AR, Coşkun I, Karakaya K, Ibis C. Retroperitoneal localization of hydatid cyst disease. *Hepatogastroenterology.* 2001; 48:1037-9. [PubMed: 11490794]

How to cite this article: Ravikanth R, Sarkar PS, Kumar N, Philip B. Imaging of Primary Hydatid of the Psoas Muscle. *Ann. Int. Med. Den. Res.* 2017; 3(2):RD08-RD09.

Source of Support: Nil, **Conflict of Interest:** None declared