

A Case of Ovarian Tumor.

Vallabh Lathiya¹, Rajesh Kumar Chaurasia², Sukhdev Singhvi³, Rajesh Arora¹, Rohan Talokar⁴, Aiman Khursheed⁴

¹Senior resident, Department of Radiology, K.D. Medical College Hospital & Research Center, Mathura, U.P.-281406, India.

²Professor, Department of Radiology, K.D. Medical College Hospital & Research Center, Mathura, U.P.-281406, India.

³Associate Professor, Department of Radiology, K.D. Medical College Hospital & Research Center, Mathura, U.P.-281406, India.

⁴Sonologist, Department of Radiology, K.D. Medical College Hospital & Research Center, Mathura, U.P.-281406, India.

Received: March 2017

Accepted: April 2017

Copyright: © the author(s), publisher. It is an open-access article distributed under the terms of the Creative Commons Attribution Non-Commercial License, which permits unrestricted non-commercial use, distribution, and reproduction in any medium, provided the original work is properly cited.

ABSTRACT

Ovarian cystadenoma is a type of benign ovarian epithelial tumour. We performed this study to determine the imaging characteristics of this tumor.

Keywords: Ovarian cystadenoma, sonography.

INTRODUCTION

Ovarian cystadenoma is a commonest type of ovarian epithelial neoplasm. Serous cystadenomas account for about 60% of ovarian serous tumours.^[1] Predominantly they occur in premenopausal women, peak incidence is at the 4th to 5th decades of life. In addition, upon encountering a mass with these imaging characteristics in the proper clinical setting, serum CA-125 levels should be measured to help make a presurgical diagnosis and to obtain a baseline value.

Name & Address of Corresponding Author

Dr. Vallabh Lathiya
Department of Radiology,
K.D. Medical College Hospital & Research Center, Mathura,
U.P.-281406, India.

CASE REPORT

A 45years old female (gravida 3, para 3) presented to a gynaecology OPD. With complaints of dull aching abdominal pain for 4 months, which was associated with poor appetite & menstrual irregularity. Her last menstrual period was 4 weeks ago. Physical examination revealed a large abdominal soft, mobile mass.

Abdominal ultrasound show a huge abdominal multilocular cystic mass, few thick & thin walled septations, displacing the visceral organs. Ovaries could not be separately identified, suggesting a possible ovarian origin. Loculations contain low level internal echogenicity & few of the loculations contain papillary projections. No calcifications or

internal vascularity seen on Doppler study. There was no free fluid in peritoneal cavity.

- Our differential diagnosis included serous cystadenocarcinoma.
- Because of serum CA-125 level was not elevated ovarian cystoadenocarcinoma was ruled out.

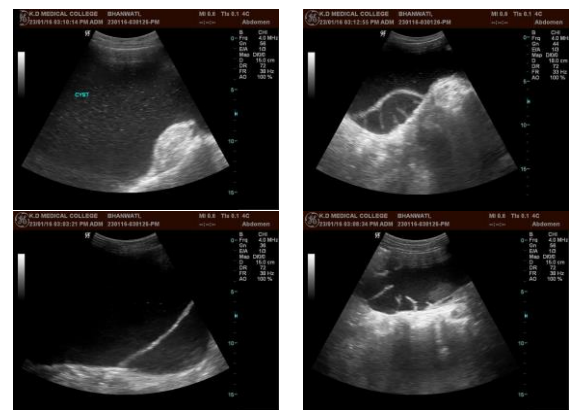


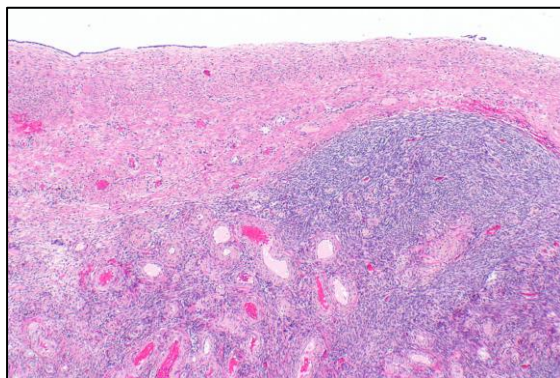
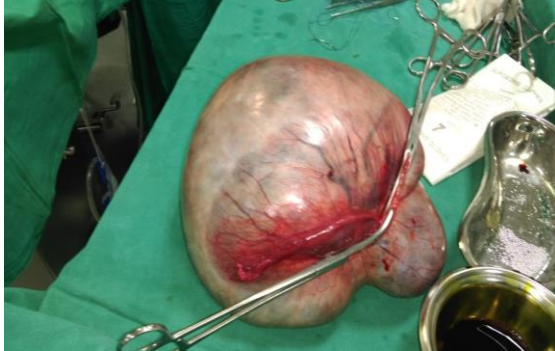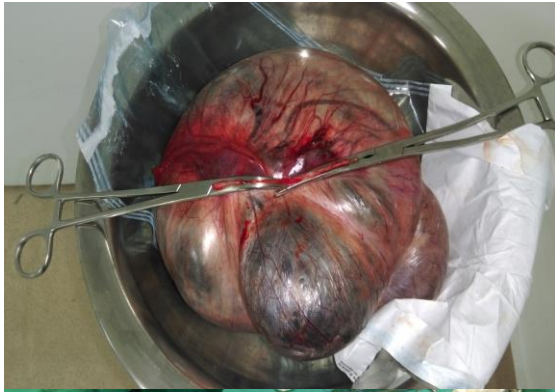Figure 1: Transabdominal USG. & Color Doppler shows a complex cystic mass with multiple septa, no intralesional vascularity.

Pathological findings

Gross pathology- Grossly, they are, unilocular cyst that contain clear, straw-coloured fluid, in this case it was multilocular. Weight 4.2kgs.

Histopathology

Microscopically, the cyst lining consists of a simple epithelium with cilia that may be columnar or flat. Ovarian serous cystadenoma.^[3] The cystic space is at the top of the image. Ovarian parenchyma is seen at the bottom right



DISCUSSION

Ovarian cystadenoma is commonest benign neoplasm containing epithelial line and fibrous septae accounting for 25-30% of all benign ovarian tumors. Serous cystadenocarcinomas account for about 50% of all malignant ovarian neoplasms. The peak incidence of serous cystadenomas is in the fourth and fifth decades, whereas serous cystadenocarcinomas most frequently occur in perimenopausal and postmenopausal women. These tumors can be predominantly cystic, unilocular may multilocular with no solid components. Calcifications is usually not seen. Even on gross examination at the time of surgery, a cystadenoma may resemble a benign tumor.

Sonographically, serous cystadenomas are usually large, thin-walled, unilocular cystic mass that may contain thin septations. Papillary projections are occasionally seen.^[2] Serous cystadenocarcinomas may be quite large and usually present as multilocular cystic masses containing multiple

papillary projections arising from the cyst walls and septa. The septa and wall may be thick. Echogenic solid material may be seen within the loculations. Papillary projections may form on the surface of the cyst and surrounding organs, resulting in fixation of the mass. Ascites is frequently seen.

Mucinous cystadenomas generally tend to be larger than serous cystadenomas at presentation.^[1] Bilaterality is rare (2-5%). Mural calcification is more common than serous tumours.^[4] On USG- typically large cystic adnexal mass, multilocular with numerous thin septations, loculations may contain low-level internal echogenicity due to increased mucin content, different locules may contain different degrees of echogenicity. Cystadenofibroma may occur in reproductive age group and an accurate preoperative diagnosis may help in avoiding extensive surgical procedure. On USG. A cystadenoma show a unilocular or a multiloculated cystic mass, with serous contain or papillary projections. Vascularisation can be present in just under 50 % of cases with typical pattern of peripheral vascularisation with scattered vessels of high blood flow impedance. USG:. Cannot definitely characterize this tumor as its heterogenous appearance mimics a malignant ovarian neoplasm. A computed tomography (CT) scan has value in evaluating adhesion.

REFERENCES

1. Jung SE, Lee JM, Rha SE et-al. CT and MR imaging of ovarian tumors with emphasis on differential diagnosis. *Radiographics*. 22 (6): 1305-25. doi:10.1148/rg.226025033 - Pubmed citation
2. Hassen K, Ghossain MA, Rousset P et-al. Characterization of papillary projections in benign versus borderline and malignant ovarian masses on conventional and color Doppler ultrasound. *AJR Am J Roentgenol*. 2011;196 (6): 1444-9. doi:10.2214/AJR.10.5014 - Pubmed citation
3. Cheng, EJ.; Kurman, RJ.; Wang, M.; Oldt, R.; Wang, BG.; Berman, DM.; Shih, IeM. (Jun 2004). "Molecular genetic analysis of ovarian serous cystadenomas.". *Lab Invest* 84 (6): 778-84. doi:10.1038/labinvest.3700103.PMID 15077125.
4. Okada S, Ohaki Y, Inoue K et-al. Calcifications in mucinous and serous cystic ovarian tumors. *J Nippon Med Sch*. 2005;72 (1): 29-33. Pubmed citation.

How to cite this article: Lathiya V, Chaurasia RK, Singhvi S, Arora R, Talokar R, Khursheed A. A Case of Ovarian Tumor. *Ann. Int. Med. Den. Res*. 2017; 3(3):RD04-RD05.

Source of Support: Nil, **Conflict of Interest:** None declared