

# Spontaneous Pneumothorax as the Initial Presentation in an Osteosarcoma Patient: A Case Report.

Laxmi Sankar Kumar<sup>1</sup>, Pradosh Kumar Sarangi<sup>1</sup>, Jayashree Mohanty<sup>2</sup>, Sasmita Parida<sup>3</sup>

<sup>1</sup>Junior resident, Department of Radiodiagnosis, SCB medical college & Hospital, Cuttack, Odisha, India.

<sup>2</sup>Professor & HOD, Department of Radiodiagnosis, SCB medical college & Hospital, Cuttack, Odisha, India.

<sup>3</sup>Associate professor, Department of Radiodiagnosis, SCB medical college & Hospital, Cuttack, Odisha, India.

Received: December 2016

Accepted: December 2016

**Copyright:** © the author(s), publisher. It is an open-access article distributed under the terms of the Creative Commons Attribution Non-Commercial License, which permits unrestricted non-commercial use, distribution, and reproduction in any medium, provided the original work is properly cited.

## ABSTRACT

Spontaneous pneumothorax (SP) is a very rare condition, mainly seen in patients with underlying lung diseases. Pneumothorax caused by lung metastasis occurs in 1% of whole spontaneous pneumothorax cases, especially in the setting of cytotoxic chemotherapy or radiotherapy. The most frequently involved tumor is osteogenic sarcoma. But, before initiation of chemotherapy, spontaneous pneumothorax as a complication of malignancy is rare. Herein, we report a case of spontaneous pneumothorax in a 19-year-old female with osteosarcoma of left ilium. The patient was not receiving chemotherapy or radiotherapy and was found to have pneumothorax at the initial presentation, which is rare. Chest CT revealed bilateral pulmonary metastases and right sided pneumothorax.

**Keywords:** Spontaneous pneumothorax, Pulmonary metastases, Osteosarcoma, Multiple random nodules, Chemotherapy.

## INTRODUCTION

Spontaneous pneumothorax (SP) can be encountered with various lung tumors: primary tumors, metastasis, lymphangitis carcinomatosa. Only about 1% of SP are due to lung metastasis.<sup>[1]</sup> Approximately 80% of secondary spontaneous pneumothorax cases are associated with metastatic osteogenic sarcoma. It occurs after initiation of chemotherapy or radiotherapy due to necrosis of subpleural metastases.<sup>[2-4]</sup> Pneumothorax decreases the quality of life and increases the risk of mortality in osteosarcoma patients. Only less than 10% of osteosarcoma patients with SP survive for >2 years following the initial diagnosis of pneumothorax patients.<sup>[2,5]</sup> We hereby, report a case of spontaneous pneumothorax in a 19-year-old female due to metastatic osteosarcoma of left iliac bone.

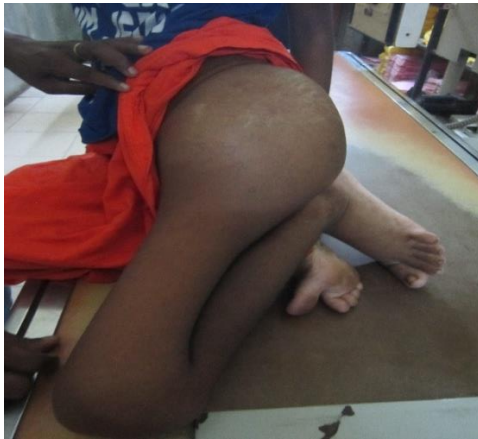### Name & Address of Corresponding Author

Dr. Pradosh Kumar Sarangi,  
Junior resident,  
Department of Radiodiagnosis  
SCB medical college & Hospital, Cuttack, Odisha, India.

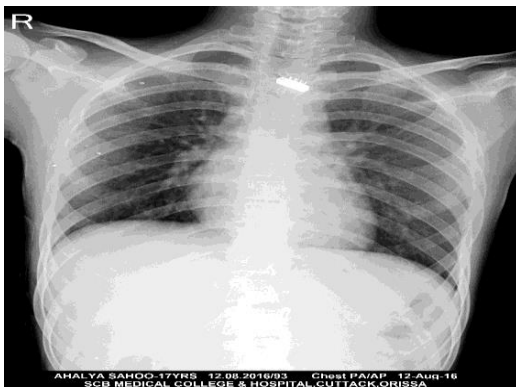## CASE REPORT

A 19-year-old female presented with dyspnea for 2 days. She had no history of trauma or any surgical intervention in the chest region. She had no other complaints like history of fever, chest pain, hemoptysis. She had no significant medical or

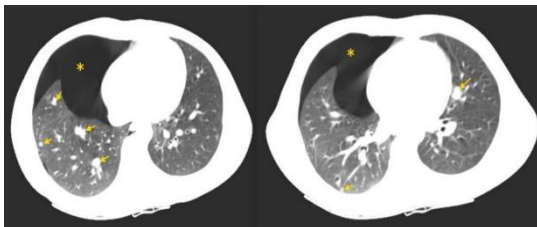
surgical history. She had swelling above left hip joint associated with mild pain for 1 year, for which she was under treatment by a local doctor who diagnosed it as muscular swelling but no improvement was noted after conservative management. Due to mild pain patient ignored it and then the patient developed sudden onset of respiratory distress for which she was admitted to our institution. On examination, pulse rate was 94 bpm and regular; respiratory rate 36/min, BP-124/80 mmHg. No central cyanosis or clubbing was not present. Chest examination showed tympanic percussion note and diminished vesicular breath sound over right hemithorax. On local examination, a huge soft tissue swelling noted in left hip region. No warmth or tenderness was noted [Figure 1]. She was referred to our department for urgent chest X-ray. However, CXR was apparently normal without any evidence of lung nodules or pneumothorax [Figure 2]. CT scan of thorax was done which revealed right pneumothorax with multiple pulmonary nodules in bilateral lung fields [Figure 3]. Computed tomography of pelvis showed a soft tissue mass lesion centered on left hemipelvis with calcific foci within [Figure 4]. Sunburst type of periosteal reaction of ilium was noted. MRI of the pelvis revealed heterogeneous mass lesion in left iliac bone with soft tissue extension, possibly osteosarcoma [Figure 5]. Punch biopsy from the lesion revealed osteosarcoma. She was referred to our regional cancer center for further management.



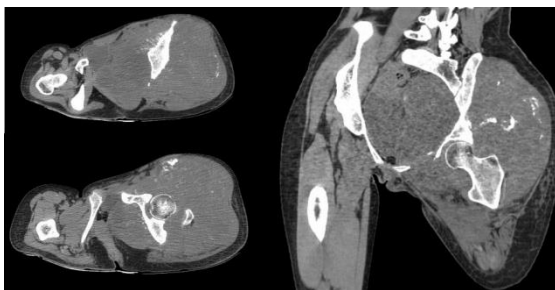
**Figure 1: Huge soft tissue swelling in left hip region.**



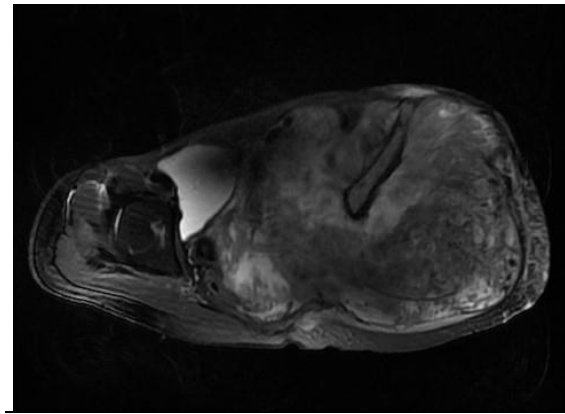
**Figure 2: Apparently normal chest X-ray PA view at presentation.**



**Figure 3: Computed tomography of thorax showing right pneumothorax (\*) with bilateral pulmonary metastases (arrows).**



**Figure 4: Computed tomography of pelvis showing a soft tissue mass lesion centered on left hemipelvis with calcific foci within. Sunburst type of periosteal reaction of ilium is noted.**



**Figure 5: Axial T2- fat suppressed MRI image showing a huge lobulated necrotic soft tissue mass lesion centered on left hemipelvis displacing bladder to the right.**

## DISCUSSION

Pneumothorax can be spontaneous (non-traumatic), traumatic or iatrogenic. SP can be primary (without any pre-existing lung pathology) or secondary (with abnormal underlying lung). SP is usually seen in healthy young male, its pathogenesis is associated with rupture of bullae, blebs, and subpleural emphysema. SP also occurs secondary to pulmonary disorders like chronic obstructive pulmonary disease (COPD), diffuse interstitial fibrosis, infections, iatrogenic factors like mechanical ventilation, central line in the subclavian vein, tracheostomy and due to chest trauma. There is a known association between emphysematous pulmonary bullae and lung cancer, but this very rarely predisposes to pneumothorax as the initial clinical manifestation, 0.03% being the incidence due to the primary lung tumour and with that of pulmonary metastases is even rarer.<sup>[5,6]</sup> Lung is the most frequent site for metastasis of osteosarcoma.<sup>[7,8]</sup> The mechanism of pneumothorax is not clearly understood yet, several hypotheses have been proposed<sup>[1]</sup>:

- (1) Formation of a fistula between parenchyma and pleura due to rupture of necrotic subpleural tumor nodule or micrometastasis, secondary to vascular lesion or chemotherapy or radiotherapy.
  - (2) Ball-valve mechanism due to partial bronchiolar obstruction by a tumor tissue, causing alveolar distension, dehiscence of alveolar walls, and passage of air in the interlobular septa to the pleura, forming blebs that breaks.
  - (3) Tumor emboli with infarction and necrosis.
  - (4) Tumor infiltration in the wall of a preexisting benign cavity and its rupture into the pleural space.
- Pneumothorax can be one-sided or simultaneous bilateral in patients with osteosarcoma, those receiving chemotherapy have a higher incidence than those who do not. The relative risk of pneumothorax developing doubled, from 7–14%, after the introduction of chemotherapy. The period

from chemotherapy initiation to pneumothorax onset ranged between first and seventh days.<sup>[7]</sup> Unilateral is reported to be more common (5-7%) than bilateral [only a few reported cases] and occurred mostly in patients during the course of treatment with chemotherapy.<sup>[9]</sup>

Lai et al in their study reported that 18 of 5,567 (0.32%) patients with primary lung cancer had pneumothorax as a complication, and two of them after chemotherapy.<sup>[10]</sup> In another study of 552 cases of osteogenic sarcoma, McKenna et al<sup>[11]</sup> identified pneumothorax in 5% of the patients with pulmonary metastases in agreement with data of Smevick et al<sup>[12]</sup> who reported a frequency between 5 to 7%.

Simultaneous bilateral pneumothorax in osteosarcoma has also been reported which is even rarer.<sup>[1,7-9]</sup> Many sporadic case reports also describe SP due to lung metastases from angiosarcoma, metastatic thyroid (papillary, medullary) carcinoma, teratomas, Wilms' tumors, melanomas, carcinomas of the kidney and pancreas, metastatic ovarian granulosa cell tumor, testicular cancer, lymphomas, choriocarcinomas, and lymphangiomatosis.<sup>[6,13-16]</sup>

Sensitivity of detection of lung metastasis was 57% by chest x-ray and 88% by chest computed tomography.<sup>[8]</sup> Chest X-ray upright PA view is not 100% sensitive in diagnosing pneumothorax. In a study by Thomsen et al, the reported mean sensitivity and specificity of diagnosing pneumothorax in inspiration by chest X-ray is 86.1% and 97.3% respectively<sup>[17]</sup>. CT is considered as the gold standard for the diagnosis of pneumothorax. So, it is essential to do a CT thorax when CXR doesn't detect any metastatic nodules or pneumothorax in the clinical setting of dyspnea in an osteosarcoma patient. In our case, CXR was negative for pneumothorax and lung metastasis.

In the present case, we excluded idiopathic spontaneous pneumothorax and traumatic pneumothorax due to the clinical and radiographic findings. The patient was not receiving chemotherapy or radiotherapy and was found to have pneumothorax at the initial presentation, which is rare.

## CONCLUSION

Although the pathogenesis of spontaneous pneumothorax is not clear, we conclude that the metastases as random nodules in lung parenchyma and under the pleura and their cystic degeneration can lead to spontaneous pneumothorax. Chest computed tomography detects minimal pneumothorax or subpleural lung metastasis and early diagnosis and management can help improve the prognosis and the quality of life of the patient. It can also be stressed that patients presenting with spontaneous pneumothorax without any known lung pathology should be actively investigated for metastatic neoplasm.

## Acknowledgements

We would like to thank Dr. Sanjay Kumar Nahak, Senior Resident, Department of Radio-diagnosis, SCB medical college for providing an MRI image of this case. The authors would also like to thank the patient and her father for their cooperation.

## REFERENCES

- Gan Z, Lin S, Han K, Shen Z, Yao Y, Min D. Bilateral spontaneous pneumothorax in an osteosarcoma patient with pulmonary metastases: A case report. *Oncology Letters*. 2016; 11(2):1179-1180.
- Laucius JF, Brodovsky HS, Howe CD. Spontaneous pneumothorax and pneumomediastinum as complications of sarcoma. *J Thorac Cardiovasc Surg*. 1972;64:467-471.
- Yamamoto T, Mizuno K. Spontaneous pneumothorax without any detectable pulmonary metastases in a patient with osteosarcoma. *Int Orthop*. 1999;23:361-362.
- Hoag JB, Sherman M, Fasihuddin Q, Lund ME. A comprehensive review of spontaneous pneumothorax complicating sarcoma. *Chest*. 2010;138:510-518.
- Tschopp JM, Rami-Porta R, Noppen M, Astoul P: Management of spontaneous pneumothorax: state of the art. *Eur Respir J*. 2006;28:637-650.
- Moreno Merino S, Gallardo Valera G, Congregado Loscertales M. Spontaneous pneumothorax as the initial manifestation of medullary thyroid carcinoma. *Arch Bronconeumol*. 2011;47:615-6.
- Once IM, Sunam GS, Yildiran H. Simultaneous Bilateral Secondary Pneumothorax. *Eur J Gen Med*. 2015;12(1):174-176.
- Sen BK, Basu M, Das S, Chaturvedi AN. Unusual Cause of Spontaneous Bilateral Pneumothorax Secondary to Osteosarcoma Metastasis. *J Assoc Physicians India*. 2016;64(2):68-69.
- Boersma RS, Buijs J. Simultaneous bilateral pneumothorax as a presenting symptom of osteosarcoma. *European Journal of Internal Medicine*. 2007;18(4):342-343.
- Lai RS, Perng RP, Chang SC: Primary lung cancer complicated with pneumothorax. *Jpn J Clin Oncol* 1992;22: 194-7.
- McKenna RJ, Schwinn CP, Soong KY, Hihinbotham NL. Sarcomata of the osteogenic series (osteosarcoma, fibrosarcoma, chondrosarcoma, parosteal osteogenic sarcoma, and sarcomata arising in abnormal bone). *J Bone Joint Surg [Am]*. 1966;48:1-26.
- Smevik B, Klepp O. The risk of spontaneous pneumothorax in patients with osteogenic sarcoma and testicular cancer. *Cancer*. 1982; 49:1734-1737.
- Lee M, Kim E, Kim M, Kwak J, Hong S, Park C. Spontaneous Pneumothorax in Metastatic Thyroid Papillary Carcinoma. *Journal of Clinical Oncology*. 2007;25(18): 2616-2618.
- P.G. Davidson, J.T. McGinn Jr., S.L. Goldberg. Bilateral spontaneous pneumothoraces caused by metastatic ovarian granulosa cell tumor. *Chest*. 1990;98(2):503-505.
- Chen W, Shih CS, Wang YT, Tseng GC, Hsu WH. Angiosarcoma with pulmonary metastasis presenting with spontaneous bilateral pneumothorax in an elderly man. *J Formos Med Assoc*. 2006;105(3):238-41.
- Pearson FG, Cooper JD, Deslauriers J, Ginsberg RJ, Hiebert C, Patterson GA, et al. *New York: Churchill Livingstone; Thoracic Surgery*. 2nd ed; p. 2002.
- Thomsen L, Natho O, Feigen U, Schulz U, Kivelitz D. Value of digital radiography in expiration in detection of pneumothorax. *Rofo*. 2014;186(3):267-73.

**How to cite this article:** Kumar LS, Sarangi PK, Mohanty J, Parida S. Spontaneous Pneumothorax as the Initial Presentation in an Osteosarcoma Patient: A Case Report. Ann. Int. Med. Den. Res. 2017; 3(2):RD04-RD07.

**Source of Support:** Nil, **Conflict of Interest:** None declared