

Diagnostic Accuracy of High Resolutions Sonography in the Evaluation of thyroid Lesions in a Tertiary Care Centre in Northern Kerala.

Jinu CK¹, Krishnananda Holla², Mahesh P³, Junise M⁴

¹Assistant Professor, Dept. of Radiology, Academy of Medical Sciences, Pariyaram, Kannur, Kerala

²Associate Professor, Dept. of Radiology, Academy of Medical Sciences, Pariyaram, Kannur, Kerala

³Professor, Dept. of Radiology, Academy of Medical Sciences, Pariyaram, Kannur, Kerala

⁴Junior resident, Dept. of Radiology, Academy of Medical Sciences, Pariyaram, Kannur, Kerala.

Received: January 2017

Accepted: January 2017

Copyright: © the author(s), publisher. It is an open-access article distributed under the terms of the Creative Commons Attribution Non-Commercial License, which permits unrestricted non-commercial use, distribution, and reproduction in any medium, provided the original work is properly cited.

ABSTRACT

Background: The objectives of this study were to evaluate thyroid lesions, to differentiate between possible benign and malignant lesions and to assess the diagnostic accuracy of high resolution sonography in thyroid lesions. **Methods:** Patients presenting with clinical suspicion of thyroid disease referred to the Department of Radiodiagnosis were included in the study. Ultrasound was done as an initial diagnostic imaging method and later underwent to ultrasound guided FNAC, for confirmation of diagnosis. Findings of the thyroid ultrasound scan were correlated with FNAC diagnosis. **Results:** Ultrasound was able to pick up lesions in all 100 cases with a sensitivity and specificity of 72 % and 100% respectively. Ultrasonography showed a Diagnostic accuracy of 97% for thyroid diseases. Sonography could considerably differentiate between malignant and benign lesions. Ultrasound guided FNAC showed high diagnostic yield for detection of thyroid diseases. **Conclusion:** The current study suggests that high resolution sonography can be used as a primary imaging modality for the evaluation of thyroid diseases with high diagnostic accuracy. Ultrasound helps in guiding FNAC for confirmation of the diagnosis.

Keywords: Ultrasonography, Thyroid, USG.

1

INTRODUCTION

Thyroid gland plays a major role in the regulation of the body metabolism. The thyroid gland is affected by a wide spectrum of pathologic conditions including benign and malignant lesions. Ultrasonography (USG) is usually the first and most commonly ordered imaging study for thyroid disorders. One of the limitations of gray scale ultrasonography is its relative inability to differentiate between benign and malignant lesions. Doppler ultrasonography and more recently high resolution sonography have been used with significant improvement in the diagnostic accuracy. High resolution sonography combines the techniques of compound scan and harmonic imaging^[1].

Name & Address of Corresponding Author

Junise M,
Junior resident,
Dept. of Radiology,
Academy of Medical Sciences, Pariyaram, Kannur, Kerala.

Prevalence of thyroid lesions is 13% to 67% by sonographic evaluation. However, less than 7% of thyroid nodules are malignant. Because of the

superficial location of the thyroid gland and superior sonographic imaging clarity provided by transducers with frequencies of 7.5 to 15 MHz, high resolution sonography can demonstrate normal thyroid anatomy and pathologic conditions with remarkable resolution, which increases the role of sonography in thyroid imaging^[2]. To diagnose thyroid lesions, sonography is the cornerstone which aids in localization, differentiation and also interventional procedures^[1].

To solve the confusing or overlapping spectrum of thyroid lesions USG guided FNAC is useful adjuvant technique. In such scenarios Fine Needle Aspiration Cytology (FNAC) and histopathology (HPE) aids the diagnosis. The sensitivity of FNAC in thyroid lesions ranges from 78-98%^[2]. The current management guidelines (American thyroid association) states that the diagnostic ultrasonography should be performed in all patients with thyroid nodules and FNAC in potentially malignant lesions^[3].

Objectives of the Study

➤ To differentiate between possible benign and probably malignant masses based on their sonographic appearance.

- To assess the diagnostic accuracy by correlation with histopathological or cytological diagnosis.

Background

Thyroid gland has homogenous medium to high level Echogenicity. The capsule appears as a hyper echoic line. Sonography of superficial soft tissue structures was first done by Howry et al in 1954. They proposed the importance of sonography in diagnosis of benign & malignant tumors of neck. Lees et al (1978) stated that sonography can differentiate normal from abnormal thyroid. And they documented a diagnostic accuracy of 94% in thyroid diseases^[4-12]

Table 1: Thyroid measurements^[9-12].

| | Longitudinal | AP |
|----------|--------------|---------|
| New Born | 18-20 mm | 8-9 mm |
| < 1year | 25 mm | 12-15mm |
| Adults | 40-60 mm | 13-18mm |

The major clinical application of sonography in thyroid diseases are^[13]

1. Detection of Thyroid Lesion:

- Differentiation of thyroid nodules from other cervical masses
- As a problem solving tool when the findings on Physical examination and lab values are equivocal.
- Detection of occult thyroid nodules in high risk patients
- Detection of residual, recurrent disease

2. Characterisation of Thyroid Lesion:

- Focal or diffuse
- Solitary nodule or multinodular.
- Internal consistency - Cystic or solid.

3. To determine the extent of the lesion

4. Biopsy guidance:

- Ultrasound guided biopsy are easier and more specific than the usual biopsy

5. Therapeutic Evaluation:

- To assess the response of the nodules for treatment.
- Volumetric assay for radionuclide dosage^[9].

MATERIAL AND METHODS

A cross sectional study was conducted in Department of Radiodiagnosis, Academy of Medical Sciences, Pariyaram from 01.02.2013 to 31.10.2014 after informed consent.

- Study group comprised of 100 patients with suspected thyroid diseases referred for ultrasound scanning. Sample size was calculated

using appropriate formula. Institutional ethical committee clearance was obtained.

- Inclusion criteria- Those patients who are having imaging findings of benign or malignant lesions on ultrasonography will be included in the study.
- Exclusion criteria- those patients with no demonstrable sonographical abnormality in the thyroid gland.

Each patient were evaluated as follows after taking informed consent,

1. Brief history, clinical examination and relevant biochemical investigations will be obtained in all patients.
2. 3) Radiological evaluation by high resolution real time ultrasonography and color doppler performed in GE VOLUSON 730 Expert ultrasound machine with a 12MHz probe in longitudinal and transverse planes.

The findings were correlated and confirmed with follow-up FNAC or biopsy.

The thyroid were evaluated under the following headings

Anatomy

Both lobes of the thyroid and isthmus were evaluated for

1. Size
2. shape
3. Echogenicity
4. Borders
5. Vascularity
6. Capsule
7. Retrosternal extension if any

Pathology

In case of any thyroid lesions, following characters will be noted

1. Location of the lesion
2. Size
3. Shape
4. Capsular integrity
5. Echogenicity
6. Presence of cystic changes, blood or fluid
7. Calcification- type and location in the lesion
8. Mass effect
9. Relation or Invasion to surrounding structures
10. Vascularity
11. Perilesional vessels or Vascularity

Lymph nodes if present will be evaluated for

1. Size
2. Shape
3. location
4. Echogenicity
5. Whether matting present or not
6. Necrosis
7. Calcification

Classification of Thyroid Swelling

1. **Hyperplasia**
 - a. **Diffuse**
 - b. **Solitary Nodule**
 - c. **Multinodular**
 - i. Euthyroid
 - ii. Hyper functioning
2. **Thyroiditis**
 - Acute
 - Sub acute
 - Chronic

b. 1) Non specific 2) Hashimoto's 3) Atrophic
3. **Adenomas**
 - Follicular
 - Non-follicular
4. **Malignant Neoplasms**
 - Follicular carcinoma
 - Papillary carcinoma
 - Medullary carcinoma
 - Anaplastic carcinoma
 - Lymphoma, sarcoma, teratoma etc

Goitre and Diffuse Hyperplastic Goitre

Sonographically they will appear as isoechoic. Many becomes hyper echoic when the size increases, due to numerous interfaces between cells and colloid substance. A thin hypo echoic halo around the lesion due to perinodular blood vessels and oedema may present. Cystic degenerations or haemorrhages may develop in late stages^[14].

Thyroiditis

▪ **Acute Thyroiditis**^[15]

On ultrasound gland may be enlarged (focal or diffuse). The affected part will be heterogeneous or hypo echoic. Diffuse sonolucency indicates an inflammatory process^[15].

▪ **Sub Acute (De Quervain's) Thyroiditis**

On Sonography affected areas will become hypo echoic and Doppler will show reduced or absent flow. Multiple hypo echoic areas in the thyroid with atrophy of the gland in later stages also may be seen. Complete recovery is characteristic ^[15,16].

▪ **Graves's Disease**^[17]

Sonographically, the gland will appear hypo echoic and inhomogeneous causing diffuse swelling. Doppler will show increased blood flow, known as thyroid inferno. Spectrum shows PSV >70 cm/sec.

Hashimoto's thyroiditis (Autoimmune Thyroiditis)

Sonography will show diffuse enlargement and hypo echoic coarse parenchyma of the gland with irregular lobulated margins. Echogenic fibrous septa are causing this pseudo lobulated appearance. Parenchyma will be uneven with decrease in the

normal echogenicity. A micro nodular pattern is diagnostic. Doppler will show slightly increased vascularity^[18].

Thyroid Adenomas

Follicular adenoma:

The distinction between true adenoma from a nodular goitre (Adenomatous goitre) is mainly by the presence of a well defined capsule. According to the type of cell proliferation follicular adenoma is subdivided into

- Fetaladenoma
- Hurthle cell adenoma
- Embryonal adenoma^[14]

Papillary adenoma:

Adenomas usually appear as solid lesions. Echogenicity will be hyper, iso or hypo. Often adenomas will have thick uniform smooth hypo echoic peripheral halo (due to fibrous capsule and blood vessels)^[19,20]. Sometimes spoke and wheel appearance may be seen due to the special arrangement of blood vessels within the lesion^[14].

Malignant Thyroid Nodule

Malignant neoplasms of thyroid includes

- Papillary adeno-carcinoma
- Follicular carcinoma
 1. Clear cell carcinoma
 2. Oxyphil carcinoma
- Medullary carcinoma
- Undifferentiated carcinoma
 1. Small cell carcinoma
 2. Giant cell carcinoma
- Epidermoid carcinoma
- Other malignant tumours include
 - Lymphoma
 - Sarcoma
 - Teratoma
 - Metastasis

Papillary Thyroid Carcinoma

Sonographically it is hypo echoic due to closely packed cell content with minimal colloid. Micro-calcification may be seen. Doppler will show increased vascularity in majority of cases. Cervical lymph node enlargements are commonly seen. It is rare for papillary carcinoma to exhibit large amount of cystic changes. Rarely may they show muscular invasion. A follicular variant of papillary carcinoma is uncommon variety which looks similar to follicular neoplasm on gross pathological examination and by ultrasound imaging ^[14,21].

Follicular Carcinoma^[14,22,23]:

They are subdivided into minimally, moderately or highly invasive tumour. Most of the cases of the follicular carcinomas are hypo echoic or isoechoic^[41]. FNA is not reliable in differentiating benign from malignant neoplasm because the

visualisation capsular and vascular invasion is possible only by biopsy^[14].

Medullary Carcinoma

It is a poorly defined non-encapsulated invasive mass. They originate from para follicular cells of the gland. On ultrasound they will appear as hypo echoic solid mass and are similar to papillary carcinoma^[24] coarse calcifications are often seen^[14].

Anaplastic Carcinoma Thyroid^[25,26]

It is rare tumor (only 2%) typically seen in the elderly and considered as one of the most aggressive tumor of endocrine origin with high mortality rate^[26]. On ultrasound they are usually hypo echoic and often encase or invade blood vessels, neck muscles and other adjacent structures. Often CT or MRI is needed to clearly delineate the extent of lesion^[14].

Lymphoma

In ultrasound they appear as a hypo echoic mass with lobulated margins. Sometimes it may show only diffuse enlargement with normal parenchyma. The involvement can be focal or diffuse. Cystic necrosis is common at later stages. The mass may encase the surrounding structures. Doppler will show reduced flow. Large round hypo echoic nodes with posterior enhancement is typically seen in lymphoma.^[14,28]

Sarcoma

Primary thyroid sarcomas are extremely rare. Angiosarcomas (Hemangio endotheliomas) and fibrosarcomas are the more likely sarcoma types^[29].

Metastatic Carcinoma

The common primaries are melanoma, breast and renal cell carcinoma. Sonography will show large well defined with uniformly hypo echoic focal mass. In case of diffuse involvement of the gland it will become hetero echoic. Associated lymph nodes may be seen. Doppler may be normal or may show increased blood vessels^[30]

RESULTS

The maximum number of cases in the age group of 31-40 years (29%) and 41-50 years (27 %). Most of the patients are females (91%). Most common clinical diagnosis is Multinodular goitre (MNG) (35%) followed by solitary nodular goitre (SNG) (27%). It was observed that, among 100 patients of thyroid diseases most common are Solitary nodular goitre by ultrasonography .Thyroglossal cyst (1%) is the least one. It is observed that most of the cases are solitary nodules (46%), followed by multiple nodule cases (41 %). Rest of the 13% of cases are Thyroiditis or thyroglossal cyst which does not have any nodule.

The study showed that the echo texture of thyroid in maximum number of Cases seen are Hetero echoic (49%), followed by Hypo echoic (40%) Hyper echoic (4%) and anechoic (4%).

Out of the 100 thyroid cases, calcification was seen in 8 cases only. Among this, micro calcification was seen in 6 (71%) cases and macro calcification was seen in 2 (29%) cases. Enlarged lymph nodes were seen in six cases (6%) only.

It is observed that out of the 100 case peripheral halo was seen in 25 cases only. Out of which 20 (80%) had thin halo and 5(20%) cases had thick halo.

Most of the lesions showed well defined margins (81%), Poorly defined (6%) and speculated (2%) are also seen 51% of cases showed peripheral flow around the lesion which is characteristic of benignity. 5% of cases showed internal flow which is in favour of malignancy. 38% of cases showed normal Vascularity. Only 6% showed increased Vascularity

In our study maximum number of cases observed by FNAC/HPE is colloid goitre which includes SNG and MNG (57%), followed by benign nodule which includes adenoma and hyperplasic nodule (20%) primary thyroid carcinoma (11%) and Thyroiditis (11%). Only one case of thyroglossal cyst has been reported

Distribution of the Clinical Diagnosis According TOFNAC/HPE

Table 2: Distribution of the clinical diagnosis according to FNAC/HPE.

| Clinical DX | Colloid | | Benign | | Thyroiditis | | Carcinoma | | Thyroglossal Cyst | |
|--------------|---------|---------|--------|---------|-------------|---------|-----------|---------|-------------------|---------|
| | Goitre | | Nodule | | | | | | | |
| | Count | Percent | Count | Percent | Count | Percent | Count | Percent | Count | Percent |
| SNG | 14 | 24.6 | 7 | 35.0 | 2 | 18.2 | 4 | 36.4 | 0 | 0.0 |
| MNG | 24 | 42.1 | 6 | 30.0 | 2 | 18.2 | 3 | 27.3 | 0 | 0.0 |
| Goitre | 13 | 22.8 | 3 | 15.0 | 2 | 18.2 | 0 | 0.0 | 0 | 0.0 |
| Thyroiditis | 6 | 10.5 | 3 | 15.0 | 4 | 36.4 | 2 | 18.2 | 0 | 0.0 |
| Carcinoma | 0 | 0.0 | 1 | 5.0 | 1 | 9.1 | 2 | 18.2 | 0 | 0.0 |
| Thyroglossal | 0 | 0.0 | 0 | 0.0 | 0 | 0.0 | 0 | 0.0 | 1 | 100.0 |
| Cyst | | | | | | | | | | |

Thyroid Diseases Finding According to Age

Table 3: Distribution of the thyroid diseases finding according to age.

| Age | Colloid Goitre | | Benign Nodule | | Thyroiditis/ Thyro. Cyst | | Carcinoma | |
|--------|----------------|---------|---------------|---------|--------------------------|---------|-----------|---------|
| | Count | Percent | Count | Percent | Count | Percent | Count | Percent |
| 10- 20 | 2 | 3.5 | 1 | 5.0 | 1 | 8.3 | 0 | 0.0 |
| 21- 30 | 15 | 26.3 | 4 | 20.0 | 1 | 8.3 | 1 | 9.1 |
| 31- 40 | 16 | 28.1 | 8 | 40.0 | 3 | 25.0 | 2 | 18.2 |
| 41- 50 | 16 | 28.1 | 4 | 20.0 | 3 | 25.0 | 4 | 36.4 |
| 51- 60 | 8 | 14.0 | 2 | 10.0 | 4 | 33.3 | 3 | 27.3 |
| 61- 70 | 0 | 0.0 | 1 | 5.0 | 0 | 0.0 | 1 | 9.1 |

Association of Thyroid Disease with Age

Table 4: Association of thyroid disease with age.

| Age | Colloid Goitre | | Benign Nodule | | Thyroiditis/ Thyro. Cyst | | Carcinoma | | Chi ² | p |
|---------|----------------|---------|---------------|---------|--------------------------|---------|-----------|---------|------------------|-------|
| | Count | Percent | Count | Percent | Count | Percent | Count | Percent | | |
| 10 – 30 | 17 | 29.8 | 5 | 25.0 | 2 | 16.7 | 1 | 9.1 | 8.05 | 0.529 |
| 31 – 40 | 16 | 28.1 | 8 | 40.0 | 3 | 25.0 | 2 | 18.2 | | |
| 41 – 50 | 16 | 28.1 | 4 | 20.0 | 3 | 25.0 | 4 | 36.4 | | |
| > 50 | 8 | 14.0 | 3 | 15.0 | 4 | 33.3 | 4 | 36.4 | | |

Association of Thyroid Diseases with Sex

Table 5: Association of thyroid diseases with sex.

| Sex | Colloid Goitre | | Benign Nodule | | Thyroiditis/ Thyro. Cyst | | Carcinoma | | Chi ² | p |
|--------|----------------|---------|---------------|---------|--------------------------|---------|-----------|---------|------------------|-------|
| | Count | Percent | Count | Percent | Count | Percent | Count | Percent | | |
| Female | 55 | 96.5 | 17 | 85.0 | 11 | 91.7 | 8 | 72.7 | 7.47 | 0.058 |
| Male | 2 | 3.5 | 3 | 15.0 | 1 | 8.3 | 3 | 27.3 | | |

Table 6: Statistical analysis.

| | |
|-----------------------------------|-------|
| Sensitivity | 72.7 |
| Specificity | 100.0 |
| False Negative | 27.3 |
| False positive | 0.0 |
| Predictive value of positive test | 100.0 |
| Predictive value of negative test | 96.7 |
| Positive Likelihood ratio | - |
| Negative Likelihood ratio | 0.3 |
| Diagnostic Accuracy | 97.0 |

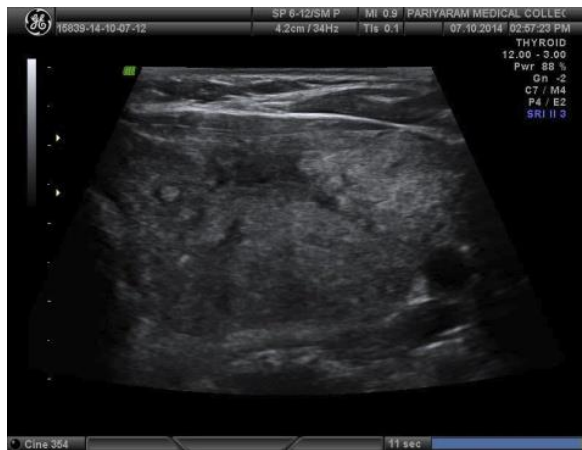


Figure 1: Heterogeneous nodule with some cystic changes.

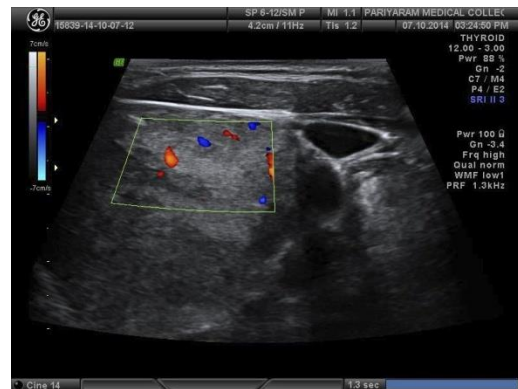

Figure 2: Thyroid nodule showing internal Vascularity.

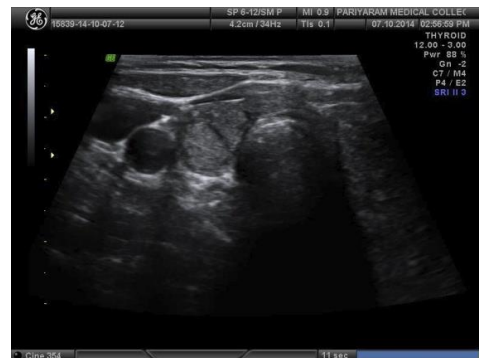

Figure 3: Hyper echoic Thyroid nodule with peripheral halo.

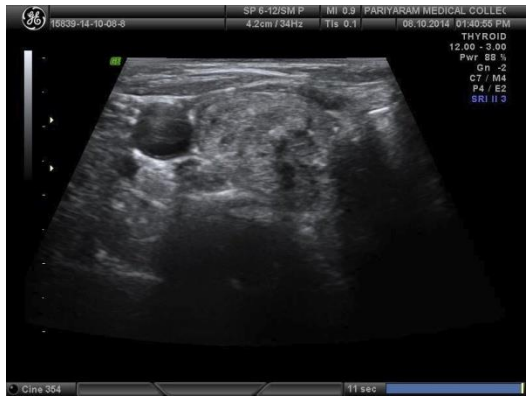

Figure 4: Hetero echoic nodule with punctuate calcification.

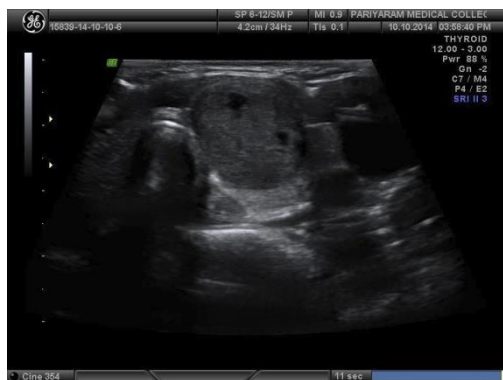

Figure 5: Hypo echoic nodule with minimal cystic changes.

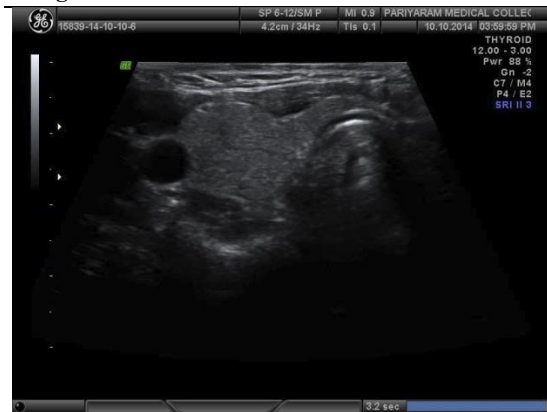

Figure 6: Isoechoic nodule.

DISCUSSION

The larger group of patients were in 31-50 yrs age group. The oldest patient was of 63 years and youngest was of 15 yrs. A female preponderance (91%) was noted in the study. A similar demography was reported in the study conducted by Jeffery R. Wienke et al., whereas most of the patients were in the age group of 30-50 and out of 68 cases 63 were females and only 7 were males^[33]. Uzma Bukhari et al., reported thyroid lesions in 158 cases, of which 138 were female and 27 were males. Most of the cases were found in the age group of 30-50 yrs^[34].

Mary et al., studied 1985 patients of which 1742 occurred in women and 203 were males and most of patients was in the age group of 30-50.

The commonest thyroid pathology diagnosed in our study was colloid goitre (57%). Most of the cases were hetero echoic in appearance followed by hypo echoic. Calcification was seen only in 7%. Lymphadenopathy was seen in 6%. Peripheral halo was seen in 25 cases only, out of which 20 were thin halo and 5 cases had thick halo.

In a study by Mary et al., they reported that, out of 1985 patients 1181 patients had solitary thyroid nodules and 804 patients had multiple nodules. And they noted that solitary nodule had a higher likelihood of malignancy than a non solitary nodule^[35]. Jeffery R. Winke et al. reported 27 cases of colloid cysts in their study.

The second largest group were benign nodule, which includes adenoma and hyperplastic nodule. A total of 20 cases were reported, Out of which 14 were adenomas and 6 were hyperplastic nodules. Jeffery R. Winke et al. reported, on 82 thyroid nodules of which 41 were adenomas and 27 cases were colloid cyst in their study^[33]. Kamaljit Kaur et al reported 41 benign nodules out of the 50 cases they studied^[36].

The appearance of benign nodules were predominantly hypoechoic and solid followed by mixed (solid and cystic) or heterogenous. In a study conducted by Kamaljit Kaur et al on 50 thyroid nodules of which 41 nodules were benign and 9 were malignant lesions. Sonographically benign nodules were predominantly hypo echoic followed by mixed and cystic^[36].

Carcinoma was diagnosed in 11 patients by FNAC/HPE out of 100 cases, of which papillary carcinoma was 7, Follicular carcinoma 2, Medullary carcinoma 1 and Anaplastic carcinoma 1. M. Allauddin et al., studied 1140 thyroid cases, of which 154 were malignant. Out of that 98 were papillary thyroid carcinoma and 32 were follicular carcinoma and 6 were medullary carcinoma^[37]. Kamaljit Kaur et al reported 9 malignant cases among 50 patients they studied^[36].

Out of the 11 cases 9 were heterogeneous and 2 were hypo echoic in echo texture. Calcification were positive in 5 cases. Lymph nodes were noted in 5 cases. Thick peripheral halo was seen in 5 cases. Irregular margin was seen in 6 cases and spiculated margin in 2 cases. On Doppler normal internal flow was seen in 8 cases (3 cases were predominantly cystic), increased flow in 2 cases and peripheral flow in 1 case.

Sonographic Differentiation of Benign and malignant Thyroid Nodules:

1. Internal contents

A nodule with significant cystic change is more likely to be benign nodule. Comet tail artifacts are characteristic of benignity.

2. Echogenicity

Thyroid cancers are usually hetero echoic or hypo echoic while benign nodules are usually hyper echoic.

3. Halo

A thin regular complete peripheral halo that surrounds a thyroid nodule is more favourable of benign lesions. While malignant lesions have thick irregular halos.

4. Margins

Benign modules usually have sharp well defined margins. While malignant case irregular or poorly defined or spiculated margins.

5. Calcification

Fine calcifications are more favourable of malignancy while macro calcification suggests benign nodule.

Manju. B et al. reported high sensitivity and specificity in differentiating benign and thyroid lesions with these features in their study^[38]:

- Solid or predominantly solid composition (sensitivity 88.6%, specificity 53.5%);
- Micro-calcification (sensitivity 65.9%, specificity 97.9%);

Results of other studies (USG)

- Irregular or poorly defined margins (sensitivity 84%, specificity 88.7%);
- Anteroposterior (AP) diameter > transverse diameter (sensitivity 77.2%, specificity 80.1%);
- Absent or thick incomplete halo (sensitivity 70.4%, specificity 65.8%);
- And marked lyhypoechoic nature (sensitivity 65.9%, specificity 84.6%)

The present study had a sensitivity of 72%, specificity of 100% and diagnostic accuracy of 97% in detecting thyroid malignancy. The sensitivity and specificity of USG in various studies ranges from 60-88% and 59-96% respectively. The high specificity obtained in the study can be attributed to stringent adherence to the above mentioned criteria, which in turn reduced the sensitivity in our study.

A total of 11 patients of Thyroiditis were detected by sonography, most of them appeared isoechoic and hypo echoic on ultrasound. On FNAC they were proven to represent 9 Hashimotos Thyroiditis and 2 De quervain`s Thyroiditis. Hashimotos Thyroiditis is the most common form of thyroiditis^[39].

One case of thyroglossal cyst is detected by ultrasound and later on confirmed by HPE. Wadsworth et al. reported thyroglossal cyst in 12 cases ranging from 2 months to 16 years old^[40].

Table 7: Results of other studies.

| Author | Years | Sensitivity | Specificity | Accuracy |
|--------------------------------------|-------------|-------------|-------------|------------|
| | | (%) | (%) | (%) |
| Jones et al. ^[56] | 1990 | 75 | 61 | |
| Waters et al. ^[57] | 1992 | 74 | 83 | |
| S Arda-et al. ^[58] | 2001 | 60 | 59 | 59 |
| Kamalji tkaur et al. ^[54] | 2002 | 71.4% | 77% | |
| Nggada HA et al ^[59] | 2004 | 88 | 96 | 94.2 |
| F. Basolo et al | 2009 | 70 | 91 | 95 |
| Present Study | 2014 | 72% | 100% | 97% |

Summary

- The disorders of thyroid gland are most common in female (91%) population compared to male (9%) in our study population.
- Maximum numbers of patients in our study were encountered in the age group of 31-40 (29%) and 41-50 (27%).
- Patients of colloid goitre formed the largest proportion of the cases in our study and ultrasound was able to depict that successfully
- Ultrasound was clearly able to delineate benign nodules in 20 cases which include adenoma and hyperplastic nodules. One case diagnosed as benign nodule turned out to be malignant on FNAC.
- Carcinoma is diagnosed in 8 patients by ultrasound and in 11 patients by FNAC/HPE. Out of which papillarycarcinoma was 7, Follicular carcinoma 2, Medullary carcinoma 1 and Anaplastic carcinoma 1

- Ultrasound showed Irregular margin in 6 and spiculated margin in 2 cases of carcinoma.
- On doppler normal internal flow was seen in 8, increased flow in 2 and peripheral flow in 1 cases of carcinoma
- Calcification is present in 7 patients
- Significant lymph node enlargement were seen in 6 patients
- 11 patients of Thyroiditis were detected by sonography
- Sensitivity of ultrasound for detecting malignancy in the study is 72%
- Specificity of ultrasound for detecting malignancy in the study is 100%
- Diagnostic accuracy of ultrasound in the study is 97%
- High resolution sonography is a useful modality in distinguishing thyroidal from other neck masses.

- High resolution sonography can clearly differentiate benign from malignant thyroid nodules in most of the cases.
- Ultrasound is useful in the diagnosis and follow up of diffuse thyroid diseases like Thyroiditis.
- Ultrasound is Useful in diagnosis of congenital conditions like thyroglossal cyst.
- Ultrasound is Useful imaging modality in evaluation of thyroid in children and pregnant women as there is no radiation risk.
- Ultrasound can be used to guide FNAC from thyroid lesions.

CONCLUSION

Conclusion

- High resolution sonography is a cost effective investigation and recommended as the primary imaging modality in the evaluation of thyroid diseases. It has a high sensitivity, specificity and diagnostic accuracy in the diagnosis of thyroid diseases.
- Ultrasonography in our study was found to be helpful in the morphological characterization of thyroid lesions
- Ultrasonography can differentiate benign from malignant Lesions in most of the cases. The characteristics of benign lesions – well defined margin, thin sonolucent halo, purely cystic lesions etc. can be clearly depicted by ultrasound. Micro calcification and lymph node involvement are most commonly seen in thyroid carcinoma which can be clearly delineated by ultrasound.
- Ultrasound can be used to guide the FNAC. The assisted FNAC definitely increases the yield of diagnostic material and aid in the correct diagnosis.

Limitations of the Study

- In thyroid disease evaluation histopathology is considered as the gold standard. But, in our study histopathology was not available in some of the cases as thyroid excision was not done in them. In such cases only FNAC was available which is taken as gold standard.
- Our study showed relatively lesser sensitivity and relatively high specificity, which could be due to the strict adherence to the criterias differentiating the benignity and malignancy.

Recommendations

- High resolution sonography is recommended as the primary imaging modality in the evaluation of thyroid diseases.
- Ultrasound guidance is recommended in FNAC to improve the tissue yield and accuracy
- Ultrasound can be used as a preoperative investigation in thyroid lesions

- Ultrasound can be used in follow up of thyroid diseases

REFERENCES

1. Beunen GP, Malina RM, Lefevre J, et al. Skeletal maturation, somatic growth and physical fitness in girls 6-16 years of age. *Int J Sports Med.* 1997; 18: 413-419.
2. Vikas chaudhary, Shahinabano. Imaging of thyroid: Recent advances. *Indian journal endocrinology and metabolism.* 2012; 3(16):371-376
3. MahiraYunus, Zeba Ahmed. Significance of ultrasound features in predicting malignant solid thyroid nodules: Need for fine-needle aspiration. *j pak medical assoc.* 2010;60(10): p.848-853
4. Cooper DS, Doherty GM, Haugen BR, Kloos RT, Lee SL, Mandel SJ. Revised American Thyroid Association Management Guidelines for Patients with Thyroid Nodules and Differentiated Thyroid Cancer. *Thyroid.* 2009;19:1167-214.
5. World Federation for Ultrasound in Medicine and Biology History/Archives Committee, Goldberg BB, Wells PNT, Claudon M, Kondratas R. History of Medical Ultrasound; June 1–4, 2003; Montreal, Quebec, Canada.
6. Robert A. Sofferman . The History of Clinical Ultrasound, in Robert A. Sofferman Anil T. Ahuja, editors. *Ultrasound of the Thyroid and Parathyroid Glands*; Springer. New York: p.3-8
7. Goldberg B, Gramiak R, Freimanis A. Early history of diagnostic ultrasound: the role of American radiologists. *AJR Am J Roentgenol.* 1993; 160:p.189–194
8. Shriki J. Ultrasound physics .*Critical Care Clinics.* 2014; 30(1): p1-24
9. Wells PN, author; McGahan JP, Goldberg BB, editors. *Physics and Bioeffects. Diagnostic Ultrasound, A logical approach.* Philadelphia: Lippincott-Raven Publishers; 1998. p. 1–19
10. Hangiandreou NJ, author. *AAPM/RSNA physics tutorial for residents. Topics in US: B-mode US: Basic concepts and new technology.* *Radiographics.* 2003;23:1019–33
11. Robert A. Sofferman. physics and basic principles of ultrasound , editors Anil T. Ahuja . Robert A. Sofferman. *Ultrasound of the Thyroid and Parathyroid Glands.* Springer: p.9-21
12. Fikri M Ashraf F, et al .*Clinical ultrasound physics.* *J Emerg Trauma Shock.* 2011; 4(4):p. 501–503.
13. Thomas S. Curry, James E. Dowdey, et al. Ultrasound, Chapter–20, In: Christensen’s *Physics of Diagnostic Radiology.* 4th Edn. Lea and Febiger, UK; p. 323 – 325
14. Simeone JF et al: *Sonography in follow up of 100 patients with thyroid carcinoma.* *AJR.* 1987;148:45-49
15. Solbiati L et al. The thyroid gland. In: Rumack CM, Wilson SR, Charboneau JW, editors. *Diagnostic Ultrasound.* 2005. 4th ed., Vol. 1. St. Louis, Missouri: Elsevier Mosby; p. 708-49
16. Kunz A, Blank W, Braun B. De Quervain “ssubacute thyroiditis – color Doppler sonography findings. *Ultraschall Med.* 2005; 26:102-6
17. Kumar K, Pasupuleti V. Role of thyroid Doppler in differential diagnosis of thyrotoxicosis. *Endocrinology Practice.* 2009;15:6–9
18. Yamashiro I, de Cassio Saito O. Ultrasound findings in thyroiditis. *Radiol Bras.* 2007;40:75-9
19. G.B Salabè. Pathogenesis of thyroid nodules: histological classification .*Biomedicine &Pharmacotherapy.* 1(55):p. 39-53
20. Ann D. King .Imaging for staging and management of thyroid cancer. *Cancer Imaging.* 2008.8(5):57-69.
21. Bryan K. Chan, MD, Terry S. Desser, MD. Common and Uncommon Sonographic Features of Papillary Thyroid Carcinoma .*J Ultrasound Med.* 2003;22:1083–1090.

22. Christopher R. McHenry . Follicular Adenoma and Carcinoma of the Thyroid Gland. *Oncologist*. 2011; 16(5): 585–593.
23. John C. Sillery, Carl C. Reading. Thyroid Follicular Carcinoma: Sonographic Features of 50 Cases. *AJR*: 2010;194.
24. Sung-Hun Kim, Bum-Soo Kim Ultrasonographic Findings of MedullaryThyroidCarcinoma:aComparisonwithPapillaryThyroidCarcinoma . *Korean J Radiol*. 2009; 10(2).
25. Jenny K. Hoang, Wai Kit Lee .US Features of Thyroid Malignancy: Pearls and Pitfalls. *Radio Graphics*. 2007; 27: 847–865
26. Serdaraltınay, Betültaş. Anaplastic thyroid carcinoma with diffuse thoracic skin metastasis: A case report. *Oncology letters*. 2014;7: 1767-1770.
27. Nagaiah G, Hossain A, Mooney CJ, et al. Anaplastic thyroid cancer: a review of epidemiology, pathogenesis and treatment. *Journal of Oncology*. 2011; 2(1):13.
28. AT.Ahuja. thyroid and parathyroid .chapter-3. *Practical Head and Neck Ultrasound*. Cambridge university press. 2000; p.35-68
29. LaurysBoudin, Nicolas Fakhry. Primary Synovial Sarcoma of the Thyroid Gland: Case Report and Review of the Literature .*Case Rep Oncol*. 2014; 7(1): 6–13.
30. Katherine L. Griem, ; Philip K. Robb, et al. Radiation-Induced Sarcoma of the Thyroid.*ArchOtolaryngol Head Neck Surg*. 1989;115(8):991-993.
31. Carvounis.cp. Inferential statistics: the basics .*Handbook of Biostatistics*. 2000. The Parthenon publishing group. New York. p;27-31
32. Amer A Ali .The role of ultrasound in thyroid nodules. *Barsh journal of surgery*. 2011. september.
33. Jeffery R Wienke MD., Wuikchong MD., et al. Sonographic features of benign thyroid nodules. In observer reliability and overlap well malignancy. *Journal of Ultrasound Med*. 2003; 22: 1027–1031,
34. UzmaBhukare, SaleemSadiq, JawidMenon et al. Thyroid carcinoma in Pakistan: a respective review of 998 cases from an academic referral center. *Hematology/Oncology and Stem Cell Therapy*. 2009; 2 (2): 345-348.
35. Mary C. Frates, Carol B. Benson et al. Prevalence and distribution of carcinoma in patients with solitary and multiple thyroid nodules on sonography. *The Journal of Clinical Endocrinology and Metabolism*. 2006; 91 (9): 3411-3417.
36. KamaljitKaur, Nishi Sonkhya, A.S. Bapna, PradeepMital. A comparative study of fine needle aspiration cytology, ultrasonography and radionuclide scan in the management of solitary thyroid nodule: A prospective analysis of fifty cases. *Indian Journal of Otolaryngology and Head & Neck Surgery*. 2002; 54 (2): 96-101.
37. M. Alauddin et al. Management of thyroid carcinoma. An experience in Bangladesh. *Indian Journal Otolaryngology and Head Neck Surg*. 2004; 56(3): 201–205.
38. Popli, et al. Utility of gray-scale ultrasound to differentiate benign from malignant thyroid nodules. *Indian Journal of Radiology and Imaging*.2012;1(22) :63-68.
39. Sao Paulo. Ultrasound findings in thyroidites. *Radiol Bras*. 2007; 40 (2).
40. Wadsworth DT. Thyroglossal duct cysts: variability of sonographic findings. *American Journal of Roentgenology*. 1994 ;163(6):1475-7.

How to cite this article: Jinu CK, Holla K, Mahesh P, Junise M. Diagnostic Accuracy of High Resolutions onography in the Evaluation of thyroid Lesions in a Tertiary Care Centre in Northern Kerala. *Ann. Int. Med. Den. Res*. 2017; 3(2): RD40-RD48.

Source of Support: Nil, **Conflict of Interest:** None declared