

# A Comparative Study of Histopathology of Different Types of Nasal Polyps: Allergic, Inflammatory and Neoplastic.

Pankaj Tripathi<sup>1</sup>, Rajesh Ranjan<sup>2</sup>

<sup>1</sup>Associate Professor, Department of Pathology, TSM Medical College, Anaura, Amausi, Lucknow.

<sup>2</sup>Assistant Professor, Dept of community medicine, Rama medical college.

Received: July 2017

Accepted: August 2017

**Copyright:** © the author(s), publisher. It is an open-access article distributed under the terms of the Creative Commons Attribution Non-Commercial License, which permits unrestricted non-commercial use, distribution, and reproduction in any medium, provided the original work is properly cited.

## ABSTRACT

**Background:** Nasal polyp is a multifactorial disease, with infectious, non-infectious, inflammatory, anatomic and genetic abnormalities. Most theories consider polyps to be the ultimate manifestation of chronic inflammation. **Methods:** A total number of 6250 biopsies from different departments were received at the Department of Pathology for a period of 2 years. The specimens were processed and sections were stained with conventional Haematoxylin and Eosin stain and systematically examined. Toluidine blue staining was carried on sections which were diagnosed as non-neoplastic on H&E. **Results:** Majority of patients were in second (37.5%) and third (12.5%) decades of life. In case of nasal polyp, male patients (30) predominated over female patients (18) with a M:F ratio of 1.7:1. Nasal obstruction was the most common symptom. Most of nasal polyps were lined by pseudostratified ciliated columnar epithelium (79.1%) and had severe oedematous stroma. Out of 18 neoplastic polypoidal lesions, 16 (88.8%) were benign and only 2 (11.2) were malignant neoplasm. **Conclusion:** The use of clinical criteria as a method of selecting nasal polyps for histology proved inadequate as several cases of polyps with sinister pathology would have escaped diagnosis. Routine histology is recommended, as no definite diagnosis on the basis of history and clinical examination is adequate.

**Keywords:** Allergy, Histopathology, Nasal polyp, Neoplasm.

## INTRODUCTION

Nasal polyps were first described more than 3000 years ago and comprise the most common group of mass lesions encountered in the nose. Despite this long history and frequent occurrence, a great many questions still exist with regard to incidence, pathogenesis and treatment.

Nasal polyp is a multifactorial disease, with infectious, non-infectious, inflammatory, anatomic and genetic abnormalities. Most theories consider polyps to be the ultimate manifestation of chronic inflammation.<sup>[1]</sup>

Nasal polyps are essential rounded projections of oedematous mucous membrane. They may develop in association with chronic hypertrophic rhinitis, chronic sinusitis and allergic diseases of the nose. They are solitary or multiple, unilateral or bilateral. They arise most commonly in the ethmoidal air cells are filled by sessile polyp, where polyps that arise from surface mucosa are likely to become

pedunculated. The true nasal polyps are the tumour like non-neoplastic polypoid masses arising from nasal cavity and sinuses. Two types are encountered – one is associated with nasal allergy and numerous eosinophilic infiltration of stroma and other is found in relation to chronic naso-sinusoidal infection termed the inflammatory or granulomatous polyp.<sup>[2]</sup> Clinically, it is quite impossible to distinguish between simple nasal polyps, polypoidal lesions due to specific diseases and polypoidal neoplasms (benign and malignant). For this reason, it becomes important that all polyps and polypoidal lesions of nose should be submitted for histopathological examination.<sup>[3,4]</sup>

In a study, it was reported that meningiomas were polypoid, rubbery in consistency, and in nasal cavity may give the impression of simple polyps. In another study of non-epithelial neoplasms, fibromas of the upper respiratory tract have been described as polypoidal lesions occurring in nasal cavity, pharynx and larynx. It has been said that about one percent of malignant melanoma develops in mucosa of head and neck. The nasal cavity is the commonest site, followed by mouth.<sup>[5]</sup>

Rhabdomyosarcoma is divided into 4 types, which has been generally accepted. Some researchers drew attention to existence of embryonal type of Rhabdomyosarcoma in the head and neck region having a resemblance to the sarcoma botryoides in

### Name & Address of Corresponding Author

Dr. Rajesh Ranjan  
Assistant Professor,  
Dept of community medicine,  
Rama medical college.

infantile genital tract. It is the most common paediatric mesenchymal neoplasm, comprising 50 % of all soft tissue sarcomas in this age group. More than one third is located in head and neck region. In a study of 170 cases of Rhabdomyosarcoma, majority (77.7%) were seen in children less than 12 years of age.<sup>[6]</sup>

The presence of peripheral nerve tumors in the nose and sinuses is present in literature. It was mentioned that peripheral nerve tumors can occur in nose and sinuses and usually of schwannoma type.

Angiectatic nasal polyps should prevent confusion of such lesions with other vascular or spindle cell lesions. A study at Armed forces institute of pathology about oto-laryngeal tumors disclosed 88 cases of sino-nasal polyps with atypical stromal cells over a 20 year period. It was emphasized that cellular atypia in stromal cells of nasal polyps was due to response in fibroblasts or fibro-histiocytes to increased intercellular fluid and vascular compromise.<sup>[7]</sup>

It was reported that rhinosporidiosis is a chronic granulomatous disease in endemic zones of India, including West Bengal. In a study it was reported that allergic fungal sinusitis was most common form of fungal sinusitis. Acute fulminant (invasive) fungal sinusitis is another subtype, caused by etiological agents, belonging to, Mucoraceae – which includes Rhizopus, Mucor and Absidia. It was observed that allergic fungal sinusitis occurs as a spectrum of disease ranging from mild sinus disease and atopy (with or without fungi) to severe expansible sinusitis with extremely high total Immunoglobulin E levels.<sup>[8]</sup>

The earliest description of inverted papilloma was published in 18th century. Ringertz was first to describe the downward (invert) growth of epithelium into stroma, thus giving this tumor its present name of inverted papilloma. Barnes and Bedatti used the term Schneiderian papilloma due to prominent eosinophilic granularity of tumor cells. Pleomorphic adenoma was first reported by Ahlborn in nasal region. The epithet “Mixed” was first introduced by Paget in 1853. It has been stated that pleomorphic adenomas comprise less than 10 percent of all glandular tumors in the nasal region.<sup>[9]</sup>

**MATERIALS AND METHODS**

The present study was undertaken over a period of two years. A total number of 6250 biopsies from different departments were received at the Department of Pathology, out of which 456 biopsies were received from Otorhinolaryngology (ENT) department constituting about 7.2% of all biopsies. 119 biopsies were from nasal cavity, paranasal sinuses and nasopharynx forming 26.09% of ENT biopsies and 1.9% of the biopsies received from other departments.

Attention was paid to record the clinical history and examination findings of each patient in the

proforma. The specimens were processed and sections were stained with conventional Haematoxylin and Eosin stain and systematically examined. Toluidine blue staining was carried on sections which were diagnosed as non-neoplastic on H&E. Mast cells in these polyps was counted in the epithelium and stroma.

Various parameters which were recorded are:

- a) Age and sex of patient.
- b) Clinical presentation of patient.
- c) Laterality of the lesion.
- d) Nature and type of surface epithelium in nasal polyps.
- e) Stroma of nasal polyps.
- f) Inflammatory cell population in stroma of simple nasal polyps.
- g) Types of neoplastic polypoidal lesions.

**RESULTS**

Simple nasal polyp's occurred over a wide age range. The youngest patient was 10 years old and oldest patient was 56 years old. Majority of patients were in second (37.5%) and third (12.5%) decades of life [Figure 1].

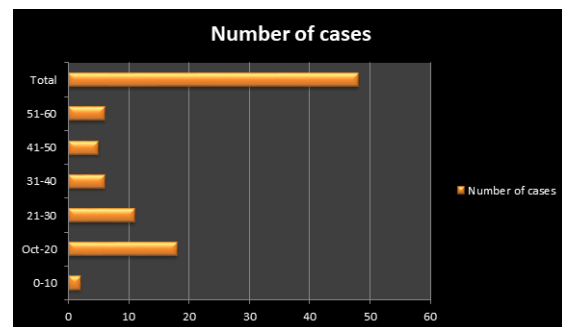


Figure 1: Age incidence of simple nasal polyps.

Table 1: Sex incidence of simple nasal polyps.

Age	Male	Female	Total	Ratio
0-10	1	1	2	1:1
11-20	12	6	18	2:1
21-30	6	5	11	1.2:1
31-40	4	2	6	2:1
41-50	3	2	5	1.5:1
51-60	4	2	6	2:1
Total	30	18	48	1.7:1

In case of nasal polyp, male patients (30) predominated over female patients (18) with a male: female ratio of 1.7:1 [Table 1].

Table 2: Clinical features of polyps and polypoidal lesions.

Clinical Features	No. of Cases
Nasal Obstruction	55
Nasal Mass	18
Allergic Symptoms (Sneezing, Rhinorrhea)	15
Nasal Discharge	
a) Serous	15
b) Mucopurulent	30
Epistaxis	25

In majority of cases, (55 cases) nasal obstruction was the most common symptom. Nasal discharge was

frequently noted in majority of patients (45 cases), of which 30 patients had mucopurulent discharge, while 15 patients had watery discharge. Epistaxis was also noted in 25 patients. Allergic symptoms like sneezing and rhinorrhea were noted in 15 cases. Nasal mass lesions were observed in 18 cases. Majority of polyps and polypoidal lesions presented with multiple symptoms [Table 2].

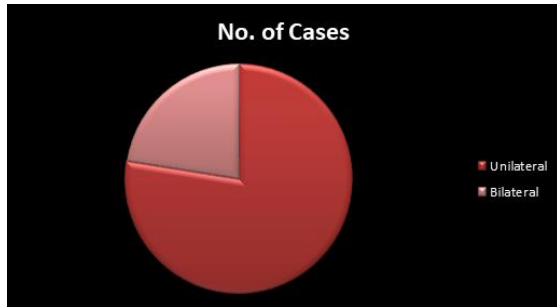

Figure 2: Laterality of nasal polyps and polypoidal lesions.

Table 3: Nature and type of surface epithelium in nasal polyps.

Surface Epithelium	No. of Cases	Percentage
A.	05	10.5
I. Non ulcerated		
II. Ulcerated	43	89.5
Total	48	100.0
B.	38	79.1
I. Pseudostratified ciliated columnar epithelium		
II. Squamous epithelium	9	18.8
III. Transitional epithelium	1	2.1
Total	48	100.0

Most of nasal polyps were lined by pseudostratified ciliated columnar epithelium (79.1%) and had severe oedematous stroma. [Table 3,4].

Table 4: Stroma of nasal polyps.

Stroma	Severe (%)	Moderate (%)	Minimal (%)	Nil (%)
Oedematous	22 (45.8)	14 (29.2)	9 (18.7)	3 (6.3)
Vascular	8 (16.7)	16 (33.3)	24 (50.0)	-
Fibrosis	5 (10.3)	2 (4.2)	3 (6.3)	38 (79.2)

Table 5: Inflammatory cell population in stroma of simple nasal polyps.

Cells	Dense (%)	Moderate (%)	Scanty (%)
Lymphocytes	32 (66.7)	6 (12.5)	10 (20.8)
Plasma Cells	16 (33.3)	24 (50.0)	8 (16.7)
Mast Cells	7 (14.6)	5 (10.4)	36 (75.0)
Macrophages	1 (2.1)	4 (8.3)	43 (89.6)
Polymorphs	2 (4.2)	4 (8.3)	42 (87.5)
Eosinophils	12 (25.0)	22 (45.8)	14 (29.2)

The type and density of inflammatory cell population was observed. Majority of the polyps had

lymphocytes, plasma cells, eosinophils, neutrophils and macrophages. Most polyps had a dense infiltrate of eosinophils, lymphocytes and plasma cells. Neutrophils and macrophages were scanty in most polyps. Average number of cells 7.5 hpf was taken to approximately quantitate the inflammatory cell population as dense (>50) moderate (30-50) and scanty (<50) [Table 5].

Table 6: Types of neoplastic polypoidal lesions.

A.	Benign	No. of Cases	Percentage
a.	Epitheloid haemangioendothelioma	1	5.5
b.	Capillary haemangioma	5	27.8
c.	Angiofibroma	1	5.5
d.	Inverted papilloma	8	44.5
e.	Nasal glioma	1	5.5
Total		16	88.8
B.	Malignant		
a.	Olfactory neuroblastoma	1	5.6
b.	Undifferentiated nasopharyngeal carcinoma	1	5.6
Total		2	11.2

Out of 18 neoplastic polypoidal lesions, 16 (88.8%) were benign and only 2 (11.2) were malignant neoplasm. In 16 (88.8%) benign lesions presenting as polypoidal lesions, Inverted papilloma (8cases) and Capillary haemangioma (5 Cases) were the most frequent benign tumours followed by Epitheloid haemangioendothelioma (1 case), Angiofibroma (1 case), Nasal glioma (1case). Out of the 2 (11.2) malignant lesions presenting as polypoidal masses a solitary case of undifferentiated nasopharyngeal carcinoma and a solitary case of olfactory neuroblastoma was detected [Table 6].

## DISCUSSION

Polyps and polypoidal mass in nose and nasal sinuses are very common lesions encountered in clinical practice. It may be due to most frequently occurring simple nasal polyps or polypoidal lesions due to a variety of other pathologic entities ranging from infective granulomatous disease to polypoidal neoplasm including malignant ones.<sup>[10]</sup>

The nose and nasal sinuses are exposed to a variety of infections, chemically agitating, antigenically stimulating, mechanical, and traumatic and many other influences.

Although majority of nasal polyps sent for histology are inflammatory secondary to infection, allergy or idiopathic causes; a variety of clinical conditions, also present as nasal polyps ranging from benign lesions to malignant nasal tumors. Therefore an assessment of a clinician's ability to distinguish between 'common' nasal polyps and those of sinister aetiology is needed to determine the benefit of

ending nasal polyps for histo-pathological examination.<sup>[11]</sup>

In the present study, male to female ratio was 1.7:1, with a male predominance. Ratio of male in the study group of Vento et al,<sup>[12]</sup> is 2.4:1 (82 males and 33 females) and Diamantopoulos I et al,<sup>[13]</sup> showed male to female ratio of 3.3:1 (57 males and 17 females). According to Kirtsreesakul. V there is a strong male predominance with a ratio between 2:1 and 4:1. In most of the studies discussed so far, male predominance was noted.

Histological analysis of epithelium of nasal polyps in the present study showed ulceration in 89.7% of polyps. Majority of the polyps are lined by Pseudostratified ciliated columnar epithelium in 25 cases (86.2%). As in present study, ulceration of epithelium found in majority of cases may be due to trauma or due to pressure of enlarging polyps against rigid structures causing devitalization.

In a study by Stamm AC et al,<sup>[1]</sup> 62% of nasal polyps (65 cases) were lined by pseudostratified ciliated columnar epithelium with goblet cells and ciliary cells. In anterior nasal polyps, some have reported the finding of stratified squamous non-keratinized epithelium or transitional epithelium also.

In a study by Ruhno J et al 46% of polyps were lined by ciliated columnar epithelium and almost 113 cases (100%) showed ulceration of surface epithelium in nasal polyps.<sup>[9]</sup> In a study conducted by Triglia JM et al,<sup>[7]</sup> microscopically, the polyps had a ciliated respiratory epithelium but often surface ulceration was seen. Many studies on the histology of nasal polyps have described that they have a respiratory epithelium with pseudostratified ciliated columnar cells and goblet cells. According to Stamm AC et al,<sup>[1]</sup> the surface epithelium is composed of intact respiratory epithelium, but may also show squamous metaplasia.

In the present study, significant feature was the constant presence of inflammatory cells in the stroma of nasal polyps. Most polyps in present study showed varying degree of cellular infiltrate consisting of eosinophils, lymphocytes stroma cells and mast cells. Macrophages and neutrophils were scanty in majority of cases.

Various attempts to subgroup nasal polyps on a histological basis were totally unsuccessful. Histopathologists often face difficulty in subgrouping the nasal polyps as allergic and non-allergic,<sup>[6]</sup> or as inflammatory polyp and allergic polyp.<sup>[7]</sup>

Mygind classified polyps into two groups, those containing large number of eosinophils and those containing large number of neutrophils. In the present study, we could not classify polyps into eosinophil or neutrophil polyps as by Mygind because in majority of the polyps eosinophils were present. It is tempting to classify to eosinophils polyps as allergic because they were often associated

with asthma and perennial climates, but relationship between polyps and allergy is not clear.

Lathi et al stated that allergy was a causal factor in the development of nasal polyps, however many other authors have considered the relationship to be co-incident.<sup>[2]</sup>

Patients with polyps have about the same prevalence of positive skin tests as does the normal population. Additional evidence against the hypothesis of allergy as a causal factor is that polyps seldom occur in children or young adults with atopic hay fever and allergic asthma. Nasal polyps arising in non-allergic group also showed significant number of eosinophils.

In a study conducted by Stamm et al,<sup>[1]</sup> 10.6% were allergic polyps and 31.9% non-allergic or inflammatory polyps, the rest being mixed type.

In the study by Zafar U et al,<sup>[3]</sup> lymphocytes plasma cells and macrophages were present in moderate number in 61.1%, 70.8% and 67.3% instances respectively. Eosinophils were present in 48.7% of cases and rest of polyps showed presence of moderate to poor eosinophils. In majority of cases plenty to moderate number of mast presence in 58.4% cases.

## CONCLUSION

The clinical information on the requisition form and diagnosis made by the clinician was compared with final histopathological diagnosis. The use of clinical criteria as a method of selecting nasal polyps for histology proved inadequate as several cases of polyps with sinister pathology would have escaped diagnosis. Routine histology is recommended, as no definite diagnosis on the basis of history and clinical examination is adequate.

## REFERENCES

1. Stamm AC, Draf W. Microendoscopic Surgery of Paranasal Sinuses and the Skull Base. New York: Springer, 2000.
2. Lathi, M.M.A. Syed, P. Kalakoti, D. Qutub. Clinicopathological profile of sinonasal masses: a study from a tertiary care hospital of India. ACTA otorhinolaryngologica ita lica 2011;31:372-377
3. U. Zafar, N. Khan, N. Afroz, S. A. Hasan. Clinicopathological study of non-neoplastic lesions of nasal cavity and paranasal sinuses. Indian J Pathol Microbiol. 2008 Jan-Mar;51(1):26-9.
4. S. Shulbha, B. S. Dayananda. Clinicopathological study of nasal polyps with special reference to mast cells in inflammatory polyps. Basic and Applied Pathology 2012; 5: 59-62.
5. Mysorekar VV, Dandekar CP, Rao SG. Mast cell quantitation in non neoplastic polypoidal nasal lesions. Indian Journal of Otolaryngology and Head and Neck Surgery 2004;56(2):87-8.
6. Kale USU, Mohite D, Rowlands, Lee DAB. Clinical and histopathological correlation of nasal polyps: are there any surprises? Clin Otolaryngol 2001;26:321-3.
7. Triglia JM, Nicollas R. Nasal and sinus polyposis in children. Laryngoscope 1997; 107: 963-6.

8. Gustavo F Couto , A M Fernades , D F Brandão , D S Neto. Histological Aspects of Rhinosinusal Polyps. Rev Bras Otorrinolaringology 2008;74(2):207-12.
9. Ruhno J, Howie K, Anderson M, Anderson B, Vanzielegem M, Hitch D, et al. The increased number of epithelial mast cells in nasal polyps and adjacent turbinates is not allergy dependent. Allergy 1990;45(5):370-4.
10. Otsuka H, Ohkubok K, Seki H, Ohnishi M, Fujikura T. Mast cell quantitation in nasal polyps, sinus mucosa and nasal turbinate mucosa. J Laryngol Otol 1993;107(5):418-22.
11. Zhang G, Shao J, Su C et al. Distribution change of mast cells in human nasal polyps. Anat Rec (Hoboken) 2012; 295: 758–63.
12. Vento SI, Wolff CHJ, Salven PJ, Hytomen ML. Vascular permeability factor / vascular endothelial growth factor in nasal polyps. Acta Oto-Laryngologica 2000;120:170-4.
13. Diamantopoulos I, Jones NS, Lowe J. All nasal polyps need histopathological examination: an audit based appraisal of clinical practice. Journal of Laryngology and Otology 2000;114:755-9.

**How to cite this article:** Tripathi P, Ranjan R. A comparative study of histopathology of different types of nasal polyps: Allergic, Inflammatory and Neoplastic. Ann. Int. Med. Den. Res. 2017; 3(6):PT41-PT45.

**Source of Support:** Nil, **Conflict of Interest:** None declared