

## A Tripod of Metastasis in a Case of Osteosarcoma.

Monika Singh<sup>1</sup>, Swasti Shubham<sup>2</sup>, Udit Chauhan<sup>3</sup>, Ajay Kr Singh<sup>4</sup>

<sup>1</sup>Senior Resident, Department of Pathology, Dr RML Hospital and PGIMER, New Delhi, India.

<sup>2</sup>Assistant Professor, Department of Pathology, People's College of Medical Sciences and Research Centres, Bhanpur, Bhopal, Madhya Pradesh, India.

<sup>3</sup>Senior Resident, Department of Radiology, GB Pant Hospital, New Delhi, India.

<sup>4</sup>Associate Professor, Department of Pathology, KGMU, Lucknow, Uttar Pradesh, India.

Received: March 2017

Accepted: April 2017

**Copyright:** © the author(s), publisher. It is an open-access article distributed under the terms of the Creative Commons Attribution Non-Commercial License, which permits unrestricted non-commercial use, distribution, and reproduction in any medium, provided the original work is properly cited.

### ABSTRACT

Osteosarcoma is the most common primary bone tumor arising from mesenchymal bone forming cells. The most frequent sites of metastasis are lungs, bones and kidneys. Osteosarcomas rarely metastasize to scalp and pleura. Here, we report a case of a 65-year-old male patient with complaints of shortness of breath and painful swelling in right knee joint and also a small nodule on scalp. Contrast enhanced computed tomography (CECT) of thorax revealed irregular pleural lesions causing indentation over underlying lung parenchyma on both side while CT abdomen revealed metastatic lesion in liver. Patient came to our department for FNAC from swelling right knee and scalp nodule. Later pleural biopsy was also received of the same patient. A final diagnosis of osteosarcoma of the right knee joint was made with scalp, and pleural metastasis. This case underlines the importance of warranting further investigations for search of unusual sites of metastasis from osteosarcoma.

**Keywords:** Osteosarcoma, scalp, pleura, liver, metastasis.

### INTRODUCTION

Osteosarcoma is the most common, non-haematopoietic, primary malignant tumour of bone. Most common age group of presentation is adolescent period with a second smaller peak in 7th to 8th decade of life.<sup>[1,2]</sup> The most common sites of metastasis from osteosarcoma are lung and bone.<sup>[3]</sup> Skin and pleura are rare sites of metastasis from an osteosarcoma. Herein we present a rare case of osteosarcoma with tripod of metastasis to scalp, pleura and liver.

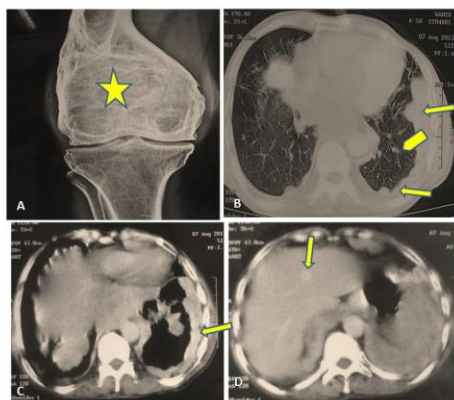
#### Name & Address of Corresponding Author

Dr. Monika Singh,  
Senior Resident,  
Department of Pathology,  
Dr. RML Hospital and PGIMER, New Delhi, India

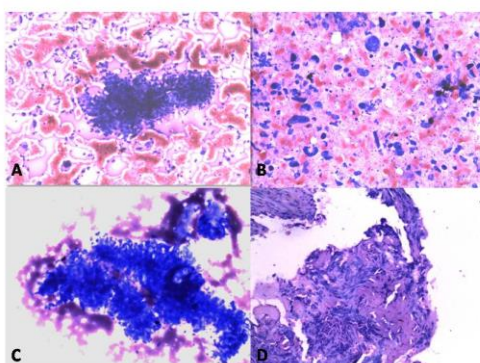
### CASE REPORT

A 65 year old male presented to Pulmonary OPD with history of breathlessness and right knee swelling. On detailed clinical history of patient it was observed that the knee swelling was from last 6 months followed by breathlessness since last two months. Patient was a known smoker and tobacco chewer. There was no history of tuberculosis or any exposure, neither of any significant trauma. Family history was not significant. On general physical examination a small nodule measuring 1.5x1cm in size was noticed on the scalp. Routine hematological examination and biochemical tests were

unremarkable. On radiological examination, x-ray right knee revealed a lytic lesion in the lower end of right femur [Figure 1a]. Following these investigations a FNAC from both knee and scalp swelling was done which yielded blood mixed cellular aspirate. The slides were stained with Hematoxylin and Eosin (H&E) stain. FNAC smears from the swellings i.e, knee and scalp showed similar cytomorphological picture with of clusters of malignant spindle shaped tumour cells and osteoid material in a hemorrhagic background [Figure 2a, b, & c]. A final cytological diagnosis of osteosarcoma with cutaneous metastasis was rendered. Following this a radiological work up for distance metastasis was done. CT scan of thorax showed metastatic foci in the lung along with a lesion in the pleura overlying the lung foci [Figure 1b & c] while, on mediastinal window small hyperdense lesion noted in segment IV of liver was highly suggestive of metastases [Figure 1d]. A pleural biopsy was obtained. Histopathological examination of pleural biopsy revealed sheets and clusters of atypical, pleomorphic, spindle to oval cells with high nucleocytoplasmic ratio lying in a fibro-connective tissue [Figure 2d]. Histomorphology was consistent with metastatic osteosarcoma. Hepatic mass lesion could not be biopsied as patient's condition deteriorated rapidly.



[Figure 1]: (a) A well-defined lytic expansile lesion is seen in lower end of femur involving the metaphyseal region reaching short of epiphysis with wide zone of transition. CECT chest in the lung window (b) and mediastinal window (c and d) reveals diffuse nodular pleural thickening in bilateral lower lungs (arrows in b and c) with small nodular lesions in left lower lobe (arrow head in b) consistent with pleural and pulmonary metastases. Small hyperdense lesion noted in segment IV of liver (arrow in 'd') is highly suggestive of metastases.



[Figure 2]: (a and b) FNA smears from the knee swelling showing spindle shaped hyperchromatic cells with background osteoid and blood.(H&E, 40x and 200x).(c)FNA smears from scalp nodule show similar cytomorphological features with relatively scant osteoid. (H&E, 400x). Smears from scalp nodule.(d) pleural biopsy showing crush artefact, however presence of atypical hyperchromatic spindle cells can be seen(H&E,200x) .

## DISCUSSION

Osteosarcoma is the most common, non-haematopoietic, primary malignant tumour of bone that occurs predominantly in the metaphysis of the long bones. Osteosarcoma represents approximately 55% of childhood and adolescent malignant bone tumours.<sup>[1]</sup> A second, smaller peak is observed during the seventh and eighth decades of life as in our case.<sup>[2]</sup> Apart from the conventional osteosarcomas (osteoblastic, chondroblastic, and fibroblastic) a number of variants occur including telangiectatic, multifocal, parosteal, and periosteal.

The most common sites of metastasis from osteosarcoma are lung and bone.<sup>[3]</sup> Osteosarcomas dramatically respond to therapy. Skin metastasis from a sarcoma is rarer, compared with their epithelial counterparts ranging from 1% to 2.6% of all cutaneous metastases.<sup>[4,5]</sup> Sarcomas involving skin are, leiomyosarcoma, Ewing sarcoma, and extraskeletal osteosarcoma.<sup>[6-8]</sup> In few studies it is observed that skin metastases of osteosarcomas develops distant to the site of primary tumour as seen in our case, which is in contrast to many types of carcinomas, in which regional skin metastases are the more common presentation. Most of such metastases occur late in the disease course, and herald a poor prognosis.<sup>[9]</sup> Although cutaneous metastatic osteosarcoma is rare metastases it shows a predilection for the upper body, particularly the head and neck region (70%) similar to our case. Osteosarcoma spread from bone is deemed to be hematogenous rather than lymphatic as bone is devoid of lymphatic vessels.<sup>[10,11]</sup> Therefore, the predilection for metastasis to the scalp (lung and liver) is likely due to the generous blood supply in this region. Pleural metastasis is a rare phenomenon in metastatic lung osteosarcomas in contrary to metastatic carcinoma of lung.<sup>[12]</sup>

Two pathways can be hypothesized for pleural metastasis in patients with osteosarcoma: (1) By direct contact of pleura with the lung parenchyma and (2) haematogenous spread from the primary site or metastatic lung osteosarcoma. It is difficult to comment upon about the origin of pleural metastasis in our patient as the metastatic pleural tumour could be originating from the contact with lung tumour rather than a haematogenous spread or dissemination. The points in favour of the spread from direct contact with lung tumour surface are (1) The pleural nodule came into contact with lung surface during ventilation (2) Absence of mesothelial covering in pleural surfaces. Although we cannot completely deny the haematogenous spread or dissemination but as in our case it can be summarized that a metastatic pleural osteosarcoma can originate from 'Kissing Metastases' to the pleura from the surface of lung tumour.

## CONCLUSION

To conclude, one should be suspicious of new cutaneous lesions in patients with osteosarcoma, and regard new lesions as metastases until proven otherwise. Pleural cavity should be looked into carefully in every patient of osteosarcoma. Whenever a metastasizing cutaneous or pleural tumour is found, it should be resected completely which could improve the prognosis of patients and prevent recurrences and failure to therapy.

## REFERENCES

1. L. Mirabello, R. J. Troisi, and S. A. Savage, "Osteosarcoma incidence and survival rates from 1973 to 2004: data from the surveillance, epidemiology, and end results program," *Cancer*, vol. 115, no. 7, pp. 1531–1543, 2009.
2. L. Mirabello, R. J. Troisi, and S. A. Savage, "International osteosarcoma incidence patterns in children and adolescents, middle ages and elderly persons," *International Journal of Cancer*, vol. 125, no. 1, pp. 229–234, 2009.
3. Jeffree GM, Price CH, Sissons HA. The metastatic patterns of osteosarcoma. *Br J Cancer*. 1975;32:87–107.
4. Saeed S, Keehn CA, Morgan MB. Cutaneous metastasis: a clinical, pathological, and immunohistochemical appraisal. *J Cutan Pathol*. 2004; 31:419-430.
5. Brownstein MH, Helwig EB. Metastatic tumors of the skin. *Cancer*. 1972;29:1298-1307.
6. Biswas G, Khadwal A, Kulkarni P, et al. Ewing's sarcoma with cutaneous metastasis—a rare entity: report of 3 cases. *Indian J Dermatol Venereol Leprol*. 2005;71:423-425.
7. Covello SP, Humphreys TR, Lee JB. A case of extraskeletal osteosarcoma with metastasis to the skin. *J Am Acad Dermatol*. 2003;49:124-127.
8. Vandergriff T, Krathen RA, Orengo I. Cutaneous metastasis of leiomyosarcoma. *Dermatol Surg*. 2007;33:634-637.
9. Wei-Lien Wang, Ross A. Bones-Valentin, Victor G. Prieto, et al. Sarcoma Metastases to the Skin; A Clinicopathologic Study of 65 Patients
10. American Cancer Society "What are the key statistics about bone cancer?" Available at: <http://www.cancer.org/Cancer/BoneCancer/DetailedGuide/bone-cancer-key-statistics>. Accessed September 2010.
11. Pappo A, Vassal G. SARC 011:R1507 in refractory sarcomas. Sarcoma Alliance for Research and Collaboration. Available at: [www.sarctrials.org/SARC011r1507](http://www.sarctrials.org/SARC011r1507). Accessed August 2010
12. Takeshi Mori, Maasakazu Yoshioka, Kazunori Iwatani, et al. Kissing Pleural Metastases from Metastatic Osteosarcoma of The Lung . *Ann Thorac Cardiovasc Surg*. 2006;12:129-132.

**How to cite this article:** Singh M, Shubham S, Chauhan U, Singh AK. A Tripod of Metastasis in a Case of Osteosarcoma. *Ann. Int. Med. Den. Res.* 2017; 3(3):PT24-PT24.

**Source of Support:** Nil, **Conflict of Interest:** None declared