

Clear Cell Cribriform Hyperplasia of Prostate- A Case Report.

Poonam Singal¹, Jasneet Kaur², Ramesh Kumar Kundal³, Harpal Singh⁴

¹Senior Resident, Department of Pathology, Government Medical College, Patiala.

²Junior Resident, Department of Pathology, Government Medical College, Patiala.

³Professor and Head, Department of Pathology, Government Medical College, Patiala.

⁴Associate Professor, Department of Pathology, Government Medical College, Patiala.

Received: April 2017

Accepted: April 2017

Copyright: © the author(s), publisher. It is an open-access article distributed under the terms of the Creative Commons Attribution Non-Commercial License, which permits unrestricted non-commercial use, distribution, and reproduction in any medium, provided the original work is properly cited.

ABSTRACT

Prostatic lesions with cribriform pattern pose a challenging differential diagnosis between clear cell cribriform hyperplasia prostate, cribriform intraepithelial neoplasia and cribriform prostatic carcinoma. We discuss a case presenting with urinary hesitancy and difficulty in micturition who underwent transurethral resection of prostate. Careful histopathological examination of the lesion along with the use of immunohistochemistry helped in the correct diagnosis of clear cell cribriform hyperplasia of prostate which is an uncommon variant of benign hyperplasia prostate. Awareness of this entity is important to avoid any misdiagnosis which can lead to wrong clinical management.

Keywords: Clear cell hyperplasia, intraepithelial neoplasia, Prostatic adenocarcinoma.

INTRODUCTION

Prostate lesions with cribriform / pseudocribriform architecture represent a broad spectrum of entities, varying from normal histological structures or benign lesions to premalignant lesions and frank malignancies. Diagnostic classification of cribriform glands is one of the most difficult problems facing the general pathologist and even the uropathologist, especially in quantitatively limited tissue fragments.^[1]

Clear cell cribriform hyperplasia (CCCH) of the prostate is a rare form of benign nodular hyperplasia of the prostate. It was recognized by the World Health Organization in 1980 and described as florid benign papillary/ciabriform hyperplasia of prostate by Gleason in 1985.^[2,3] It is characterized by a nodular proliferation of clear cells with small, uniform nuclei, and inconspicuous nucleoli and can be misdiagnosed as prostatic cancer or prostatic intraepithelial neoplasia, potentially leading to a wrong clinical management of the patient.

Name & Address of Corresponding Author

Dr. Poonam Singal,
Senior Resident,
Department of Pathology,
Govt. Medical College, Patiala.

difficulty in micturition along with burning micturition since 3 months. There was no complaint of hematuria, loss of weight or loss of appetite. Serum PSA level was done and found to be 0.09 µg/L. Ultrasound examination revealed grade II prostatic hyperplasia along with presence of corpora amylacea. Transurethral resection of prostate was done and prostate chips were received for histopathological examination. H&E staining of sections revealed a lesion characterized by a proliferation of complex glands with majority of cells containing clear cytoplasm, small nuclei and inconspicuous nucleoli. Some of the glands revealed cribriform pattern of growth in the lumen. [Figure 1 & 2]. At this stage, differential diagnosis considered were – clear cell cribriform hyperplasia of prostate, prostate intraepithelial neoplasia and cribriform prostatic adenocarcinoma. The differentiation between cribriform hyperplasia and prostatic intraepithelial neoplasia was done on the basis of lack of cellular atypia and inconspicuous nucleoli. On thorough examination, there was seen an intact row of basal cells in the lining of all the prostatic acini. Which was further confirmed by 34 β E 12 anti-keratin antibody [Figure 3] which reacts with basal cells, thereby ruling out prostatic adenocarcinoma. So, the diagnosis of clear cell cribriform hyperplasia was made.

CASE REPORT

A 60 years old man presented to the urology clinic with the chief complaints of urinary hesitancy,

DISCUSSION

Pseudoneoplastic lesions in the prostate include those of prostatic epithelial origin, the most common

being atrophy, adenosis (atypical adenomatous hyperplasia), basal cell hyperplasia, and crowded benign glands, as well as those of nonprostatic origin, such as seminal vesicle epithelium. Such lesions often mimic lower grade prostatic adenocarcinoma, whereas others, such as clear cell cribriform hyperplasia and granulomatous prostatitis, for example, are in the differential diagnosis of Gleason adenocarcinoma, Gleason grade 4 or 5.^[3]

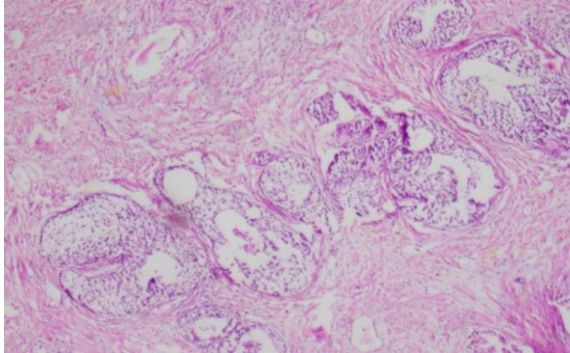


Figure 1: Section showing clear cell cribriform hyperplasia. (H & E stain x 100).

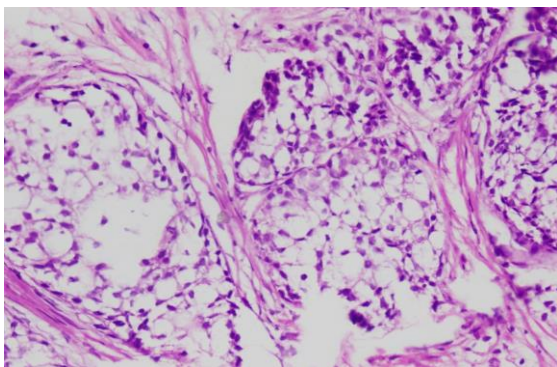


Figure 2: Section showing high power view of clear cells in acini with cribriform architecture.(H & E x 400)

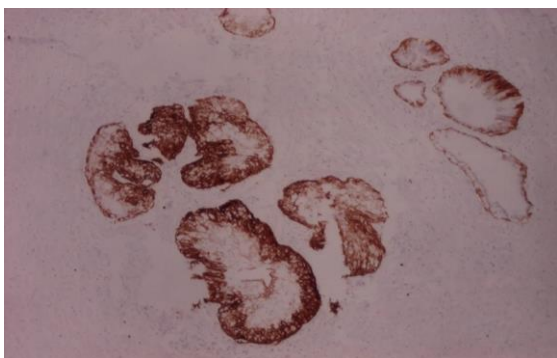


Figure 3: Positivity of basal cell layer of prostatic acini with 34 β E 12 anti-high molecular weight keratin antibody (Immunoperoxidase with haematoxylin counterstain x 400).

Clear cell cribriform hyperplasia is usually seen in the transitional zone as part of benign nodular epithelial hyperplasia. Pathologically, this lesion has a cribriform arrangement of clear cells with a

complex papillary growth simulating the cribriform pattern of prostatic carcinoma. Cytologically, however, there is no nuclear atypia, mitosis, or prominent nucleoli, and typically there is a double epithelial cell layer at the periphery of the involved acini.^[7] In most instances, the cribriform glands have uniform round lumina and clear cytoplasm, hence the name “clear cell cribriform hyperplasia”. At low power the lesion generally has a nodular appearance and intervening cellular stroma is seen.^[4]

Basal cell markers like 34 β E12 anti-high-molecular-weight keratin antibody, are not very helpful in discriminating cribriform hyperplasia from architectural similar foci of high grade PIN since both entities may present a patchy peripheral basal cell layer. The discrimination of the two lesions is therefore based on the evaluation of nuclear atypia, which lacks in the hyperplastic glands and is present in PIN.^[5,6]

The prognosis of CCCH is good as reported by Ayala AG et al who followed up 10 patients in their study and found that all the patients were alive and had shown no evidence of recurrent disease.^[7] Follow-ups ranged from 1 month to 7 years (median: 12.5 months; mean: 24.6 months). In fact, in five of the 10 cases, the referring diagnosis was either carcinoma or possible carcinoma. They concluded that the key feature for the diagnosis is the preservation of nodular configuration with a bland cytology and double cell layer lining the involved acini.

It is important to notice that a misdiagnosis of Gleason grade 4 prostatic carcinoma would have resulted in the patient been offered a radical prostatectomy or radical radiotherapy resulting in an unnecessary treatment. Moreover a misdiagnosis of high grade PIN would have been followed by unnecessary repeat prostatic biopsies. In this case instead the patient will be followed up with yearly PSA level monitoring.

CONCLUSION

Cribriform hyperplasia is a form of benign prostatic hyperplasia that can be misdiagnosed for prostatic carcinoma or cribriform PIN. Awareness of this histological entity is important for correct diagnosis and consequent patient management.

REFERENCES

1. Dema A, Borda A, Lazar E, Lazureanu C, Taban S, AndercoD, et al. Prostate lesions with cribriform/pseudocribriform pattern. Rom J MorpholEmbryol 2010;51:413-425.
2. Mostofi FK, Sesterhenn I, Sobin LH. Histological typing of prostate tumor. Geneva: World Health Organization, 1980:17-23 (International Histological Classification of Tumors, No. 22).

3. Gleason DF. Atypical hyperplasia, benign hyperplasia, and well-differentiated adenocarcinoma of the prostate. *Am J Surg Pathol* 1985;9(Suppl):53-57. 3
4. Fraumeni EE, Ro JY, el-Naggar AK, Ordóñez NG, Ayala AG. Clear cell cribriform hyperplasia of the prostate. Immunohistochemical and DNA flow cytometric study. *Am J Clin Pathol* 1991;95:446-453.
5. Hameed O, Humphrey PA. Pseudoneoplastic mimics of prostate and bladder carcinomas. *Arch Pathol Lab Med* 2010;134:427-443.
6. Bostwick DG, Ma J. Over-diagnosis of high-grade prostatic intraepithelial neoplasia: a prospective study of 251 cases. *BJU Int* 2007; 100:1036-1039.
7. Ayala AG, Srigley JR, Ro JY, Abdul-Karim FW, Johnson DE. Clear cell cribriform hyperplasia of prostate. Report of 10 cases. *Am J Surg Pathol*. 1986 Oct;10(10):665-7

How to cite this article: Singal P, Kaur J, Kundal RK, Singh H. Clear Cell Cribriform Hyperplasia of Prostate- A Case Report. *Ann. Int. Med. Den. Res.* 2017; 3(4):PT25-PT27.

Source of Support: Nil, **Conflict of Interest:** None declared