

Rosai-Dorfman Disease of Extranodal Site.

Sucheta Yadav¹, Atin Singhai², Suresh Babu³

¹Postgraduate Department of Pathology KGMU Lucknow.

²Assistant Professor Department of Pathology KGMU Lucknow.

³Associate Professor Department of Pathology KGMU Lucknow.

Received: July 2017

Accepted: July 2017

Copyright: © the author(s), publisher. It is an open-access article distributed under the terms of the Creative Commons Attribution Non-Commercial License, which permits unrestricted non-commercial use, distribution, and reproduction in any medium, provided the original work is properly cited.

ABSTRACT

Rosai-Dorfman disease is a rare benign disorder of lymph nodes in which histiocytic proliferation occurs, usually seen in early decades of life. In few cases extranodal involvement has been seen with or without lymphadenopathy. A 28 year old male presented with preauricular ill-defined swelling with central area showing redness and ulceration without any clinically evident lymphadenopathy. On the basis of fine needle aspiration cytology findings of singly scattered as well as multinucleated histiocytes with abundant pale blue cytoplasm containing lipid droplets and vesicular nuclei, demonstrating phagocytosis of inflammatory cells at places, we reported our case as Rosai-Dorfman disease of extranodal site. Treatment modalities include surgical excision, chemo-radiotherapy and steroids. It varies according to clinical presentation of patient and responsiveness to treatment.

Keywords: Lymph node, Rosai-Dorfman disease.

INTRODUCTION

Sinus histiocytosis with multiple lymphadenopathy or Rosai-Dorfman disease is a human disorder of unknown cause, clinically presents with swelling of multiple lymph nodes.^[1] It mainly affects the younger population with slight male predominance. It is usually benign but in chronic and rare cases, it can metastasize to other parts of body via lymphatic system. Histiocytosis refers to excess production and accumulation of histiocytes. Histiocytes are macrophages released by littoral cells lining inner endothelial wall of lymph nodes. Function of histiocytes is filtering or trapping foreign particles and pathogens within lymph sinus. Sinus histiocytosis that has spread to sites other than lymph nodes is known as extranodal, and it occurs in about one fourth of all cases. Clinical presentation depends upon the site of occurrence.^[1] Extra nodal sites involved by disease include skin, subcutaneous tissue, bone, skeletal muscle, thyroid, liver, kidney, heart, uterine cervix, nasal cavity, paranasal sinuses, nasopharynx, submandibular gland, breast, parotid gland, larynx, temporal bone, pterygoid fossa, infratemporal fossa, meninges and orbital region.^[2,3] In most of the patients there is involvement of more than one site. Usually it follows benign clinical course, with spontaneous resolution. If there is any

Long term ill effect that does not resolve on its own, it implies searching for other reactive conditions like any infective aetiology. In case of extra nodal involvement, disease mimics malignant cancer in fair number of cases. The period of exacerbation and remission also depict the malignancy. The management modalities include prompt diagnosis, surgical excision, steroid therapy and radiation, depending on the clinical condition of patient.^[4,5]

CASE REPORT

A 28 year old male presented with recurrent left preauricular swelling which had persisted for one year. [Figure 1a] The patient had no history of fever, tuberculosis or loss of body weight. On examination diffuse, tender and movable 3x3 cm preauricular ill-defined swelling was found. There was a cystic, raised reddish area over the centre of swelling. There was no lymphadenopathy in the cervical or other sites. Fine needle aspiration cytology (FNAC) was performed one year before and diagnosis of pyogenic abscess was made.

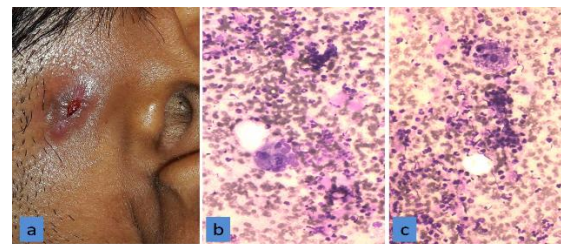


Figure 1a: Ill-defined inflamed preauricular lesion, **Figure 1b,c:** Emperipolesis of inflammatory cells by histiocytes amidst necrotic and haemorrhagic background.

Name & Address of Corresponding Author

Dr. Sucheta Yadav,
Postgraduate
Department of Pathology
KGMU
Lucknow.

Investigations

Sonography of region showed solid hypoechoic, hypervascular lesion with few central area showing necrocystic changes with dense internal echoes. Aspiration was re-performed from the same site and smears revealed high cellularity with prominent mixed inflammatory infiltrate comprising of polymorphs, lymphocytes, plasma cells as well as few eosinophils. There was also evidence of fair number of singly scattered as well as multinucleated histiocytes with abundant pale blue cytoplasm containing lipid droplets and vesicular nuclei. These histiocytes also demonstrated emperipolesis in form of phagocytosis of lymphocytes, polymorphs and plasma cells at places. [Figure 1b,c] Acid fast bacilli and Gram's staining were also performed which showed negative results.

Differential Diagnosis

The chief differential diagnoses on clinico-radiological examination were Rosai-Dorfman disease, pyogenic abscess with underlying infective aetiology and lymphoma. Study of aspiration smears clearly ruled out possibility of lymphoma and any underlying infection. Cytological features were in favour of Rosai-Dorfman disease, however because of absence of any apparent lymphadenopathy, the final diagnosis was framed as Rosai-Dorfman disease of extranodal site.

Treatment

Treatment modalities include surgical excision with or without adjuvant chemo-radiotherapy and steroids. It varies according to clinical presentation of patient and responsiveness to treatment. Steroid therapy in form of low dose cortisone was started in this patient.

Outcome And Follow-UP

Patient showed marked clinical improvement in following 2-3 weeks

DISCUSSION

On the basis of FNAC smears of the preauricular swelling, sinus histiocytosis was diagnosed. The smear showed multinucleated histiocytes with abundant pale blue cytoplasm containing lipid droplets and vesicular nuclei which demonstrated phagocytosis. Sometimes such cases are misdiagnosed or over diagnosed as lymphoma and other causes of histiocytosis. Because of different treatment modalities, it is necessary to differentiate sinus histiocytosis from lymphoma and other causes of histiocytosis. The clinical presentation of sinus histiocytosis with multiple lymphadenopathy or Rosai-Dorfman disease is painless, bilateral cervical lymphadenopathy with fever, leucocytosis, raised erythrocyte sedimentation rate, and hypergammaglobulinemia. In recent years extranodal presentation has been increasingly seen.

Pathogenesis of this disease is unknown but its relation with an infectious aetiology and/or immunodeficient state has been stipulated. In our case we diagnosed extranodal manifestation of Rosai-Dorfman disease in preauricular region without any lymphadenopathy, which responded to steroid therapy.

CONCLUSION**Learning Points/Take Home Messages**

- Rosai-Dorfman disease may present without lymphadenopathy at an extranodal site too.
- Fine needle aspiration cytology is concluded as a useful and reliable method for diagnosing this entity.
- It reduces inconvenience to patients by avoiding unnecessary biopsy.

REFERENCES

1. Das DK, Gulati A, Bhatt NC, Sethi GR. Sinus histiocytosis with massive lymphadenopathy (Rosai-Dorfman disease): Report of two cases with fine-needle aspiration cytology. *Diagn Cytopathol.* 2001 Jan 1;24(1):42-5.
2. Kumar B, Karki S, Paudyal P. Diagnosis of sinus histiocytosis with massive lymphadenopathy (Rosai-Dorfman disease) by fine needle aspiration cytology. *Diagn Cytopathol.* 2008 Oct 1;36(10):691-5.
3. Dahlgren M, Smetherman DH, Wang J, Corsetti RL. Rosai-Dorfman disease of the breast and parotid gland. *J La State Med Soc.* 2007 Dec;160(1):35-8.
4. Kruse AL, Gengler C, Grätz KW, Obwegeser JA. Extranodal manifestation of Rosai-Dorfman disease without involvement of lymph nodes. *J Craniofac Surg.* 2010 Nov 1;21(6):1733-6.
5. Wenig BM, Abbondanzo SL, Childers EL, Kapadia SB, Heffner DR. Extranodal sinus histiocytosis with massive lymphadenopathy (Rosai-Dorfman disease) of the head and neck. *Hum Pathol.* 1993 May 1;24(5):483-92.

How to cite this article: Yadav S, Singhai A, Babu S. Rosai-Dorfman Disease of Extranodal Site. *Ann. Int. Med. Den. Res.* 2017; 3(5):PT07-PT08.

Source of Support: Nil, **Conflict of Interest:** None declared