

# Histopathological Pattern of Lungs on Post-Mortem Specimen – A Study of 100 Cases.

Bhavleen Kaur<sup>1</sup>, Rajiv Kamal Gupta<sup>2</sup>, Harpal Singh<sup>2</sup>, Akashdeep Aggarwal<sup>3</sup>, Ramesh Kumar Kundal<sup>4</sup>, Garima Anand<sup>5</sup>, Puneet Garg<sup>5</sup>

<sup>1</sup>Junior Resident, Department of Pathology, Government Medical College, Patiala.

<sup>2</sup>Associate Professor, Department of Pathology, Government Medical College, Patiala.

<sup>3</sup>Associate Professor, Department of Forensic Medicine, Government Medical College and Rajindra Hospital, Patiala.

<sup>4</sup>Professor and Head of department, Department of Pathology, Government Medical College, Patiala.

<sup>5</sup>Junior Resident, Department of Pathology, Government Medical College, Patiala.

Received: April 2017

Accepted: April 2017

**Copyright:** © the author(s), publisher. It is an open-access article distributed under the terms of the Creative Commons Attribution Non-Commercial License, which permits unrestricted non-commercial use, distribution, and reproduction in any medium, provided the original work is properly cited.

## ABSTRACT

**Background:** Lungs are a major organ involved in infectious, inflammatory, occupational and neoplastic diseases. Lungs are also involved secondarily in almost all terminal events. Autopsy is an important tool to identify cause and manner of death and hence to establish preventive methods. Aims: To study the histopathological pattern of lungs in 100 post mortem cases. **Methods:** This was an observational study on 100 post-mortem specimens of lungs received in the department of Pathology, GMC, Patiala for a period of 1 year from August 2014 onwards. A thorough gross examination was done on the received lung specimens and sections were taken from the representative areas. These sections were processed for paraffin blocks; slides were prepared and stained with routine Hematoxylin and Eosin stains. The slides were studied under the microscope and the results were noted. **Results:** Out of the 100 cases, 63 showed terminal nonspecific changes; 19 cases showed the evidence of chronic venous congestion. 10 cases were of pneumonia, 6 of granulomatous pathology, and 1 case of metastatic deposits of adenocarcinoma. **Conclusion:** Infections are the most commonly noticed primary lung pathology mainly comprising of pneumonia followed by tuberculosis. Hence, efforts should be made for the prevention of these infectious diseases.

**Keywords:** Pneumonia, granuloma, tuberculosis, chronic venous congestion, adenocarcinoma.

## INTRODUCTION

The autopsy has served medicine in numerous ways and continues to play evolving roles in a time when technologies have dramatically improved and when new diseases (naturally occurring or iatrogenic) continue to arise on medical horizon. Determining the cause of death is an obvious objective of medico-legal autopsy.<sup>[1]</sup>

Two major types of autopsy are commonly described namely: hospital or clinical and medico- legal or coroner's autopsy.

Medico- legal investigation of death focuses on the establishment of the cause of death, the time and the circumstances of death.<sup>[2]</sup>

### Name & Address of Corresponding Author

Dr. Harpal Singh,  
Associate Professor,  
Department of Pathology,  
Government Medical College,  
Patiala.

Findings on autopsy can enable the pathologist to alert the infection control unit of a hospital on possible nosocomial infection especially contagious infection. The pathologist can also identify a

hereditary condition that would require genetic counselling.

The lungs are a pair of spongy, air-filled organs located on either side of the chest (thorax). The trachea conducts inhaled air into the lungs through its tubular branches, called bronchi. The bronchi then divide into smaller and smaller branches (bronchioles), and finally air reaches to the alveoli.

Average adult right lung weighs- 450gm (375-450gm); left lung weighs- 400gm (325-450gm).

The two main components of the lung parenchyma are the bronchi and bronchioles (airways) and the alveoli. The alveoli are lined by type I and type II (granular) pneumocytes; the latter produce surfactant and are the main proliferating component after alveolar injury. The alveolar walls contain capillaries whose basement membrane fuses with that of the alveolar epithelium to constitute a single alveolar capillary membrane.<sup>[3]</sup>

In lung autopsy – the lungs are examined for disease, injury and other findings suggesting cause of death or related changes.

The lungs are affected by various infectious, inflammatory, occupational and neoplastic conditions. Lungs are involved secondarily in almost all the terminal events.<sup>[4]</sup>

In asphyxia deaths, the surface of the lungs, particularly the interface of the lobes show the presence of Tardieu’s spots, and both the lungs will be congested with oedema fluid. In cases of death due to drowning, there will be absence of Tardieu’s spots on the surface; however, the lungs will be oedematous. Punctured or lacerated wounds can cause collapse of the particular lobe. In case of blunt force injury, wounds of the lung correspond with the fractured end of a rib. In case of any pathology, the tissue may be processed for histological test.

Tuberculosis today remains one of the world’s most lethal infectious diseases. Despite the availability of effective treatment for most cases, tuberculosis is still a cause of death in our environment. Some cases of active tuberculosis are not identified until after the patient has died and an autopsy has been performed. Pathologic examination of autopsy lungs gives valuable information such as various stages of fibrosis, including early patchy fibrosis and honeycomb lesions, and their distribution and progression in the lungs.<sup>[5]</sup>

Hence, it is important to identify the leading causes of death in a particular area to establish the preventive control measures.

### MATERIALS AND METHODS

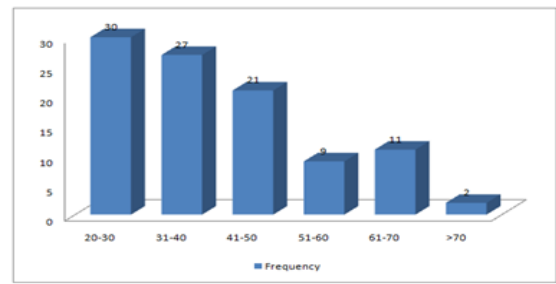
This is a prospective observational study conducted on 100 post-mortem lung specimens received during 1 year from August 2014 onwards in the department of Pathology, Government Medical College, Patiala. The department receives post-mortem specimens from District hospitals, civil hospitals, and Primary health centres of district Patiala, Sangrur, Fatehgarh Sahib, Ropar, Mohali, Ludhiana for histopathological examination. The autopsies are usually from medico-legal cases, custodial deaths, road side accidents, poisoning and drowning.

- Inclusion criteria –the subjects were selected from medico-legal autopsies irrespective of cause of death
- Exclusion criteria- autolysed specimens were excluded from the study

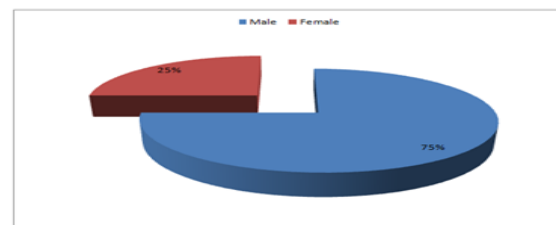
A thorough gross examination of lung specimens or a part of lung, including measurements, weight, consistency, cut surface, details of any lesion if present were recorded. The samples were taken from representative areas of the specimen and were processed for histopathology. Haematoxylin and eosin (H&E) staining was done.

### RESULTS

Age distribution – mean age was 41.3 years with standard deviation of 14.57 years. Gender distribution – male: female- 3:1.



**Graph 1: Age Group Distribution.**



**Graph 2: Sex Distribution.**

**Table 1. Distribution of Various Morphological Changes in the Subjects.**

MORPHOLOGICAL CHANGES NOTED	PRESENT (%)	ABSENT (%)
CONGESTED BLOOD VESSELS	99.0	1.0
ANTHRACOSIS	60.0	40.0
PULMONARY OEDEMA	56.0	44.0
EMPHYSEMATOUS CHANGES	56.0	44.0
HEART FAILURE CELLS	19.0	81.0
INFLAMMATORY INFILTRATE	16.0	84.0
FIBROSIS	10.0	90.0

In this study, the most common morphological change seen was congestion in (99% cases); followed by anthracosis in 60% cases.

Pulmonary oedema and emphysematous change was observed in the same frequency of 56%.

Heart failure cells were seen in 19%.

Inflammatory infiltrates were observed in 16% of the cases. Fibrosis was noted in 10% of the cases.

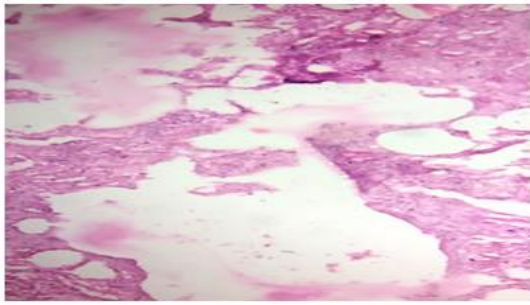
Based on the above morphological findings the various pathologies noted were-

**Table 2. Lung pathology**

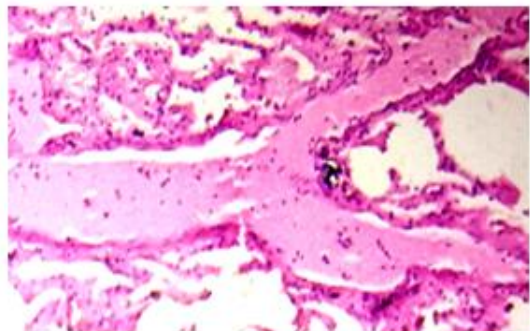
LUNG PATHOLOGY	FREQUENCY	PERCENT (%)
TERMINAL CHANGES	63	63.0
CHRONIC VENOUS CONGESTION	19	19.0
PNEUMONIA	10	10.0
CHRONIC GRANULOMATOUS PATHOLOGY	6	6.0
METASTATIC DEPOSITS	1	1.0
PLEURAL HAEMORRHAGE	1	1.0
TOTAL	100	100.0

**Terminal changes:** included nonspecific findings of congested blood vessels, pulmonary oedema, areas of haemorrhage and emphysematous changes.

These were noted in majority of the males with no age group specifications.



**Figure 1: Microphotograph showing Emphysematous changes (10X H&E).**

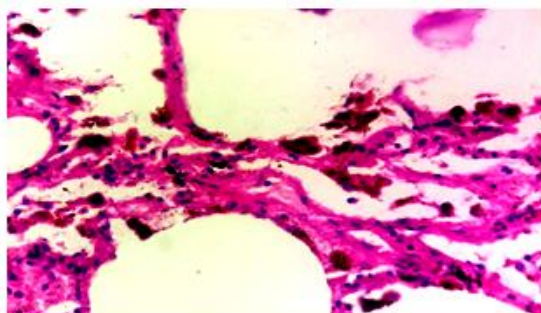


**Figure 2: Microphotograph showing pulmonary oedema (10X H&E).**

### **Chronic venous congestion**

Chronic venous congestion – was noted by the presence of thickened alveolar walls, presence of numerous haemosiderin-laden macrophages (heart-failure cells) within the alveolar lumens, and thickened vessel walls. These were more common in males. Majority of the cases belonged to the age group of >50 years.

Specimens of heart were also received in 14 of these cases which showed the features of left ventricular hypertrophy.

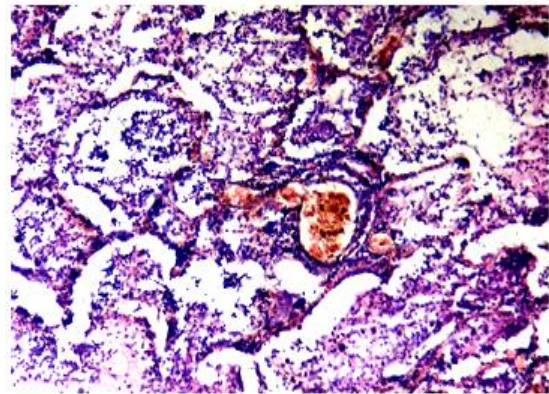


**Figure 3: Microphotograph showing Heart failure cells (10X H&E).**

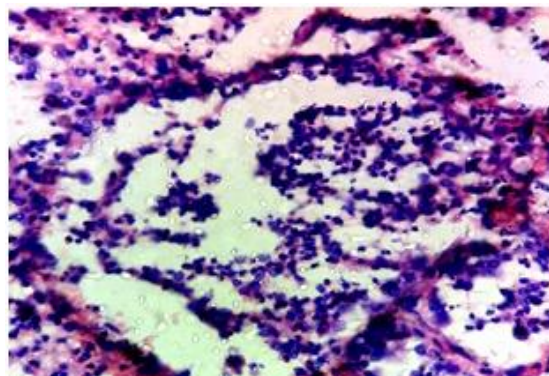
### **Pneumonia**

Pneumonia was noted by the presence of vascular engorgement, intra-alveolar fluid with neutrophils, and often the presence of numerous bacteria and red cells, and fibrin filling the alveolar spaces. All the cases were of lobar pneumonia. This pathology was

more common in males (70%). Majority of the cases were noted in 20-40 years of age.



**Figure 4: Microphotograph of Lobar Pneumonia (10X H&E).**

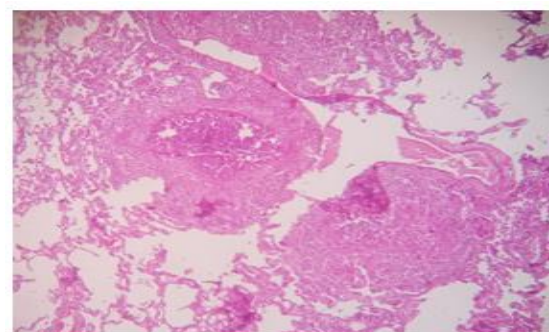


**Figure 5: Microphotograph of Lobar Pneumonia (40X H&E).**

### **Chronic granulomatous pathology**

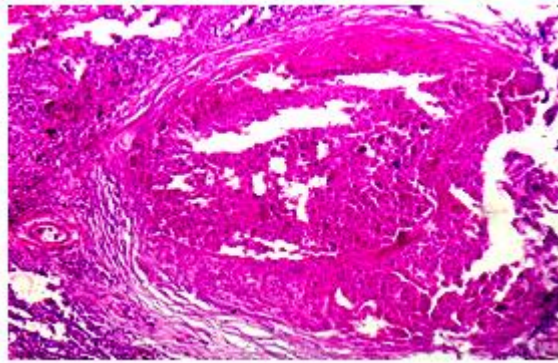
Chronic granulomatous pathology was noted by the presence of well-formed granulomas comprising of epithelioid cells and giant cells surrounded by collar of lymphocytes and fibrosis.

Out of 6 cases, 5 cases showed the presence of central caseation necrosis with Langhans type of giant cells and the possibility of tuberculosis was kept. One case showed presence of non caseating granulomas. No gender predilection was noted. Majority of the cases were of the age group of 19-40 years.



**Figure 6: Microphotograph of Caseating granuloma (10X H&E).**





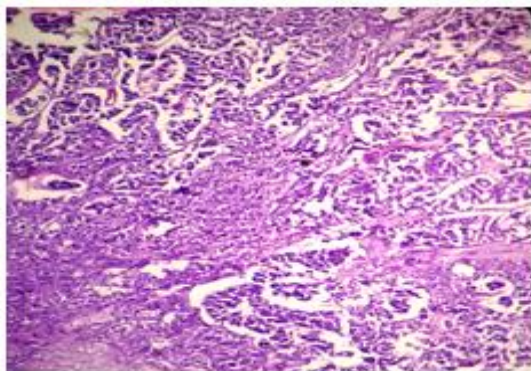
**Figure 7: Microphotograph of Caseating granuloma (40X H&E).**

**Metastatic deposits**

A single case was reported in a 65 yr old female. Grossly – lung surface showed creamish white firm to hard nodules approximately 0.5-1cm in diameter. On microscopy were seen well-formed acini, cords and sheets of malignant epithelial cells exhibiting pleomorphism, increased nucleocytoplasmic ratio, vesicular to hyperchromatic nuclei with irregular nuclear contours, prominent nucleoli, and variable amount of eosinophilic cytoplasm. These were surrounded by chronic inflammatory infiltrate and areas of fibrosis.



**Figure 8: Gross picture of lung specimen showing metastatic deposits.**



**Figure 9: Microphotograph of Metastatic deposits of Adenocarcinoma (10X H&E).**

**Pleural haemorrhage**

A single case of 30 yr old male was noted. On gross examination - multiple areas of haemorrhage were seen on the pleural surface.

Microscopic examination confirmed the gross findings along with the presence of other terminal changes in the lung.

**DISCUSSION**

The present study was compared to the previously done similar studies.

**Terminal changes**

Terminal changes were noted in 63% of the cases. These included the presence of pulmonary oedema, emphysematous changes, congested blood vessels and presence of haemorrhages. This was similar to the study by Chauhan et al in which these terminal changes were noted in 182 out of 335 cases (54.32%).<sup>[6]</sup>

A study was done by Ohya in 1994 on 130 medicolegal cases to detect early histopathological changes of lungs. In this study,<sup>[7]</sup> pulmonary oedema and haemorrhage were noted, but the incidence of such changes did not reveal any significant difference among the causes of death. In the present study also pulmonary oedema was noted in 56% of cases without any other significant pathology.

Emphysematous changes were noted in 56% of the cases in the present study which was consistent with the study done by Sevlam et al in 2011 which showed emphysematous changes in 46.2% cases of the 108 studies autopsy cases. However,<sup>[8]</sup> in the study done by Sevlambigai et al in 2016,<sup>[4]</sup> emphysematous changes were noted in 16% of the 100 autopsy cases studied.

Urer et al studied 66 autopsy cases having diffuse alveolar damage showing alveolar histiocytic desquamation,<sup>[9]</sup> alveolar fibrosis, chronic inflammation and alveolar fibrin. No such pathological changes were noticed in the present study.

Anthraxosis was noted in 60% of the cases in the present study. No similar findings were noted in the previously conducted studies.

Rosen et al conducted a study which showed reactive epithelial hyperplasia in majority of the cases where inflammation was more prominent.<sup>[10]</sup> However, these findings were not observed in the present study.

**Pneumonia**

In the present study, the cases of pneumonia noted were 10 in number which accounted for 10% of the total cases. This was in concordance with the study conducted by Chauhan et al (2015) where pneumonia was seen in 49 out of 335 cases (14.62 %).<sup>[6]</sup> However, Tariq et al observed a slightly lower percent of pneumonia cases (4%).<sup>[11]</sup> Udayshankar et al<sup>[5]</sup> (2013) reported a relatively higher percentage of pneumonia cases (31.81%).

Of these 10 cases of pneumonia, 3 were females, and 7 were males (M: F-2.3:1). This was in concordance with study done by Udayshankar et al

in which pneumonia cases were seen in 2 females and 5 males (M:F-2.5:1). However, the study by Chauhan et al observed that out of the pneumonia cases 18 were females and 31 were males (M:F-1.72:1). Tariq et al reported equal distribution of pneumonia in males and females (M: F-1:1).

In this study, majority of the pneumonia cases belonged to the age group of 20-30 years. However, in the study of Chauhan et al the majority of the pneumonia cases were reported in the age group of 50-59 years.

**Table 3: Comparative study of pneumonia cases with sex distribution in different studies.**

STUDY	Pneumonia cases	Males	Females
Tariq et al (2013) <sup>11</sup>	32 out of 810 cases (4%)	16 (.50%)	16 (.50%)
Udayshankar et al (2013) <sup>5</sup>	7 out of 22 cases (31.81%)	5 (71.42%)	2 (28.58%)
Chauhan et al (2015) <sup>8</sup>	49 out of 335 cases (14.62%)	31 (63.26%)	18 (36.74%)
Present study (2016)	10 out of 100 cases (10%)	7 (70%)	3 (30%)

A study was done by Tashiro et al in 1989 on 185 autopsy cases which showed bacterial pneumonia in 28.64% cases.<sup>[12]</sup> Terrabuio et al in 2007 conducted a study on 558 patients which showed pneumonia in 13% of cases.<sup>[13]</sup> Soeiro et al studied 3030 autopsy cases in 2008 which showed pneumonia in 21.8% cases.<sup>[14]</sup> These findings were consistent with the present study.

**Granulomatous diseases**

**Table 4. Sex distribution of granulomatous diseases in various studies.**

STUDY	RESULTS	Males	Females
Tariq et al (2013) <sup>11</sup>	154 out of 810 cases (19%)	122 (79.23%)	32 (20.77%)
Udayshankar et al (2013) <sup>5</sup>	5 out of 22 cases (22.72%)	5 (100%)	0 (0%)
Chauhan et al (2015) <sup>8</sup>	21 out of 335 cases (6.26%)	14 (66.67%)	7 (33.33%)
Present study (2016)	6 out of 100 cases (6%)	3 (50%)	3 (50%)

In the present study, 6 cases of granulomatous diseases were noted which accounted for 06 % of the total cases. This was in concordance with the study done by Chauhan et al (2015) in which 21 cases of granulomatous pathology was reported (6.26%). However, the percentage of granulomatous

pathology noted was higher in the study by Tariq (2013) et al (19%) and Udayshankar et al (2013) (22.72%).

In the present study, equal distribution was noted in the males and females (M:F-1:1). This was not in concordance with the studies done by Chauhan et al (M: F-2:1), Tariq et al (M: F-3.8:1) and Udayshankar et al (only males) which showed a male preponderance of granulomatous pathology. Majority of the granulomatous cases in this study were seen in the age group of 19-30 years (4 out of 6 cases). However, in the study of Chauhan et al, the majority of the cases were seen in the age group of 30-39 years.

Gupta et al studied 40 cases diagnosed as pulmonary tuberculosis with a mean age was 41 years with a male preponderance (92.5%) which was not consistent with the present study.<sup>[16]</sup>

A study was done by Meel et al on 200 cases which showed granulomas with carbon and silica particles in 1% males and 7% females.<sup>[17]</sup> These non-tuberculous (dust reticulation) granulomas were not observed in the present study.

**Chronic venous congestion**

Chronic venous congestion was seen in 19 cases (19%) in the present study. No data for secondary lung involvement was noticed in the above studies.

**Tumors**

In the study by Chauhan et al, 2 cases of malignant Tumors in the lung were reported.

In a study done by Morita in 2002 on lung cancers showed an increase in incidence from 6% to 12% in males and from 3% to 6% in females.<sup>[18]</sup> Adenocarcinoma was the most frequent and squamous cell carcinoma was the next most frequent in both the sexes.

In this study, 1 case of metastatic deposits was seen. No benign or malignant primary tumour cases were seen in the present study. Hence, the results were not consistent with the above studies.

**CONCLUSION**

The current study shows the incidence of lung lesions in the regions of Punjab. The most common primary finding was that of pneumonia. The patterns of finding were similar to many other studies. We should plan to prevent the causes and reduce the prevalence of pneumonia and tuberculosis.

**Future Scope**

The technologies have advanced in the recent times yet study of autopsy still serves as a supportive and educative tool in identifying and establishing the underlying cause of death. Hence, its importance must be understood, since there has to be newer approaches for old diseases and scope for detection of newer diseases.

## REFERENCES

1. Bal MS, Sethi PS, Suri AK, Bodal VK, Kaur G. Histopathological pattern in lung autopsies. *JPAFMAT*.2008;8(2):29-31.
2. Kandy NC, Pai MR, Reba PT. Role of Histopathology on Autopsy Study: An Audit. *SAS J Med*. 2015;1(1):7-15.
3. Rosai J. Respiratory tract- Lung and pleura. In: Rosai and Ackerman's Surgical Pathology. 10<sup>th</sup> ed: India.Elsevier.2012: 349-400.
4. Sevlambigai G, Amudhavalli S, Chakravarthi C.D, Ravi S. Histopathological study of lung in autopsy cases: a prospective study. *Int J Res Med Sci*. 2016; 4(11):4816-4819.
5. Udayashankar SK, Shashikala P, Kavita GU et al. Histomorphological Pattern of Lung in Medicolegal Autopsies. *Int J Sci Res*.2013: 2319-7064.
6. Chauhan G, Aggarwal M, Thakkar N, Parghi B. Spectrum of histopathological lesions in lung autopsy. *J Res Med Den Sci*. 2015;3(2):109-12.
7. Ohya I. Some findings of lung in autopsy cases, *Nippon HoigakuZasshi* 1994; 48(6):379-94.
8. Sevlam VR, Selvi T, Subramaniam PM. Prevalence of common disease in lungs and liver; a histopathological study. *J Pharma Biomedical Sci*.2011;12(09):1-5.
9. Urer HN, Ersoy G,Yilmazbayhan ED. Diffuse Alveolar Damage of the lungs in Forensic Autopsies: Assessment of Histopathological stages and causes of death. *Sci World J*. 2012; 2012.
10. Rosen D G, LopeA E, Anzalone M L et al. Postmortem findings in eight cases of influenza A/H1N1. *Modern Pathol*.2010; 23:1449–1457.
11. Tariq TM, Rehman F, Anwar S et al. Patterns of Pulmonary morphological lesions seen at autopsy. *Biomedica*. 2013; 29:64-68.
12. Tashiro T, Yamasaki T, Goto Y et al. A histopathological study on pseudomonas pneumonia diagnosed by immunostaining with monoclonal antibody. *Kansenshogaku Zasshi* 1989; 63(1): 1-9.
13. Terrabuio AA, Parra E R, Farhat C et al. Autopsy-proven causes of death in lungs of patients immunocompromised by secondary interstitial pneumonia.*Clinics*.2007;62(1).
14. Soeiro A M, Parra E R, Canzian M et al. Pulmonary histopathological alterations in patients with acute respiratory failure: an autopsy study. *Jornal Brasileiro de Pneumologia*.2008; 34(2).
15. Soeiro A M, Hovnanian A L D, Parra E R et al. Post-mortem histological pulmonary analysis in patients with HIV/AIDS. *Clinics*.2008;63(4).
16. Gupta M, Lobo F D, Adiga D S A et al. A Histomorphological Pattern Analysis of Pulmonary Tuberculosis in Lung Autopsy and Surgically Resected Specimens. *Pathology Research International Journal*. 2016; 2016:8132741.
17. Meel B L. Histopathological screening for silicosis in autopsy cases of the Umtata area of the Eastern Cape Province. *Int J Occup Med Environ Health*, 2003; 16(3):271- 274.
18. Morita T. A statistical study of lung cancer in annual of pathological autopsy cases in Japan, from 1958 to 1997, with reference to time trends of lung cancer in the world. *Jpn J Cancer Res*.2002; 93(1):15-23.

**How to cite this article:** Kaur B, Gupta RK, Singh H, Aggarwal A, Kundal RK, Anand G, Garg P. Histopathological Pattern of Lungs on Post-Mortem Specimen – A Study of 100 Cases. *Ann. Int. Med. Den. Res*. 2017; 3(4):PT01-PT06.

**Source of Support:** Nil, **Conflict of Interest:** None declared