

# Uterine Lipoleiomyoma Associated With Ovarian Serous Cystadenoma in a Postmenopausal Woman: A Rare Occasion.

Biswajit Dey<sup>1</sup>, Sairem Mangolnganbi Chanu<sup>2</sup>, Vandana Raphael<sup>3</sup>, Subrat Panda<sup>4</sup>, Pranoy Paul<sup>5</sup>

<sup>1</sup>Assistant Professor, Department of Pathology, North Eastern Indira Gandhi Regional Institute of Health and Medical Sciences, Shillong.

<sup>2</sup>Assistant Professor, Department of Obstetrics and Gynecology, North Eastern Indira Gandhi Regional Institute of Health and Medical Sciences, Shillong.

<sup>3</sup>Professor, Department of Pathology, North Eastern Indira Gandhi Regional Institute of Health and Medical Sciences, Shillong.

<sup>4</sup>Associate professor, Department of Obstetrics and Gynecology, North Eastern Indira Gandhi Regional Institute of Health and Medical Sciences, Shillong.

<sup>5</sup>Junior Resident, Department of Pathology, North Eastern Indira Gandhi Regional Institute of Health and Medical Sciences, Shillong.

Received: May 2017

Accepted: June 2017

**Copyright:** © the author(s), publisher. It is an open-access article distributed under the terms of the Creative Commons Attribution Non-Commercial License, which permits unrestricted non-commercial use, distribution, and reproduction in any medium, provided the original work is properly cited.

## ABSTRACT

Lipoleiomyomas are rare benign variant of uterine leiomyoma, composed of admixture of mature smooth muscle cells and adipocytes with a reported incidence of 2.9% of all leiomyomas. They are usually found in the peri-menopausal and postmenopausal women. Lipoleiomyomas can be associated with estrogenic states like adenomyosis, endometriosis, endometrial hyperplasia, polyps and gynaecologic malignancies. We report a case of uterine lipoleiomyoma associated with left ovarian serous cystadenoma in a post-menopausal woman, who presented with complaints of abdominal pain and abdominal distension.

**Keywords:** Lipoleiomyoma, cystadenoma, Uterus.

## INTRODUCTION

Primary lipomatous tumours of the uterus are very uncommon with an incidence of 0.03% to 0.2% and almost invariably benign.<sup>[1]</sup> Pounder subdivided these tumours into “lipoma” and “mixed lipoma/leiomyoma (lipoleiomyoma).<sup>[2]</sup> Lipoleiomyosarcoma arising in uterine lipoleiomyoma has been reported.<sup>[3]</sup> Rarely these tumours may be seen arising in cervix and from the parametrium in broad ligament.<sup>[1]</sup> They can be associated with adenomyosis, endometriosis, endometrial hyperplasia, polyps and gynaecologic malignancies.<sup>[4]</sup> We report a case of uterine lipoleiomyoma associated with left ovarian serous cystadenoma in a post-menopausal woman.

### Name & Address of Corresponding Author

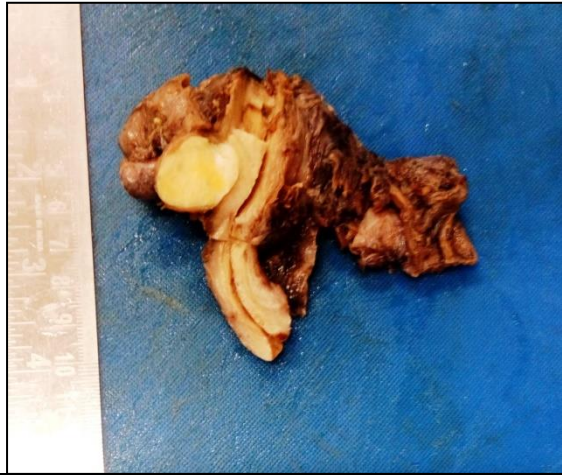Dr. Biswajit Dey,  
Assistant Professor, Department of Pathology,  
North Eastern Indira Gandhi Regional Institute of Health and  
Medical Sciences,  
Shillong.

## CASE REPORT

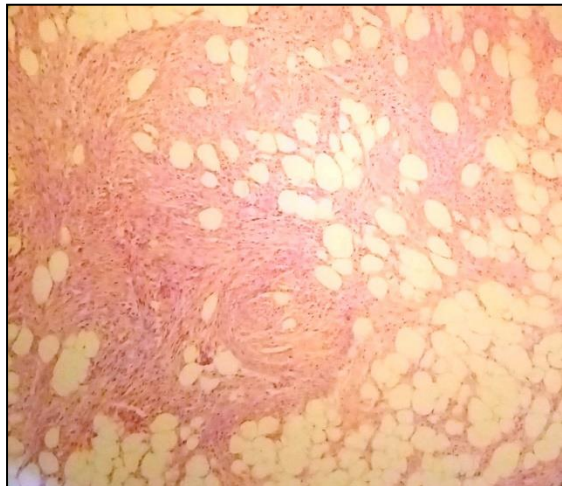
A 75-year-old post-menopausal female presented with complaints of abdominal pain and abdominal

distension increasing in size for last 6 months. She was gravida 4 and para 4. She had no complaints related with menstrual bleeding. On physical examination she was hemodynamically stable and her abdominal examination revealed a palpable mass filling whole abdominal cavity which could not be lateralized. On per vaginal examination, uterus was found to be anteverted. Laboratory investigations were within normal limits. Ultrasonography revealed a large cystic mass with a solid area measuring 20x 20x 10 cm arising from the left ovary. Radiological impression was that of a left malignant ovarian neoplasm. Surgery was planned and intra-operatively a large cystic mass arising from the left ovary was noted. The ovarian mass was excised and sent for frozen section to rule out malignancy. The frozen section revealed it was benign ovarian cyst. Total abdominal hysterectomy with bilateral salpingo-oophorectomy was done. Grossly, the left ovarian mass measured 20x 20x 0 cm. It was cystic filled with serous fluid with a solid area measuring 5x3x2 cm attached to the inner wall of the cyst wall. The uterus had a subserosal fibroid measuring 3 cm in diameter. The cut section of the fibroid was yellowish in colour [Figure 1]. The rest of the uterus, cervix and the right adnexa were grossly normal. Microscopic examination of the left ovarian cyst showed features of serous cystadenoma. The subserosal fibroid was reported as lipoleiomyoma

[Figure 2]. Intraoperative and postoperative period was uneventful and she was eventually discharged and advised for regular follow-up.



**Figure 1:** Cut section of the subserosal fibroid showing yellowish colour.



**Figure 2:** Microscopy of the fibroid showing admixture of mature smooth muscle and adipocytes. (H & E, 400x).

## DISCUSSION & CONCLUSION

Lipoleiomyoma is a rare benign variant of uterine leiomyoma, composed of admixture of mature smooth muscle cells and adipocytes.<sup>[4]</sup> Akbulut et al reported the incidence of lipoleiomyoma to be 2.9% of all leiomyomas.<sup>[4]</sup> It is usually found in the perimenopausal and postmenopausal women.<sup>[1]</sup> Lipoleiomyoma is often single with variations in size.<sup>[4]</sup>

Most of the patients are asymptomatic but some experience symptoms such as pelvic discomfort, heaviness and vaginal bleeding.<sup>[1,4]</sup> Radio imaging techniques like magnetic resonance imaging and computed tomography play an important role in determining the intrauterine location and fatty nature

of lipoleiomyoma but most of these are incidental findings postoperatively on histopathology.<sup>[1,5]</sup> The lipomatous mass in the pelvis has varied differential diagnosis including benign cystic teratoma, malignant degeneration of cystic teratoma, non-teratomatous lipomatous ovarian tumour, pelvic lipomas and liposarcomas, and pelvic fibromatosis.<sup>[6]</sup> Therefore a thorough radiological and histopathological examination is therefore recommended in such cases.

The pathogenesis and clinical significance of these tumours are not yet fully understood. They probably represent tumor metaplasia within a leiomyoma.<sup>[4]</sup> The association between gynecologic malignancies originating from the uterus, cervix and ovaries, and coexistent lipoleiomyoma has been reported.<sup>[4]</sup> Akbulut et al found 12 cases (17.1%) of malignant gynecologic neoplasms including eight endometrial, 3 ovarian and 1 breast.<sup>[4]</sup> They also found 7 cases (10%) of benign ovarian neoplasms.<sup>[4]</sup> In the present case, the uterine lipoleiomyoma was an incidental finding associated with benign ovarian neoplasm.

Lipoleiomyoma of the uterus is an uncommon benign tumour with favourable outcome. It can be associated with estrogenic conditions like adenomyosis, endometriosis, endometrial hyperplasia, polyps and gynaecologic malignancies. However, the clinical significance of lipoleiomyoma is still not fully understood.

## REFERENCES

1. Kumar S, Garg S, Rana P, Hasija S, Kataria SP, Sen R. Lipoleiomyoma of uterus: Uncommon incidental finding. *Gynecol Obstet* 2013;3:2.
2. Pounder DJ. Fatty tumours of the uterus. *J Clin Pathol* 1982;35:1380-1383.
3. Lin M, Hanai J. Atypical lipoleiomyoma of the uterus. *Acta Pathol Jpn.* 1991;41:164-169.
4. Akbulut M, Gündogan M, Yörükoglu A. Clinical and pathological features of lipoleiomyoma of the uterine corpus: A review of 76 cases. *Balkan Med J* 2014;31:224-229.
5. Kitajima K, Kaji Y, Imanaka K, Sugihara R, Sugimura K. MRI findings of uterine lipoleiomyoma correlated with pathological findings. *AJR Am J Roentgenol* 2007; 189: 100-104.
6. Manjunatha HK, Ramaswamy AS, Kumar BS, Kumar SP, Krishna L. Lipoleiomyoma of uterus in a postmenopausal woman. *J Midlife Health* 2010;1:86-88.

**How to cite this article:** Dey B, Chanu SM, Raphael V, Panda S, Paul P. Uterine Lipoleiomyoma Associated With Ovarian Serous Cystadenoma in a Postmenopausal Woman: A Rare Occasion. *Ann. Int. Med. Den. Res.* 2017; 3(4):PT72-PT73.

**Source of Support:** Nil, **Conflict of Interest:** None declared