

Nodular Hidradenoma on the Chest Wall - A Rare Case Report.

Anika Mittal¹, Ramesh Kumar Kundal², Harpal Singh Seemar³, Puneet Garg⁴, Namarta Goyal⁴, Akansha Agarwal⁴

¹Junior Residents, Dept. of Pathology, Govt. Medical College Patiala.

²Professor and Head, Dept. of Pathology, Govt. Medical College Patiala.

³Associate Prof. Dept. of Pathology, Govt. Medical College Patiala.

⁴Junior Residents, Dept. of Pathology, Govt. Medical College Patiala.

Received: April 2017

Accepted: May 2017

Copyright: © the author(s), publisher. It is an open-access article distributed under the terms of the Creative Commons Attribution Non-Commercial License, which permits unrestricted non-commercial use, distribution, and reproduction in any medium, provided the original work is properly cited.

ABSTRACT

Hidradenoma is a cutaneous, often benign tumour of the sweat glands. Also known by various other names such as nodular hidradenoma, eccrine acrospiroma, and solid cystic hidradenoma. Annual incidence rate of sweat gland tumors is about 5.1 cases per 1 million people. The case is being reported for its rare incidence, rare site and unusual clinicomorphological appearance.

Keywords: Hidradenoma, Eccrine, Acrospiroma.

INTRODUCTION

Nodular hidradenoma is a cutaneous neoplasm that may appear at various sites all over the body. It is commonly been referred as clear cell hidradenoma or sweat gland adenoma of eccrine origin.^[1] Nodular hidradenomas arises from eccrine sweat glands as intradermal nodules. They are known to be an intermediate entity between eccrine poroma and eccrine spiradenoma.^[2] These are most commonly found on the scalp, face, thorax, abdomen, and gluteal region. This tumor is found mainly in adults, peak incidence being the fifth to sixth decade and the tumor is excised more commonly in women than in men. Clinically, it presents as a slow-growing, red, blue or brown-colored solitary, 5–30 mm in size, freely mobile and firm nodule, with an occasional cystic appearance.^[3]

discharge. A clinical diagnosis of sebaceous cyst was made and the swelling was excised under local anesthesia and was sent to the department of pathology.

Grossly the soft tissue piece was skin covered brownish white measuring 1x1cms. Microscopy showed well demarcated lobules surrounded by a capsule present in the dermis. Within these lobulated masses, tubules and papillae of varying sizes were present. The tubules were lined by cuboidal ductal and columnar secretory cells with distinct cell membranes. Few small cystic spaces containing secretions were also present and the tumor showed no extension into the epidermis. Overlying skin showed acanthosis. Histopathological diagnosis of benign adnexal tumor i.e nodular hidradenoma was made. Follow up period was unremarkable.

Name & Address of Corresponding Author

Dr. Harpal Singh Seemar
Associate Professor,
Department of Pathology,
#835/13 Ghuman Nagar A,
Sirhind Road Patiala 147001, Punjab (India)

CASE REPORT

A 50 year old female patient presented to the surgery OPD with the complaint of swelling on the right side of the chest wall near the right breast since 3 years. It started increasing in size since few months. However, it was not associated with any pain or

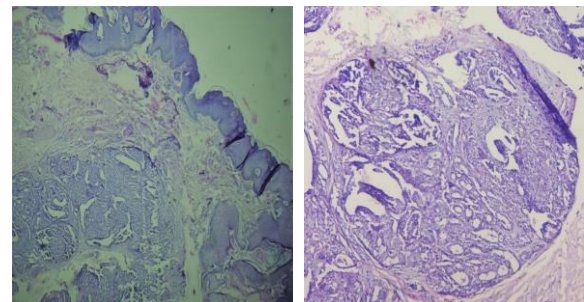


Figure 1 & 2: Photomicrographs (H& E 100X and 400X) showing well demarcated lobule within the dermis containing tubules and cystic spaces with secretions (arrow). Overlying epidermis is normal.

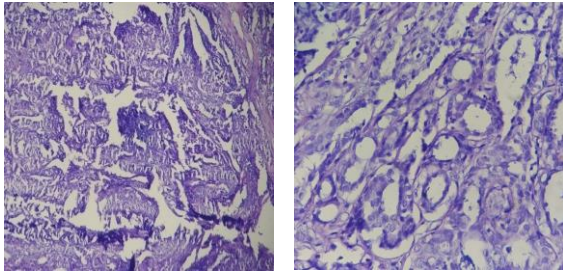


Figure 3 & 4: Photomicrographs (H&E 100X & 400X) showing the tubules lined by cuboidal and columnar secretory cells.

DISCUSSION

Hidradenomas are benign cutaneous tumors of sweat gland origin, with the clear cell type constituting the most frequent histologic variety.^[4] There is as yet no site predilection for hidradenoma although occurrence in vulva has been reported.^[5] Involvement of scalp, face, anterior trunk and proximal limbs is also commonly seen.^[6] The average size of hidradenoma is about 1 to 3 cm in diameter, although cases have been reported upto 6 cm in size.^[7] Enzyme histochemical staining has established the presence of high concentrations of eccrine enzymes, particularly phosphorylase and respiratory enzymes including succinic dehydrogenase and diphosphopyridine nucleotide diaphorase.^[8] Variants of nodular hidradenoma may show several types of cells. As the percentage of different cell types varies markedly in different tumors, the resemblance of nodular hidradenoma to metastatic renal cell carcinoma, squamous cell carcinoma should be kept as a closest differential diagnosis. The high rate of local recurrence (10%) and potential for malignant transformation make surgical removal with wide margins as the widely accepted modality of treatment.^[9,10]

CONCLUSION

The appearance of two types of cells, eosinophilic and clear cells in a papillary pattern along with ducts-like tubular structures within the lobules intradermally along with cystic spaces are the key features of nodular hidradenoma. Local resection remains the mainstay of its treatment.

REFERENCES

1. Alkatan HM. Nodular hidradenoma of the lower eyelid. *Can J Ophthalmol* 2007;42:149-50.
2. Agarwala NS, Rane TM, Bhaduri AS. Clear cell hidradenoma of the eyelid: A case report. *Indian J Pathol Microbiol* 1999;42:361-3.

3. Yildiz B, Ozdemir F, Cobanoglu U, Kavgaci H, Fidan E, Aydin F. Clear cell hidradenoma of the gluteal region: A case report. *Acta Dermatovenerol Croat* 2009;17:144-6.
4. Liu Y. The histogenesis of clear cell papillary carcinoma of the skin. *Am J Pathol* 1949;25:93-103.
5. Acowami SO, Malik A, Hanna W. Vulvar poroid hidradenoma. *Am J Dermatopathol* 2002;24:523-525.
6. R K Winkelmann MD, Klauss Wolff MD. Solid-cystic hidradenoma of the skin clinical and histopathological study. *Arch Dermatol*. 1968; 97(6) :651 – 661
7. Hunt SJ, Santa Cruz DJ, Kerl H. Giant eccrine acrospiroma. *J Am Acad Dermatol*.1990; 23:663-668.
8. Hashimoto K, DiBella Rj, Lever WF. Clear cell hidradenoma: histological , histochemical , and electron microscopic studies. *Arch Dermatol* 1967;96(1):18-38.
9. Faulhaber D, Wörle B, Trautner B, Sander CA. Clear cell hidradenoma in a young girl. *J Am Acad Dermatol* 2000;42:693-5.
10. Stratigos AJ, Olbricht S, Kwan TH, Bowers KE. Nodular hidradenoma. A report of three cases and review of the literature. *Dermatol Surg* 1998;24:387-91.

How to cite this article: Mittal A, Kundal RK, Seemar HS, Garg P, Goyal N, Agarwal A. Nodular Hidradenoma on the Chest Wall-A Rare Case Report. *Ann. Int. Med. Den. Res.* 2017; 3(4):PT44-PT45.

Source of Support: Nil, **Conflict of Interest:** None declared