

Klippel–Trenaunay Syndrome: Clinical Features and Imaging of a Rare Syndrome.

S.K.Valinjar¹, Yogesh Mokase², Pallavi Samariya³

¹Associate Professor, Department of Paediatrics, Grant Medical College and JJ Group of Hospitals Mumbai (India).

²Assistant Professor, Department of Paediatrics, Grant Medical College and JJ Group of Hospitals Mumbai (India).

³Resident, Department of Paediatrics, Grant Medical College and JJ Group of Hospitals Mumbai (India).

Received: June 2017

Accepted: June 2017

Copyright: © the author(s), publisher. It is an open-access article distributed under the terms of the Creative Commons Attribution Non-Commercial License, which permits unrestricted non-commercial use, distribution, and reproduction in any medium, provided the original work is properly cited.

ABSTRACT

Klippel–Trenaunay syndrome, also known as Klippel–Trenaunay–Weber syndrome or Angio- osteohypertrophy is a rare condition. The incidence reported in various literature ranges between 3 to 5 cases per 1,00,000 births. It is characterized by classical triad of capillary malformations (hemangioma or port-wine stain), venous varicosities, and bony or soft-tissue hypertrophy. Though the capillary malformation usually involves single extremity extensive involvement of the body and multiple limbs have also been reported. The vascular malformations are predominantly venous. Sluggish blood flow through venous malformation causes bluish discoloration of the affected limb. Pain and fatigue are the most common complaints. Various complications seen in this syndrome include venous thrombosis leading to pulmonary embolism, gastrointestinal or rectal bleeding and haematuria. Bleeding and clotting time may be deranged secondary to thrombocytopenia and reduced fibrinogen levels. Rarely may it be associated with brainstem and cerebellar angiomas. We hereby present a case of 9 months old female having Klippel–Trenaunay syndrome. She was brought with complaints of Swelling on chest, abdomen and left lower limb since birth and fever since 2 to 3 days. Patient was evaluated clinically and radiologically. Presence of lymphovenous malformations, port wine stains and hypertrophy of left lower limb confirmed the diagnosis of Klippel–Trenaunay syndrome. Under all aseptic precautions lymph was removed from lymphatic malformation over left thoraco-abdominal region and Inj Setrol 66% 4 cc was injected into the lesion. Later compression stockings were given and parents were advised to come for followup regularly.

Keywords: Klippel–Trenaunay syndrome, capillary malformations, venous varicosities, tissue hypertrophy.

INTRODUCTION

Klippel–Trenaunay syndrome (KTS) is a rare disorder. The syndrome was first described by Klippel and Trenaunay as Klippel–Trenaunay syndrome (KTS). It included hemihypertrophy and varices as its characteristic features after which Weber found an additional feature of AV malformation and then this syndrome was called the Klippel–Trenaunay Weber syndrome with the addition of AV malformations.^[1] The characteristic features seen in these patients are combined malformation of the capillaries, veins and lymphatics, congenital venous abnormalities and limb hypertrophy. It is hypothesized that mesodermal abnormality during fetal development leads to vascular and soft tissue malformations in the affected limb. The incidence of KTS is reported to be in between 3-5/1,00,000.^[2] Males are affected more than females. Venous abnormalities may cause varicose veins while lymphatic abnormalities may cause lymphedema and swelling which is more commonly seen in lower limb and usually only one limb is involved but sometimes multiple parts of the body may be involved.^[3] Limb hypertrophy may be

not only due to venous or vascular malformations but also due to soft tissue and bone hypertrophy. Patients with this syndrome have a wide spectrum of presentation ranging from asymptomatic disease to life-threatening complications like bleeding, embolism, congestive heart failure and cellulitis. Though it is non-heritable disorder rarely autosomal-dominant form of inheritance is seen.^[4] Alternate names of this syndrome include angio-osteohypertrophy, nevus varicosus osteohypertrophicus syndrome, hemangiectasia hypertrophicans and nevus verucosus hypertrophicans. No definitive treatment is possible. Management consist of multidisciplinary approach. The aim of management is to ameliorate the patient's symptoms and correct limb-length discrepancy. Usually compression garments, sclerotherapy and in some cases surgical interventions may be required.^[5]

Name & Address of Corresponding Author

Dr. Pallavi Samariya
Resident,
Department Of Pediatrics,
Grant Medical College and JJ Group of Hospitals Mumbai
(India).

CASE REPORT

A 9 month old female child, second by order of birth was brought to our hospital in view of swelling over chest, abdomen and left lower limb since birth and fever since 2-3 days. There was no other significant postnatal, past or family history except h/o consanguinity in parents. Developmentally child was normal and there was no e/o any developmental delay. On examination diffuse, non-tender swelling was noted over thorax, abdomen, left gluteal region and left lower limb. There was history of this swelling to be present and gradually increasing since birth. On examination baby was pale and had mild tachycardia. Local Examination revealed soft, non-tender, cystic and smooth swelling with well-defined borders extending from thorax to abdomen on left side of the body. Swelling was also present on left gluteal region and left lower limb. Left foot was found to be hypertrophied with non-pitting oedema and widened spaces between 1st, 2nd and 3rd toes [Figure 1].

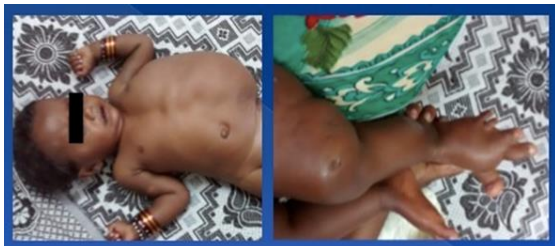

Figure 1: Swelling over thorax, abdomen and left gluteal region and left lower limb. Also Note abnormal toes with increased distance between them.

Port wine stains were noted involving parts of the swelling. Swelling was reducible and fluctuant. Transillumination test was positive on thoracic part of the swelling.



Figure 2: Positive transillumination in swelling involving chest. Also note port wine stains over the swelling.

Complete blood count showed microcytic hypochromic anemia (Hb-9.4 P/s - Microcytic hypochromic blood picture). Ultrasound abdomen was done which showed multiple, un-echoic variable sized cystic lesions in subcutaneous region extending from left pectoral to inguinal region s/o lymphatic malformation like lymphangioma and lymphovenous malformations. Left lower limb local area ultrasound showed diffuse increase in thickness and heterogeneity of subcutaneous fat due to

lipomatosis. Large multi septate lesion measuring about 12.3x 12.6x23.5 in subcutaneous plane was noted on ultrasound on left side of neck, thorax, abdomen, pelvis and thigh extending anteriorly and posteriorly over back, not crossing the midline. There was no extension in thoracic or abdominal cavity. Inferiorly it was extending to subcutaneous plane in left gluteal region. Left vulval wall Lymphatic malformation likely lymphangioma was also seen on ultrasound. The findings of ultrasound were confirmed by MRI which showed diffuse hyperintense swelling involving left side of the body. There was intense post contrast enhancement [Figure 3].

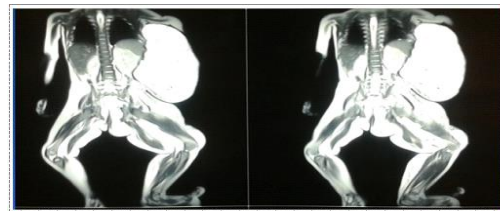


Figure 3: MRI showing hyperintense swelling involving left side of the chest abdomen, gluteal region and lower limb. Intense post-contrast enhancement was noted.

On the basis of above triad of port wine stain, limb hypertrophy and varicosities a diagnosis of Klippel-Trenaunay syndrome was made. Under all aseptic precautions 120 ml of lymph was removed from lymphatic malformation over left thoraco-abdominal region and inj Setrol 66% (4 cc) was injected into the lesion.

The patient was advised elastic compression stockings and parents were told to keep child's affected limb in elevated position whenever possible. Later she was discharged with an advice for regular follow up.

DISCUSSION

Klippel-Trenaunay syndrome is a rare vascular abnormality characterized by classical triad of capillary malformations (hemangioma or port-wine stain), venous varicosities, and bony or soft-tissue hypertrophy. It is most commonly sporadic, although few familial cases have been reported. Since it is a congenital disease the swelling becomes apparent in early childhood but it is important to remember that there may be cases in whom the features may not develop until adulthood.^[6]

The exact cause of KTS is not known. There are various theories put forward by various authors. It is hypothesized that mesodermal abnormality during fetal development leads to vascular and soft tissue malformations in the affected limb.^[7] McGrory & Amadio believed that an underlying mixed mesodermal and ectodermal dysplasia was responsible for development of KTWS. Klippel-Trenaunay Syndrome might also develop due to a single gene defect. Rarely it can be inherited as an autosomal dominant trait.^[8]

Swelling is usually present at birth and involves a lower limb but may involve more than one limb as well as portions of trunk or face. Enlargement of soft tissues may be gradual and may involve the entire extremity, a portion of it, or selected digits. The vascular lesion most often is a capillary malformation, generally localized to hypertrophied area. The deep venous system may be absent or hypoplastic. Venous blebs and/or vesicular lymphatic lesions may be present on the malformation's surface. Thick walled venous varicosities typically become apparent ipsilateral to the vascular malformation after child begins to ambulate. Hemangiomas are often apparent at birth or by second week of age. Capillary hemangiomas (port wine stains) are the most common type. If large enough, cutaneous hemangiomas may cause sequestration of platelets, leading to Kasabach-Merritt syndrome, a type of consumptive coagulopathy. The hemangioma often overlies the vascular malformation. Varicose veins result from damaged or defective valves in a vein. Vein gets damaged when the smooth muscle in the wall of vein weakens and the valves cannot support the weight of blood. Bone and soft tissue hypertrophy is a result of increased growth. In many cases, limb length is affected. In most cases, the girth of the limb is larger, although atrophy is seen in some patients. The various complications seen in KTS include gait disturbance due to unilateral hypertrophy, venous thromboembolism, cellulitis, consumptive coagulopathy, variceal bleeding which can be massive and life threatening, scoliosis and chronic pain in the affected limb. There are case reports of KTS to be associated with renal involvement like nephrotic syndrome, hydronephrosis, renal haemangiomas and focal segmental glomerulosclerosis.^[9]

As there is no curative treatment the management consist of multidisciplinary approach with an aim to reduce pain and complications. Conservative management like leg elevation and compression garments may help reduce swelling associated with varicosities. Since these patients are prone for thromboembolism prophylaxis for DVT can be given. In married females with KTS hormonal contraceptive pills needs to be avoided because of increased incidence of thromboembolic episodes. Sometimes surgical interventions are needed like orthopaedic surgeries to correct gross limb length discrepancy. Vascular interventions such as surgical stripping, Phlebectomy may also be required in some patients.^[10]

CONCLUSION

Klippel-Trenaunay syndrome is a rare condition characterized by classical triad of capillary malformations, venous varicosities, and bony or soft-tissue hypertrophy. KTS should be considered

in differential diagnosis of all patients presenting with either or all of these features. Though the features usually becomes apparent in childhood it must be kept in mind that some patients may present late even up to adulthood.

REFERENCES

1. The Klippel-Trenaunay syndrome: clinical and radiological aspects. Phillips GN, Gordon DH, Martin EC, Haller JO, Casarella WRadiology. 1978 Aug; 128(2):429-34.
2. Suchitra G, Madhu.R, Srinivasan MS: Klippel Trenaunay Syndrome. e-Journal of the Indian Society of Teledermatology. 2008; 2(4):7-14.
3. Wiedemann HR, Burgio GR, Aidenhofs P, Kunze J, Kaufmann HJ, Schirg E. The proteus syndrome: partial gigantism of the hands and/feet, naevi, hemihypertrophy, subcutaneous tumors, macrocephaly or other skull anomalies and possible accelerated growth and visceral affection. Eur J Pediatr. 1983;140:5-12.
4. Aelvoet GE, Jorens PG, Roden LM. Genetics aspects of the Klippel-Trenaunay Syndrome. Br J Dermatol. 1992;126:603-607.
5. Stringel G, Dastous J: Klippel-Trenaunay Syndrome and other cases of lower limb hypertrophy: Pediatric surgical implications. Journal of Pediatric Surgery, 1987;22(7):645-650.
6. Egemen Cebeci, Secil Demir, Meltem Gursu, et al., "A Case of Newly Diagnosed Klippel Trenaunay Weber Syndrome Presenting with Nephrotic Syndrome," Case Reports in Nephrology, vol. 2015, Article ID 704379, 4 pages, 2015.
7. Baskerville PA, Ackroyd JS, Browse NL. The etiology of the Klippel-Trenaunay syndrome. Ann Surg. 1985 Nov;202(5):624-7.
8. McGrory BJ, Amadio PC. Klippel-Trenaunay syndrome: orthopaedic considerations. Orthop Rev. 1993 Jan;22(1):41-50
9. Ceballos-Quintal JM, Pinto-Escalante D, Castillo-Zapata I. A new case of Klippel-Trenaunay-Weber (KTW) syndrome: evidence of autosomal dominant inheritance. Am J Med Genet. 1996 Jun 14; 63(3):426-7.
10. Kulungowski AM, Fishman SJ. Management of combined vascular malformations. Clin Plast Surg. 2011;38:107-120.

How to cite this article: Valinjar SK, Mokase Y, Samariya P. Klippel-Trenaunay Syndrome: Clinical Features and Imaging of a Rare Syndrome. Ann. Int. Med. Den. Res. 2017; 3(4): PE14-PE16.

Source of Support: Nil, **Conflict of Interest:** None declared