

Visual and Anatomical Outcomes after Single Injection of Intravitreal Bevacizumab (Avastin) in Patients with Diabetic Macular Edema.

Ahmad G Bafaraj¹, Njoud S Alshammari¹, Hadeah S Alshammari¹, Fatimah S Alshammari¹, Anfal K Alibrahim¹, Jluwi S Masaud²

¹Faculty of Medicine, University of Hail, Hail, Saudi Arabia.

²Department of Ophthalmology, King Khaled Hospital, Hail, Saudi Arabia.

Received: May 2017

Accepted: May 2017

Copyright: © the author(s), publisher. It is an open-access article distributed under the terms of the Creative Commons Attribution Non-Commercial License, which permits unrestricted non-commercial use, distribution, and reproduction in any medium, provided the original work is properly cited.

ABSTRACT

Background: Intravitreal bevacizumab has been shown to be an effective treatment of diabetic macular edema (DME). Purpose: To assess the effect of intravitreal bevacizumab (Avastin) on visual acuity and macular thickness in patients with DME. **Methods:** A retrospective, cross sectional study reviewed the clinical records of 130 patients with center-involved DME. 132 eyes of 81 patients who received a single intravitreal injection of bevacizumab in a dose of 0.05ml either alone or with laser therapy were included in the final analysis. Each patient underwent a detailed ophthalmic examination, including best-corrected visual acuity (BCVA) and retinal thickness measurement by optical coherence tomography (OCT), at baseline and at last follow up visit. **Results:** In this study, 132 eyes of 81 patients with diabetic macular edema were studied. 51 (63%) were males and 30 (37%) were females. The age range was from 40 to 70 years with a mean of 58.2 ± 9.4 years. All patients completed 6 months of follow-up. mean visual acuity (VA) improved from 0.80 to 0.60 at 6 months and the mean central macular thickness (CMT) was $459.13 \pm 157.92 \mu\text{m}$ at baseline and it decreased significantly to $330.21 \pm 164.06 \mu\text{m}$ ($p < 0.001$) at 6 months. **Conclusion:** Intravitreal bevacizumab results in significant visual improvement and reduction in macular edema in patients with DME at 6 months follow up.

Keywords: Avastin, Diabetic macular edema, Intravitreal bevacizumab, visual outcome.

INTRODUCTION

Diabetic macular edema (DME) is a common sight threatening complication of diabetes mellitus leading to loss of central vision secondary to abnormal retinal vascular permeability in diabetic retinopathy.^[1] It affects working age population both in the developed and in the developing world. The standard of treatment of DME was established through the Early Treatment of Diabetic Retinopathy Study (ETDRS) that showed that laser photocoagulation reduced the risk of moderate visual loss in patients with clinically significant macular edema (CSME) by approximately 50% at 3 years.^[2] However, with laser treatment, less than 3% of treated patients gain vision and many patients continue to lose vision despite intensive treatment. Therefore, the need for more effective treatments for DME is evident. In recent years, advances in pharmacotherapy, ocular drug delivery, and surgical techniques have shown promise in the treatment of DME. Several new pharmacological agents have been or are being recently tested as treatment options for DME through clinical trials. However, the ones currently available in the market and are commonly used include the intravitreal anti-VEGF agents

ranibizumab and bevacizumab as well as the intravitreal dexamethasone implant. Intravitreal bevacizumab is an off-label option, its use has increased exponentially in the recent years due to its efficacy and economic feasibility. It has been shown to be effective in the treatment of center-involved DME in three phase-3 clinical trials.^[2-4]

Name & Address of Corresponding Author

Dr. Ahmad Ghazi Bafaraj
Faculty of medicine,
University of Hail, Hail, Saudi Arabia.

In addition, the evidence for a beneficial effect of bevacizumab in the treatment of DME is increasing.^[5-11] However, unlike ranibizumab, bevacizumab has not been studied in the setting of large-scale phase-3 trials. Although the BLOT study has demonstrated that bevacizumab has a greater treatment effect than modified ETDRS laser treatment in patients with center-involving persistent DME despite previous laser therapy, the authors suggested that their short-term results must not conclude a clinically meaningful benefit in treating DME with intravitreal bevacizumab and that

verification of clinical benefit will require the conduct of large phase-3 randomized clinical trial.^[10] Although our proposed study is not a clinical trial, but to the most of our knowledge, there has not been any documented case series on the outcome of the use of bevacizumab (Avastin) in patients with DME in Saudi Arabia. Moreover, the large number of DME patients treated at King Khaled Hospital in Hail with bevacizumab will allow for the collection of potentially large data that will contribute towards a big leap in the direction of establishing the definitive role of bevacizumab in the treatment of DME.

MATERIALS AND METHODS

We conducted a retrospective chart review of the medical records of patients with center-involved DME treated with intravitreal bevacizumab (Avastin) between March 2015 and February 2016 at ophthalmology clinic in King Khaled Hospital, Hail, Saudi Arabia. Center-involved DME was defined as clinically significant DME with evidence of retinal swelling involving the center of fovea on OCT and CMT more than 320 microns. We reviewed the clinical records of 130 patients with center-involved DME. 132 eyes of 81 patients, who received a single intravitreal injection of bevacizumab in a dose of 0.05ml either alone or with laser therapy, were included in the final analysis. Each patient underwent a detailed ophthalmic examination, including best-corrected visual acuity (BCVA) measurement by Snellen's Chart and retinal thickness measurement by optical coherence tomography (OCT), at baseline and at last follow up visit. The following data were collected from all patients' files and entered into an electronic spreadsheet for analysis: age, gender, past medical and ocular history, and BCVA and macular thickness pre and post-treatment. Patients were excluded if they have (i) significant other ocular pathology such as; Age-related macular degeneration (AMD), retinal vascular occlusion or glaucoma (ii) DME previously treated with intravitreal triamcinolone and/or other anti VEGF (iii) period of follow up less than 6 months (iv) no OCT data documented as part of their initial or final evaluation (v) non-central DME.

Statistical analysis of the data was done using SPSS version 16.0. Descriptive statistics i.e. mean \pm standard deviation for numerical values and frequencies along with percentages for categorical variables were used to describe the data. Wilcoxon signed ranked test was used for comparison of pre and post injection best corrected visual acuity and central foveal thickness and a P value of <0.05 was considered statistically significant.

RESULTS

In this study, 132 eyes of 81 patients with diabetic macular edema were studied. 51 (63%) were males and 30 (37%) were females. The age range was from 40 to 70 years with a mean of 58.2 ± 9.4 years. [Table 1]. All patients had clinically significant macular edema at the baseline examination. All patients completed 6 months of follow-up with a mean of 6.21 ± 0.83 months (range, 6-9). All patients were of type II diabetes mellitus and mean duration of diabetes was 12.68 (5 – 25) years. Mean number of intravitreal injection was 2.78 ± 0.99 (range 1 – 5). And the mean visual acuity (VA) improved from 0.81 to 0.60 at 6 months for whom VA results were available. Number of injection given was found to be positively correlated with VA ($p=0.042$) [Figure 1]. There was no significant association of macular thickness ($p=0.61$) with number of injections. Optical coherence tomography results were available for only 73 cases at 6-month follow-up. The mean central macular thickness (CMT) was $459.13 \pm 157.92 \mu\text{m}$ at baseline and it decreased significantly to $330.21 \pm 164.06 \mu\text{m}$ ($p<0.001$) at 6 months [Figure 2]. Visual acuity and CMT were found to be improved significantly when baseline values were compared with six months follow up.

Table 1: Clinical characteristics of patient with diabetic macular edema at baseline n=81.

Gender	Percent
Male	63%
Female	37%

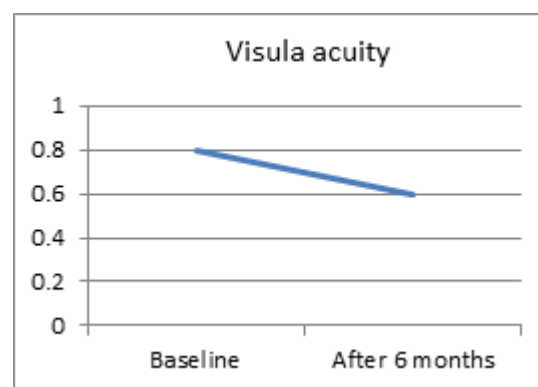


Figure 1: Pattern of VA change in follow up.

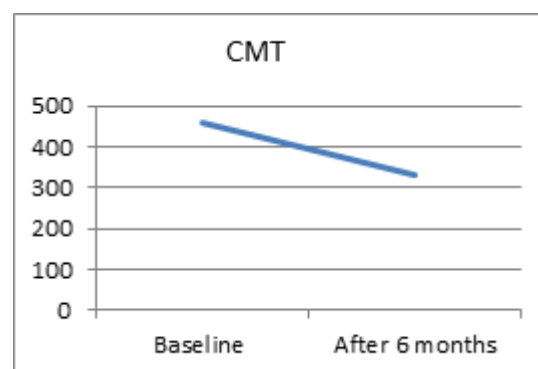


Figure 2: Pattern of CMT change in follow up

DISCUSSION

Diabetic macular edema is a manifestation of diabetic retinopathy that leads to loss of central vision. Several treatment modalities have been studied to treat DME. The standard treatment of DME was established through the Early Treatment of Diabetic Retinopathy Study (ETDRS) that showed that laser photocoagulation reduced the risk of moderate visual loss in patients with clinically significant macular edema (CSME) by approximately 50% at 3 years.^[1] However, with this modality, less than 3% of treated patients gain vision and many patients continue to lose vision despite intensive treatment. Therefore, the need for more effective treatments for DME is evident. There has been an interest in other treatment modalities such as pharmacologic therapy with oral protein kinase C inhibitors and the use of intravitreal corticosteroids.^[12, 13] The use of antibodies targeted at VEGF is another treatment modality that has generated considerable interest and is being investigated. The intravitreal injection of Bevacizumab is another treatment modality of DME that has been met with great enthusiasm especially for patients with central-involved DME. In light of this information we decided to conduct a retrospective, hospital-based study to investigate the visual and anatomical outcome after intravitreal Bevacizumab injection in patients with diabetic macular edema. Bevacizumab has attracted interest because of its low cost; however systemic safety is still of concern.^[14, 15]

This study has shown a visual improvement at 6 months of (0.20 logMAR) which is similar to the studies of Shyam Vyas et al, 2016, Soheilian et al, 2011, and Arevalo et al, 2009 (0.21, 0.24, and 0.27 logMAR, respectively) Lam et al, 2009 study had shown an improvement of 0.10 logMAR at 6 months. This difference might be related to a better mean baseline visual acuity in Lam et al study, 2009, with 0.61 compared with 0.81, 0.80, 0.78, and 0.87, in our present study and studies by Shyam Vyas et al, 2016, Soheilian et al, 2011, and Arevalo et al, 2009, respectively. Also, in our study mean baseline CMT was $459.13 \pm 157.92 \mu\text{m}$, and it was found that better response to the treatment with intravitreal bevacizumab presents among eyes with initial CMT > 350, similar to Shyam Vyas et al, 2016 study. We also observed that intravitreal bevacizumab is more effective in eyes which had no previous DME treatment. 79 % of patients had some kind of laser treatment, focal/grid/PRP during study period. We found that eyes with laser therapy had increased CMT when compared to eyes without laser treatment and this was statistically significant. But mean visual acuity did not differ significantly at 6 months follow up. This finding is supported by Diabetic retinopathy clinical research study, that combining photocoagulation with bevacizumab resulted in no apparent short-term benefit or adverse

outcomes. The combination treatment did not yield better visual or anatomical outcomes reduction at 6 months than bevacizumab injection alone.

One of the limitations of our study is the short follow-up, due to which the long-term safety and efficacy of the treatment could not be assessed. Other limitation is the visual acuity was measured on a Snellen's chart as opposed to the more standardized and accepted ETDRS chart. However, all studied eyes were tested with the same correction throughout the follow-up period.

CONCLUSION

Intravitreal bevacizumab seems to provide significant decrease in macular thickness and improvement in visual acuity in DME patients at 6 months follow-up. Intravitreal bevacizumab also showed equal efficacy both in eyes with or without previous DME treatment. Also, combining photocoagulation resulted in no significant benefit or adverse outcomes. The short follow-up period still not enough to make any specific treatment recommendations; however, the results are promising. Prospective and randomized studies are needed to better determine which patients benefit the most and how often and which concentration the drug should be given. Studies with longer follow-up are also needed to assess the safety and efficacy of bevacizumab in the treatment of DME.

REFERENCES

1. P. Zimmet, K. G. M. M. Alberti, and J. Shaw. Global and societal implications of the diabetes epidemic. *Nature*. 2001; 414 (6865): 782–787.
2. Early Treatment Diabetic Retinopathy Study Research Group. Photocoagulation for diabetic macular edema. Early Treatment Diabetic Retinopathy Study report number 1. *Arch Ophthalmol*. 1985; 103: 1796–806.
3. Ferris FL III, Patz A. Macular edema: a complication of diabetic retinopathy. *Surv Ophthalmol*. 1984; 28(suppl): 452–61.
4. Bresnick GH. Diabetic maculopathy: a critical review highlighting diffuse macular edema. *Ophthalmology*. 1983; 90: 1301-17.
5. J. F. Arevalo, J. G. Sanchez, L. Wu et al. Primary intravitreal bevacizumab for diffuse diabetic macular edema. The Pan-American Collaborative Retina Study Group at 24 months. *Ophthalmology*. 2009; 116 (8): 1488–1497.
6. R. F. Spaide and Y. L. Fisher. Intravitreal bevacizumab (Avastin) treatment of proliferative diabetic retinopathy complicated by vitreous hemorrhage. *Retina*. 2006; 26 (3): 275–278.
7. Haritoglou C, Kook D, Neubauer A, Wolf A, Priglinger S, Strauss R, et al. Intravitreal bevacizumab (Avastin) therapy for persistent diffuse diabetic macular edema. *Retina*. 2006; 26(9):999-1005.
8. Yaseri M, Zeraati H, Mohammad K, et al. Intravitreal Bevacizumab Injection Alone or Combined with Triamcinolone Versus Macular Photocoagulation In Bilateral Diabetic Macular Edema; Application of Bivariate Generalized Linear Mixed Model with Asymmetric Random Effects in a Subgroup of a Clinical Trial. *Journal of Ophthalmic & Vision Research*. 2014; 9(4):453-460.

9. Masoud Soheilian, Alireza Ramezani, Arash Obudi, Bijan Bijanzadeh, Masoud Salehipour, Mehdi Yaseri, Hamid Ahmad. Randomized Trial of Intravitreal Bevacizumab Alone or Combined with Triamcinolone versus Macular Photocoagulation in Diabetic Macular Edema. *Ophthalmology*. 2009; 116 (6): 1142-1150.
10. Michel Michaelides, Andrew Kaines, Robin D. Hamilton, Samantha Fraser-Bell, Ranjan Rajendram, Fahd Quhill, Christopher J. Boos, Wen Xing, Catherine Egan, Tunde Peto. A Prospective Randomized Trial of Intravitreal Bevacizumab or Laser Therapy in the Management of Diabetic Macular Edema (BOLT Study). *Ophthalmology*. 2017; 117 (6): 1078-1086.
11. Klein R, Klein BE, Moss SE, et al. The Wisconsin Epidemiologic Study of Diabetic Retinopathy. IV. Diabetic macular edema. *Ophthalmology*. 1984; 91:1464-74.
12. Strom C, Sander B, Klemp K, et al. Effect of ruboxistaurin on blood-retinal barrier permeability in relation to severity of leakage in diabetic macular edema. *Invest Ophthalmol Vis Sci*. 2005; 46: 3855-8.
13. Campochiaro PA, C99-PKC412-003 Study Group. Reduction of diabetic macular edema by oral administration of the kinase inhibitor PKC412. *Invest Ophthalmol Vis Sci*. 2004; 45:922-31.
14. Iturralde D, Spaide RF, Meyerle CB, et al. Intravitreal bevacizumab (Avastin) treatment of macular edema in central retinal vein occlusion: a short-term study. *Retina*. 2006; 26: 279-84.
15. Maturi RK, Bleau LA, Wilson DL. Electrophysiologic findings after intravitreal bevacizumab (Avastin) treatment. *Retina*. 2006; 26: 270-4.

How to cite this article: Bafaraj AG, Alshammari NS, Alshammari HS, Alshammari FS, Alibrahim AK, Masaud JS. Visual and Anatomical Outcomes after Single Injection of Intravitreal Bevacizumab (Avastin) in Patients with Diabetic Macular Edema. *Ann. Int. Med. Den. Res*. 2017; 3(4):OT07-OT10.

Source of Support: Nil, **Conflict of Interest:** None declared