

Clinical Study of Intertrochanteric Fracture Treated By Trochanteric Femoral Nail (TFN) At Tertiary Centre: A Prospective Study.

A Suryanarayana Rao¹

¹Associate Professor, Orthopaedic department, Meenakshi Medical College Hospital and Research Centre, Enathur, Kanchipuram, Tamil Nadu.

Received: July 2017

Accepted: July 2017

Copyright: © the author(s), publisher. It is an open-access article distributed under the terms of the Creative Commons Attribution Non-Commercial License, which permits unrestricted non-commercial use, distribution, and reproduction in any medium, provided the original work is properly cited.

ABSTRACT

Background: Intertrochanteric fracture is among the common grievous type of injury mostly occurring in elderly patients. In young patients high velocity trauma is the cause of injury. Various type of surgery has been reported in the literature. Trochanteric femoral nailing (TFN) is the emerging option among them. We here show the prospective Clinical study of intertrochanteric fracture treated by Trochanteric femoral nail (TFN) at tertiary centre. **Methods:** In a prospective study of 20 patients of intertrochanteric fracture admitted from March 2015 to June 2016 who were treated with the TFN, clinical study was done. Patients were followed at 6 weeks, 3 months, 6 months, and 12 months. X-ray was done at 6 week. On follow up the activity level and Harris Hip was checked at regular interval at 6 weeks, 3 months, 6 months, and 12 months and recorded. **Results:** 20 patients of intertrochanteric fracture treated with Trochanteric femoral nail from 2015 to 2016 were included in the study. Mean age of the patients was 53.8 year (range 35-77 year). Most of the injury was due to simple fall (82.5%). 12 patients had right hip involvement and 8 patients had that of left hip. Mean average delay for surgery was 10.36 days. Average surgery time was 65.34 minutes (54 minute to 95 minutes). Closed reduction was done in 16 patients and open reduction in rest 4 patients. The fracture consolidated in all 20 patients. Intraoperative complication included fixation in varus in 1 patient. Post operatively there was superficial infection in 2 patients (10%). 1 patient had deep infection (5%) that required debridement and IV antibiotics. There was no limb length discrepancy, Z-Effect, reverse Z-Effect, Intraoperative guide wire breakage or femur fracture. On follow up the activity level and Harris Hip was checked at regular interval at 6 weeks, 3 months, 6 months, and 12 months. Most patients were able to perform house hold activities and were able to walk outside and to their work. The ambulation was started on 4th -10th post operative day. In our study 15 patients were having no post-operative pain at 12 weeks, 3 patients had slight postoperative pain and 2 patients had mild post-operative pain. There was significant improvement in pain with subsequent follow-ups. As per Harris hip score, 16 patients (80%) had excellent results with score more than 90, 2 patients (10%) had good result with score between 80-90, 2 patients (10%) had fair result with score between 70-80 and none had poor result. **Conclusion:** Trochanteric femoral nail is an excellent implant of choice for proximal femur fracture. Rapid rehabilitation, early weight bearing and earlier discharge from hospital are achieved. But it has some technical difficulties and it need expert hand as proper reduction has to be achieved before putting the implant.

Keywords: Femoral Nail, Fracture, Intertrochanteric Fracture.

INTRODUCTION

Intertrochanteric fracture is among the common grievous type of injury mostly occurring in elderly patients. In young patients high velocity trauma is the cause of injury.

Name & Address of Corresponding Author

Dr. A Suryanarayana Rao.
Associate Professor, Orthopaedic department,
Meenakshi Medical College Hospital and Research
Centre, Enathur, Kanchipuram, Tamil Nadu.

The incidence of intertrochanteric fracture is rising because of the increasing life expectancy superadded with osteoporosis. These fractures are 3-4 times more common in women and the mechanism of injury is usually due to low-energy trauma like a simple fall.^[1] Surgical techniques for hip fractures was introduced in the 1950s with the expectation of improved functional outcome and a reduction of the complications associated with immobilisation and prolonged bed rest.^[2,3] Since then a variety of different implants had been used either extramedullary or intramedullary in nature. Treatment options for femur fracture patients

depend on the location and pattern of the fracture. The treatment of intertrochanteric fractures remains a challenge. Various operative procedures with different implants have been described in literature. Extramedullary fixation (dynamic hip screw) and intramedullary implants (TFN, PFN, and Gamma Nail etc.) are two methods of fixations for intertrochanteric fractures⁴. Intramedullary devices, although technically difficult seems to have a biomechanical advantage over laterally fixed side plates.^[5,6] Biological advantage includes close reduction, less soft tissue dissection and comparatively less blood loss. Intramedullary devices such as trochanteric femoral nail (PFN), are more stable under loading with a shorter lever arm, so the distance between the hip joint and the nail is reduced compared with that for a plate, thus diminishing the deforming forces across the implant. These are load sharing devices; so early weight bearing can be allowed. The biomechanical advantage of intramedullary devices is important particularly in unstable trochanteric and subtrochanteric fractures.^[7,8] We here show the prospective clinical study of intertrochanteric fracture treated by Trochanteric femoral nail (TFN) at tertiary centre.

MATERIALS AND METHODS

This study was a prospective outcome study conducted in the department of orthopaedics of Meenakshi Medical College Hospital and Research Centre, Enathur, Kanchipuram, Tamil Nadu from March 2015 to June 2016. 20 patients with intertrochanteric fracture were included in the study. Patients with open wound and medical contraindication were excluded from the study. Initially Patients were examined and admitted as per inclusion and exclusion criteria. Limb was stabilised with skin traction. Preanaesthetic checkup was done for surgery. Patients were operated and Trochanteric fixation nailing was done. Closed or open reduction was achieved as per the fracture condition. First wound inspection was done at 4th day of surgery and discharged if wound was dry. Patient was called for stitch removal on 14th day as per protocol and was asked to come for follow up at 6 weeks, 3 months, 6 months, and 12 months. X-ray was done at 6 week followed by partial weight bearing if sign of union was assessed and gradually shifted to full weight bearing in next 2-4 weeks. On follow up the activity level and Harris Hip was checked at regular interval at 6 weeks, 3 months, 6 months, and 12 months and recorded.

RESULTS

Out of 20 patients of intertrochanteric fracture treated with Trochanteric femoral nail from 2015 to

2016, 12 patients were male and 8 were female (male predominance) [Chart 1].

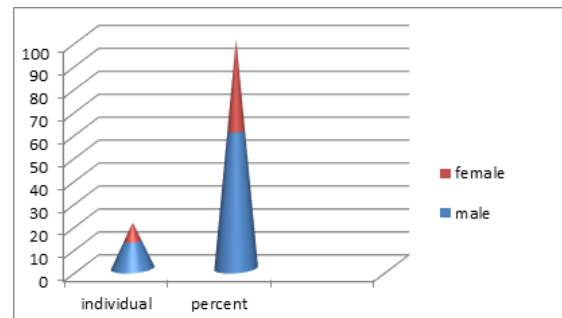


Chart 1: Showing male predominance

Mean age of the patients was 53.8 year (range 35-77 year). 87.40% of patients were of physically active age group. Most of the injury was due to simple fall (82.5%) and 17.5% as a result of road traffic accident (RTA)

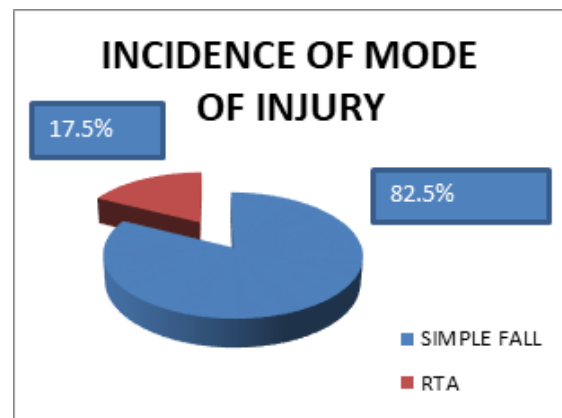


Chart 1: Showing incidence of mode of injury

Out of 20 patients, 12 patients had right hip involvement and 8 patients had that of left hip. Mean average delay for surgery was 10.36 days (range 2 to 25 days). There was delay in surgery after admission as patient was not fit for surgery at the time of presentation. And it took time to optimize the patient for surgery. Average surgery time was 65.34 minutes (54 minute to 95 minutes). Closed reduction was done in 16 patients and open reduction in rest 4 patients. Out of 20 patients, near anatomic reduction was seen in x-ray in 19 patients. The fracture consolidated in all 20 patients. 15 patients (75%) showed sign of union at the end of 12 weeks and 5 patients (25%) showed union by end of 18 weeks. Intraoperative complication included fixation in varus in 1 patient. Post operatively there was superficial infection in 2 patients (10%). 1 patient had deep infection (5%) that required debridement and IV antibiotics. There was no limb length discrepancy. There was no Z-Effect and reverse Z-Effect. There was no Intraoperative guide wire breakage or femur fracture. Patients were discharged early from the

hospital after 4 days after first wound inspection and stitch removal was done after 14 days of surgery. On follow up the activity level and Harris Hip was checked at regular interval at 6 weeks, 3 months, 6 months, and 12 months. Most patients were able to perform house hold activities and were able to walk outside and to their work. The ambulation was started on 4th -10th post operative day. All the patients were able to walk comfortably with partial weight bearing walking with walker. After 6 weeks, many patients walked comfortably without walker just holding the walking stick. In our study 15 patients were having no post-operative pain at 12 weeks, 3 patients had slight postoperative pain and 2 patients had mild post-operative pain. There was significant improvement in pain with subsequent follow-ups. As per Harris hip score, 16 patients (80%) had excellent results with score more than 90, 2 patients (10%) had good result with score between 80-90, 2 patients (10 %) had fair result with score between 70-80 and none had poor result.

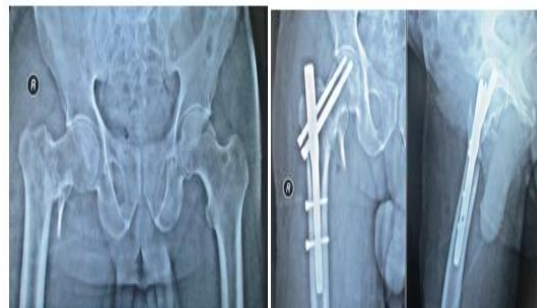

Figure 3: Preoperative and postoperative X-ray.

DISCUSSION

Intramedullary devices such as trochanteric femoral nail (TFN), are more stable under loading with a shorter lever arm, so the distance between the hip joint and the nail is reduced compared with that for a plate, thus diminishing the deforming forces across the implant. These are load sharing devices; so early weight bearing can be allowed. The biomechanical advantage of intramedullary devices is important particularly in unstable trochanteric and subtrochanteric fractures.^[7,8] In our study Out of 20 patients, 12 patients were male and 8 were female. So it was male predominance. This clearly reflected the more active life-style of male in Indian population. The result were opposite to the study done by David G. Lovelle,^[9] who found trochanteric fractures more common in women and the ratio of female to male 3:1 but Gadgone and Salphale et al found 62% male and 38% were female in their study.^[10]

Mean age of the patients was 53.8 year (range 35-77 year) in our study. 87.40% of patients were of physically active age group. Most of the injury was due to simple fall (82.5%) and 18.5% as a result of road traffic accident Cummings SR et al,^[11] Wallace WA et al told that Intertrochanteric fractures constitute one of the commonest fractures of the hip. They mainly occur in elderly people with osteoporotic bone usually due to low energy trauma like simple fall.

In our study Mean average delay for surgery was 10.36 days (range 2 to 25 days) as patient was not fit for surgery at the time of presentation. And it took time to optimize the patient for surgery. Average surgery time was 65.34 minutes (54 minute to 95 minutes). In a study by Rahul M Salunkhe et al had average hospital stay of 12.5 days.^[12] In a study by Tyllianakis et al,^[13] average duration between injury and surgery was 3 days (range 1-7 days). Gadegone et al and Salphale et al had average duration of surgery of 50 minutes (ranging from 45 to 65 minutes).^[10]

The fracture consolidated in all 20 patients. 15 patients (75%) showed sign of union at the end of 12 weeks and 5 patients (25%) showed union by

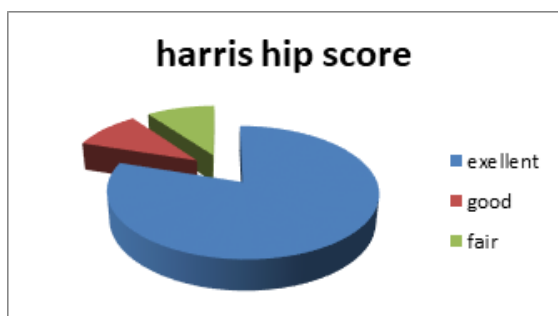


Chart 3: Showing results through harris hip score.

No patients had significant fixed flexion deformity, fixed abduction deformity.

Below are shown preoperative and postoperative X-ray of operated patients [Figure 1,2,3].

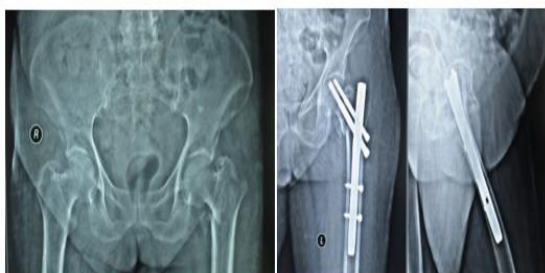

Figure 1: Preoperative and postoperative X-ray.

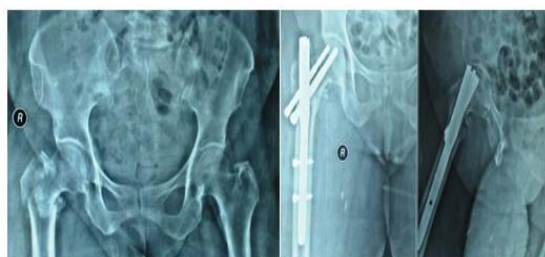

Figure 2: Preoperative and postoperative X-ray.

end of 18 weeks. Khaled Issa et al showed similar results in his study.^[14] Average healing time was 12 weeks with using TFN in unstable trochanteric fractures. Gadgone and Salphale in their study had similar findings that had union in all cases between 15 weeks to 21 weeks.^[10]

Intraoperative complication included fixation in varus in 1 patient. Post operatively there was superficial infection in 2 patients (10%). 1 patient had deep infection (5%) that required debridement and IV antibiotics. There was no limb length discrepancy. There was no Z-Effect and reverse Z-Effect. There was no Intraoperative guide wire breakage or femur fracture. No patients had significant fixed flexion deformity, fixed abduction deformity. Russel et al concluded that acceptable reduction is < 5 degree of angulation in any plain and they had similar findings with malreductions more than 5 degree in 10% cases and acceptable reduction in 90% cases which is comparable to our study.^[15,16]

Patients were discharged early from the hospital after 4 days after first wound inspection and stitch removal was done after 14 days of surgery. On follow up the activity level and Harris Hip was checked at regular interval at 6 weeks, 3 months, 6 months, and 12 months. As per Harris hip score, 16 patients (80%) had excellent results with score more than 90, 2 patients (10%) had good result with score between 80-90, 2 patients (10 %) had fair result with score between 70-80 and none had poor result.

CONCLUSION

From our study we reached to the conclusion that Trochanteric femoral nail is an excellent implant of choice for proximal femur fracture. Rapid rehabilitation, early weight bearing and earlier discharge from hospital are achieved. But it has some technical difficulties and it need expert hand as proper reduction has to be achieved before putting the implant.

REFERENCES

1. Dimon JH, Hughston JC. Unstable intertrochanteric fractures of the hip. *J Bone Joint Surg Am.* 1967; 49(3):440-50.
2. Massive WK. Fracture of hip bone joint surgery 1964; 46a: 658.
3. Hugh WL. A self adjusting nail plate for fracture about hip Joint, *J bone joint surgery* 1955; 37A:1085-1093.
4. Schipper IB, Marti RK, Werken C, Van Der. Unstable trochanteric femoral fractures: extramedullary or intramedullary fixation Review of literature, 2004.
5. Friedl W, Clausen J. Experimental examination for optimized stabilisation of trochanteric femur fractures, intra or extramedullary implant localisation and influence of femur neck component profile on cut-out risk. *Chirurg* 2001; 72:1344-52.
6. Curtis MJ, Jinnah RH, Wilson V, Cunningham BW. Proximal femoral fractures: a biomechanical study to

- compare intramedullary and extramedullary fixation. *Injury.* 1994; 25:99-104.
7. Sermon A, Broos PLO. The use of PFNA in treatment of intertrochanteric fractures. *Folia Traumatologica* 2007: 48-52.
8. *ActaorthopaedicaBelgica* 2004 vol 70-5-2004page 444-454
- Sudhir S Babhulkar. Management of trochanteric fracture. *I J O* Oct 2006; 40(4) : 210-218 .
9. Dean GL, David S, Jason HN. Osteoporotic pertrochanteric; management and concurrent controversies. *J Bone Jt Surg (Am)* 72-B: 737-752.
10. Gadegone WM, Salphale YS. Proximal femoral nail – an analysis of 100 cases of proximal femoral fractures with an average follow up of 1 year. *International Orthopaedics* 2007; 31(3):403-8.
11. Cummings SR, Rubin SM, Black D. The future of hip fractures in the United States: Numbers, costs, and potential effects of postmenopausal estrogen. *ClinOrthop* 1990; 252:163-166.
12. Salunkhe RM, Limaye S, Biswas SK, Mehta RP. Cemented hemi-arthroplasty in proximal femoral fractures in elderly with severe osteoporosis: a case series. *Med J DY Patil Univ.* 2012; 5:36-42.
13. Tyllianakis M, Panagopoulos A, Papadopoulos A, Papisimos S, Mousafiris K. Treatment of extracapsular hip fractures with the proximal femoral nail (PFN): long term results in 45 patients. *Acta Orthop Belg.* 2004; 70:444-54.
14. Khaled Issa, Ayman Khalil, Weam Mossa. Trochanteric fractures, the best method of treatment, *Tanta Med. Sc. J* 2008; 3(2):204- 214 .
15. Russel TA, Taylor JC. Technique manual. Memphis: Smith and Nephew Richards, Iric, 1984.
16. Russel TA, Taylor JC. Subtrochanteric fractures of the femur. In: Browner BD, Jupiter JB, and Levine AM. *Skeletal trauma* 2nd edition, Philadelphia, PA: WB Saunders; 1992, 1832-78

How to cite this article: Rao AS. Clinical Study of Intertrochanteric Fracture Treated By Trochanteric Femoral Nail (TFN) At Tertiary Centre: A Prospective Study. *Ann. Int. Med. Den. Res.* 2017; 3(5):OR35-OR38.

Source of Support: Nil, **Conflict of Interest:** None declared