

## Short Term Evaluation of Intra Articular Fracture Fixation of Distal Humerus in Adults without Olecranon Osteotomy (Triceps Splitting Approach).

Debasis Samanta<sup>1</sup>, Sudipta Dasgupta<sup>2</sup>, Abhijit Ghosh<sup>3</sup>, Samares Naiya<sup>4</sup>, Abhilash Sarkar<sup>5</sup>

<sup>1</sup>Medical Officer, Department of Orthopaedics, Egra SD Hospital, Midnapore, West Bengal.

<sup>2</sup>Associate Professor, Department of Orthopaedics, Burdwan Medical College, Burdwan.

<sup>3</sup>Assistant Professor, Department of Orthopaedics, Burdwan Medical College, Burdwan.

<sup>4</sup>Assistant Professor, Department of Orthopaedics, Burdwan Medical College, Burdwan.

<sup>5</sup>Junior Resident, Department of Orthopaedics, Burdwan Medical College, Burdwan.

Received: February 2017

Accepted: February 2017

**Copyright:** © the author(s), publisher. It is an open-access article distributed under the terms of the Creative Commons Attribution Non-Commercial License, which permits unrestricted non-commercial use, distribution, and reproduction in any medium, provided the original work is properly cited.

### ABSTRACT

**Background:** Intra articular fractures of distal humerus represent a challenging problem to modern day orthopaedic surgeons due to the 3-dimensional geometry, limited peri-articular bone stock for internal fixation, intra-articular comminution, and the need for early mobilization. The surgical goals are to obtain anatomic restoration of the articular surface and recreation of joint alignment with stable internal fixation. This study evaluates the functional & radiological outcome of internal fixation without olecranon osteotomy in distal humeral intra articular fracture in adults. **Methods:** Institution based prospective study comprising of 21 patients attending Orthopaedics emergency or O.P.D. of age group above 18 years with intra articular distal humerus fractures, who were operated by olecranon osteotomy approach and followed up for approximately 1 year. Functional and radiological outcomes, and associated complications were evaluated. **Results:** Out of 21 cases, 12 cases had Mayo Elbow Performance Score >90 and 10 cases had MEPS between 75 and 90. **Conclusion:** Triceps splitting approach for distal humerus fracture fixation is associated with excellent functional outcome and patient satisfaction.

**Keywords:** Intra-articular, triceps-splitting, distal humerus, elbow trauma.

### INTRODUCTION

Fractures of the distal humerus represent a challenging problem to the modern orthopaedic surgeon. Important factors to consider are the 3-dimensional geometry, limited peri-articular bone stock for internal fixation, intra-articular comminution, and the need for early mobilization. A population-based study examining all patients presenting to a single centre identified a bimodal distribution with peak occurrences in young males (12-19 years) and elderly females (>80 years). The increasing incidence of this fracture in the elderly patient in association with poor bone quality and comminution has introduced a significant challenge to the reconstructive surgeon.<sup>[1]</sup> Although non-operative care may be appropriate in some situations, the modern literature strongly supports open reduction and internal fixation (ORIF) of intra-articular distal humerus fractures.<sup>[4,5]</sup> The surgical goals are to obtain anatomic restoration of the articular surface and recreation of joint

alignment with stable internal fixation, secure enough to allow early range of motion.<sup>[8]</sup>

#### Name & Address of Corresponding Author

Dr. Abhilash Sarkar  
Junior Resident,  
Department of Orthopaedics,  
Burdwan Medical College,  
Burdwan.

Campbell described the triceps splitting approach for exposure of the distal humerus in 1932. It involves a distal midline triceps tendon split with equal portions of the triceps tendon and its insertion on the olecranon reflected medially and laterally. This study has been conducted in Orthopaedic department of a tertiary care hospital of a developing country for a period of one year on patients suffering from intra articular fracture distal humerus by standard inclusion criteria. Improvement by clinical, radiological and functional aspect will be mentioned according to the standard scoring system.

**Aims and Objectives**

The aim of our study was to evaluate the functional & radiological outcome of internal fixation without olecranon osteotomy in distal humeral intra articular fracture in adults.

1. Evaluation of functional outcome after internal fixation in distal humeral intra articular fracture managed by internal fixation without olecranon osteotomy (Triceps Splitting approach)
2. Evaluation in terms of radiological outcome after internal fixation in distal humeral intra articular fracture managed by internal fixation without olecranon osteotomy.
3. To evaluate complications associated with the procedure.

**MATERIALS AND METHODS**

1. **Study population:** All patient attending in Orthopaedics emergency and O.P.D. of age group above 18 years with intra articular distal humerus fractures in a tertiary care hospital.

**Inclusion Criteria:**

- a) Patient with age group 18 years and above.
- b) Absence of any major comorbid illness.
- c) No patient had previous injuries or symptoms related to either extremity.
- d) Patient should be physically and mentally fit for surgery.

**Exclusion criteria:**

- a) Patients with cardiac, rheumatic or metabolic diseases.
- b) Patients with previous injuries which influences their general function.
- c) Pathological fracture.
- d) Patients with head injuries and its residual morbidities.
- e) Patients with neurological and vascular injuries.
- f) Patients who found the apparatus aesthetically unacceptable.

3. **Study Period:** 1 year approx.

4. **Sample size:** 21 patients

5. **Sample design:** Patients matching the inclusion criteria will be consecutively included in this study till the desired sample size is obtained.

6. **Study design:** Institution based prospective study.

7. **Parameters to be studied:** Parameters for specific objective no. 1.

- a) Residual deformity
- b) Pain
- c) Range of motion of shoulder, elbow, wrist joint
- d) Union time
- e) Physical Activity

**Parameters for specific objective no. 2.**

- a) Callus formation in skiagram
- b) Rotation

- c) Residual deformity in skiagram

**Parameters for specific objective no. 3:**

- a) Infection
- b) Delayed union / Non - union / Mal - union
- c) Peripheral Nerve injury
- d) Vascular damage
- e) Compartment syndrome
- f) Deep venous thrombosis & pulmonary embolism
- g) Osteomyelitis
- h) Iatrogenic Fractures
- i) Shortening
- j) Elbow Stiffness
- k) Wrist, Shoulder & Elbow pain

**8. Study Tools:**

- a) Radiographs
- b) Recon plates
- c) Drill with Drill bits

**9) Study Techniques:**

Clinical evaluation done by standard DASH Score & Follow up.

**10) Plan for analysis of Data:**

The patients will be evaluated both clinically and radiologically at regular interval and result will be analysed after application of appropriate statistics.

After proper pre-anesthetic check up patients were planned for surgery. All implants and instruments were checked preoperatively. Implants that were used namely

1. Recon Plate 3.5 mm
2. One third tubular plate
3. Distal humerus pre-contoured locking plates
4. 4 mm cannulated cancellous screws
5. Kirschner's wire, SS wire, guide wires
6. 3.5 mm cortical screws

An informed written consent was taken before putting the patient for operating in every case in this study.

**After Treatment:**

Long arm plaster of Paris back slab applied. Drain was removed at 48 hrs.

Out of 21 cases, all cases were operated under tourniquet control and tourniquet was released intra-operatively after fixation.

Blood loss in cases operated with tourniquet was measured by collected blood in suction drain.

Blood loss in other cases can be measured with numbers of mops required during surgery plus collection in drain - (one wet mop = 200 ml of blood approx).

The arm was kept elevated for 3-4 days in order to reduce the oedema and inflammation. Wound inspection was routinely done on 5th post operative day.

On average the patients were discharged at the end of the first week. Suture removal was done on 14th post operative day

**Post operative Rehabilitation:**

The patients are put through active elbow motion of flexion and extension, pronation and supination within limits of pain at 5th post-operative day.

**Follow Up:**

Patients were followed-up on a weekly basis for the first six weeks. Then the patients were seen every month for follow up until the 6th post-operative month. After this, they were seen after every three months for one year. Then follow up was done after every six months.

Patients were assessed by any specific complaints condition of surgical scar, superficial temperature, scar tenderness, functional ability, the elbow range of movement, functional outcome by Mayo elbow performance scores (MEPS) and the arm shoulder and hand disability (Disabilities of the Arm, Shoulder and Hand-DASH) scores as well as radiological findings were evaluated at the final follow-up.

Time taken for functional recovery. Range of motion

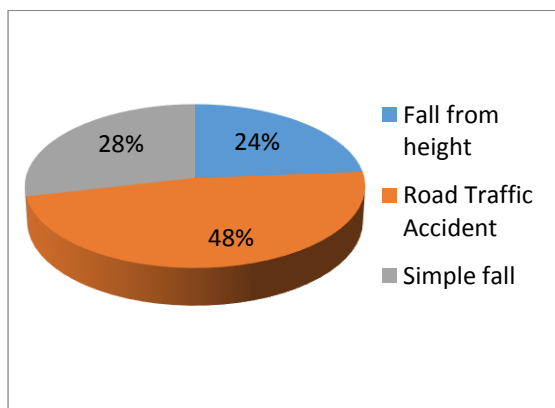
Time taken for fracture healing Any complications Final follow up was done one month before the conclusion of the study and various scoring system and classification were used to analyze the results. Results were analyzed statistically using SPSS software system.

In follow-up examination functional was done by MEPS (Mayo Elbow Performance Score), and DASH (disability of Arm Shoulder and Hand) questionnaire.

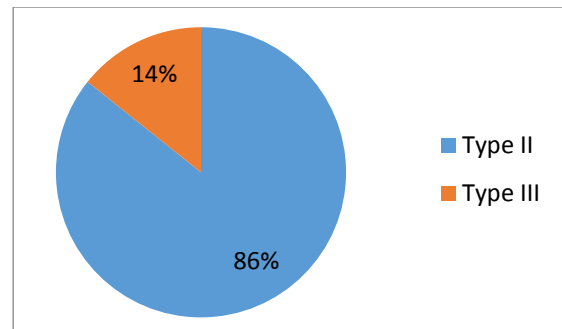
**RESULTS**

**Table 1: Distribution of Study Population According to Age and Sex.**

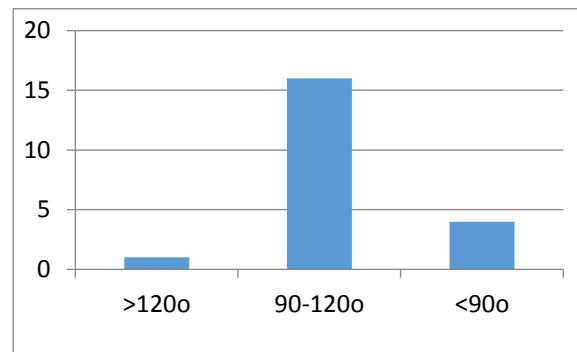
Age Group	No. of Patients	Male	Female
18-25	6	4	2
26-35	2	2	0
36-45	2	2	0
46-55	6	0	6
>55	5	0	5
Total	21	8	13



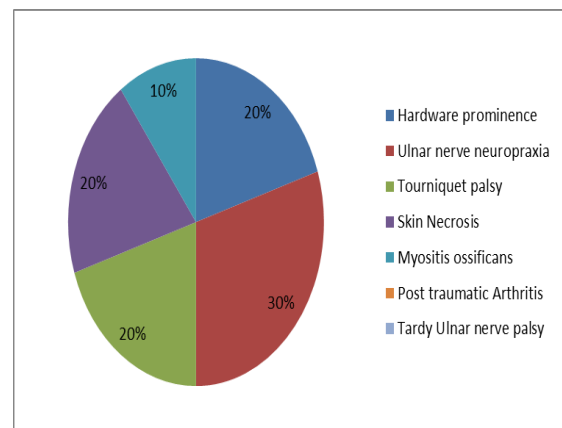
**Figure 1: Distribution of study population according to mode of injury.**



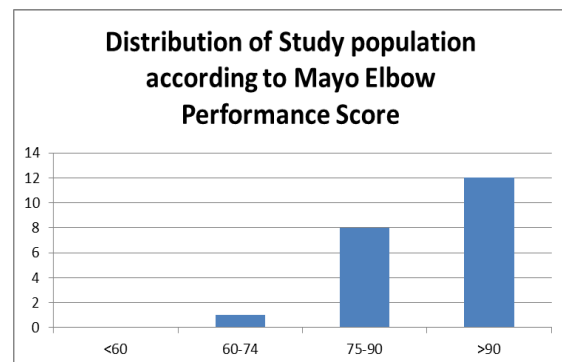
**Figure 2: Distribution of study population according to fracture type.**



**Figure 3: Distribution of Study population according to post operative flexion-extension arc.**



**Figure 4: Distribution of Study population according to Complications.**



**Figure 5: Distribution of Study population according to Mayo Elbow Performance Score.**

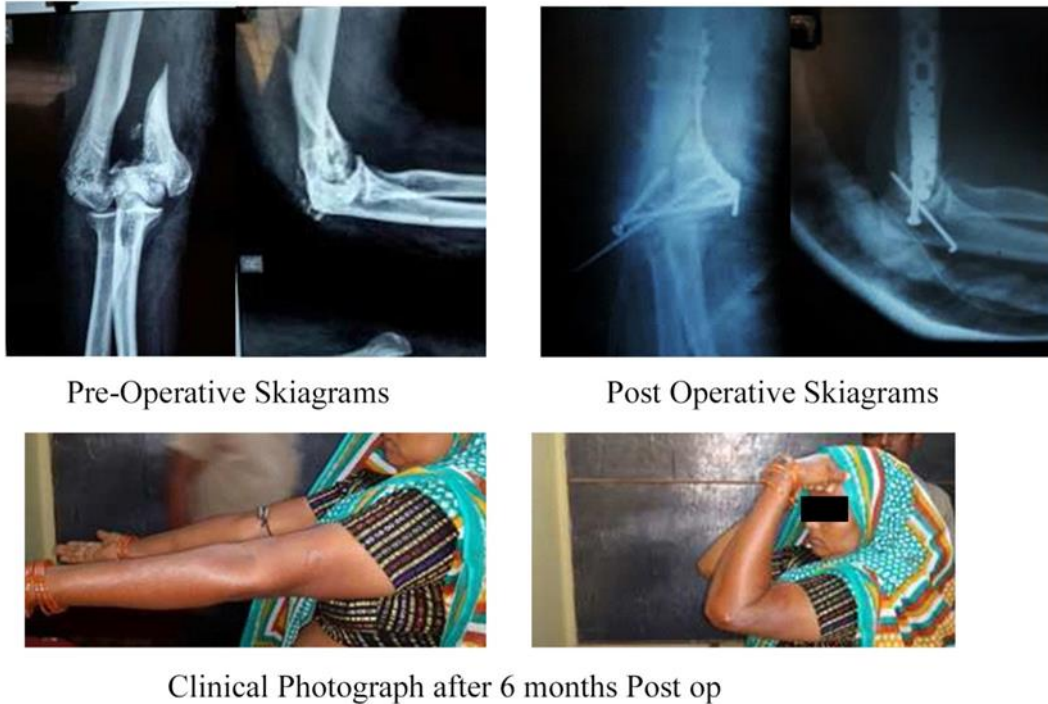

Figure 6: Case Photographs

### DISCUSSION

Distal humerus fractures represent 2% of all fractures and approximately 30% of those involving the humerus.<sup>[6]</sup> Most distal humeral fractures in adults must be treated operatively, in contrast to fractures of the proximal humerus or humeral shaft. Reported mechanism of injury of distal humerus fractures are simple fall, fall from height, road traffic accident. Simple fall being most common. In our series although the most common mode of injury is road traffic accident (48%).

Table 2: Distribution of Study population according to DASH Questionnaire.

DASH Score	No of Pts	Perc (%)
30-34	10	47.7
35-38	8	38
39-42	2	9.5
>42	1	4.8
Total	21	100

In our series females are most commonly involved (62%). Left side of extremity most commonly injured (71%). Most patients in our series were operated within 1 week of injury (54.17%). Distal humerus fractures in our series were classified on the basis of Riseborough classification of fractures. Most of the fractures in our series are Type II (86%), Type III (14%). All fractures were operated by triceps splitting approach for reduction of intra-

articular comminution. The help of image intensifier was taken in some cases.

In operative procedure the length of incision were 12-14 cm (48% of cases), 15-16 cm (42% of cases), >17 cm (9% of cases). Tourniquet time for the operative procedure in most of the cases was between 1.51-1.75 hours (50%).

Most of the surgery takes 2 hours of duration (71%). Increased duration in surgery is related mostly with complexity of fracture configuration (mostly in Type III). Blood loss of most patients was between 150-200 ml (54.17%). Most of the patients (58.33%) have follow up of 3 months in this series. The last case of this series has follow up of 4 week.

The same approach was used for fixation of distal humerus fractures in case series by Jason ME et al and Ayman MA et al.<sup>[2], [3]</sup>

In our series average age of the patients is 41.38 yrs. Average months of follow up in our series is 60 months (range, three to six months).

But mean duration of follow up in Jason ME et al is twenty seven months (range, five to eighty-two months). In series by Ayman MA et al mean duration of follow up was 30 months (range : 24 to 36)

Average interval during date of injury and date of operation (injury - surgery interval) is 10.37 days in our series.

In our series 86% patients had Riseborough Type II fractures.

In our series average length of incision is 15.5 cm. Significant correlation was found between fracture type and length of incision.

Average time taken for surgery is 126 minutes. Significant correlation was found between fracture type and time taken for surgery, that is, more complicated fractures need more time for reduction and fixation.

Average arc of motion in our series is 101.5 degree (range 70 to 130 degree), No significant correlation was found between fracture type and average arc of motion. The series by Jason ME et al shows mean motion arc 115 degree.

Average arc motion of supination/pronation 176.67 degree (range of supination: 70 to 90 degree; range of pronation: 70 to 90 degree). No significant correlation was found between fracture type and supination - pronation arc. The series by Jason ME et al shows that median supination was 90 degree (range, 0 degree to 90 degree), and median pronation was 90 degree (range, 0 degree to 90 degree).

Average DASH is 36 (range 30 to 47) in our series. No significant correlation was found between fracture type and DASH.

In this study it is shown that visibility of fracture site is good in 80% of cases and fair in 20% of cases. All cases with fair visibility were associated with more complex articular comminution. In these cases image intensifier help was taken for doing better articular congruity. 1 case of Type III Riseborough fracture with severe articular comminution was started with this approach, but later olecranon osteotomy was required for better fracture reduction. These cases were not included in this study. Two cases were diagnosed as Type II pre-operatively but per operatively diagnosed as Type III.

Mean time for functional recovery in our study was 100 days.

Mean duration of follow up in our series is less than other series.

Functional outcome measured by MEPS is more than other previous series.

Complications that develop in our series were superficial skin infection, hardware prominence, ulnar nerve neuropraxia, tourniquet palsy, skin necrosis. Heterotrophic ossification, non-union of fracture site, deep infection was not seen in any case.<sup>[7]</sup>

Out of 2 patients with hardware prominence 1 patient developed symptoms like pain, irritability. We removed the implants of this 1 patient after clinical and radiological evidence of fracture union at around 12 months. The patient was relieved of his symptoms and subsequently regained full range of motion of the affected elbow.

Another significant complication was necrosis of skin around dorsal incision site. It may be due to internal degloving of soft tissue at the time of high velocity trauma, and was evidenced by extensive bruising around injured elbow and intra operative finding of internal degloving.

Patients underwent debridement of all devitalised and necrotic tissue. Regular dressing of the wound was done and it healed with secondary intention.

Superficial infections were managed by regular dressing of wound and appropriate antibiotics according to culture and sensitivity report.

2 patients developed ulnar nerve neuropraxia immediately after surgery. Spontaneous resolution was seen in one patient after 2 months post-op, which is probably due to traction neuritis. One case of neuropraxia resolved after hardware removal at 12 months.

So, the results of our study is compatible with previous studies in terms of reduction and fixation of distal humerus fractures and visibility of fracture site, flexion - extension, arc of motion, supination - pronation arc, Mayo elbow performance score, strength of triceps. Complications like prominence of hardware, superficial infection, and ulnar nerve neuropraxia were more in our series than other authors.

#### **Limitations of Study:**

1. The sample size was small (21 patients only). This was because of our short study period of 1 year.
2. The follow-up period was short when compared to the other studies in literature. The mean follow-up period was 6 months (ranging from 3 months to 9 months).

## **CONCLUSION**

We conclude that triceps splitting approach for distal humerus fracture fixation is associated with excellent functional outcome and patient satisfaction. The advantages of this approach are, less operative time as compared to other extensor mechanism dissociating approaches, providing excellent exposure, allowing early range of motion exercises as extensor mechanism remains almost intact and decreasing the chance of post operative elbow stiffness. In difficult situations where reduction of intercondylar component cannot be achieved, it simply can be converted to olecranon osteotomy approach. Finally complications of olecranon osteotomy like delayed union and non-union of osteotomy site, prominence of hardware, and migration of hardware, blocking elbow extension, can be prevented. So, triceps splitting approach is a simple and safe approach for distal humerus fracture in terms of exposure, reduction, fracture fixation, and finally functional outcome and patient satisfaction.

Our recommendation is triceps splitting approach should be adopted in every case of adult distal humerus fracture. If difficulty arises in reduction, only then it should be converted to olecranon osteotomy approach.

## REFERENCES

1. Riseborough EJ, Radin EL: Intercondylar T fractures of the humerus in the adult. A comparison of operative and non-operative treatment in twenty-nine cases. *J Bone Joint Surg Am* 51:130141, 1969
2. Jason ME, Adam M, Robin H, Matthew AM, Edward VF. Outcomes following distal humeral fracture fixation with an extensor mechanism on approach. *JBJS Am.* 2012; 94:548-53
3. Ayman MA, Ehab YH, Abd-El-RA, Tamer AE. Management of intercondylar fractures of the humerus using the extensor mechanism - sparing paratricipital posterior approach *Acta Orthop. Belg.*, 2008, 74, 747-52
4. Caja VL, Moroni A, Vendemia V, et al: Surgical treatment of bicondylar fractures of the distal humerus. *Injury* 25:433-438, 1994
5. McKee MD, Wilson TL, Winston L, et al: Functional outcome following surgical treatment of intra-articular distal humeral fractures through a posterior approach. *J Bone Joint Surg Am* 82A:1701-1707, 2000
6. Gschwend N, Simmen BR, Matejovsky Z. late complication in elbow arthroplasty *J. shoulder, elbow smg.* 19965 (2pt) 86-96
7. Perez Edward A. Fractures of the shoulder, arm and forearm. In: Canale S. T, editor. *Campbell's Operative Orthopaedics*, 12th ed. Vol III. Philadelphia: Elsevier Mosby; 2013. P. 2862-69
8. Biswas S K. Trauma to elbow-fractures around elbow. In: Biswas S K, editor. *Orthopedics: A postgraduate companion*, 1st ed. New Delhi: Jaypee Brothers Medical Publishers; 2013. P. 372-3.

**How to cite this article:** Samanta D, Dasgupta S, Ghosh A, Naiya S, Sarkar A. Short Term Evaluation of Intra Articular Fracture Fixation of Distal Humerus in Adults without Olecranon Osteotomy (Triceps Splitting Approach). *Ann. Int. Med. Den. Res.* 2017; 3(2):OR18-OR23.