

## Short Term Evaluation of Distal Femoral Fracture Fixation by Locking Plate.

S K Kumar<sup>1</sup>, A Ghosh<sup>2</sup>, S Dasgupta<sup>3</sup>, S Naiya<sup>4</sup>, D Chatterjee<sup>5</sup>, A Sarkar<sup>6</sup>

<sup>1</sup>Junior Resident, Department of Orthopaedics, Burdwan Medical College, Burdwan.

<sup>2</sup>Assistant Professor, Department of Orthopaedics, Burdwan Medical College, Burdwan.

<sup>3</sup>Associate Professor, Department of Orthopaedics, Burdwan Medical College, Burdwan.

<sup>4</sup>Assistant Professor, Department of Orthopaedics, Burdwan Medical College, Burdwan.

<sup>5</sup>Professor, Department of Orthopaedics, Burdwan Medical College, Burdwan.

<sup>6</sup>Junior Resident, Department of Orthopaedics, Burdwan Medical College, Burdwan.

Received: May 2017

Accepted: May 2017

**Copyright:** © the author(s), publisher. It is an open-access article distributed under the terms of the Creative Commons Attribution Non-Commercial License, which permits unrestricted non-commercial use, distribution, and reproduction in any medium, provided the original work is properly cited.

### ABSTRACT

**Background:** Fractures of the distal femur are always regarded with great concern because they are difficult to treat, causing long absence from work. These facts have encouraged surgeons to resort to operative treatment with internal fixation. The options for operative treatment are traditional plating techniques that require compression of the implant to the femoral shaft (blade plate, Dynamic Condylar Screw), antegrade nailing, retrograde nailing, sub muscular locked internal fixation and external fixation. This study evaluates the operative outcomes of fixation of these fractures by locked plates. **Methods:** Institution based prospective study comprising of 20 patients attending Orthopaedics emergency or O.P.D. of age group above 18 years with distal femur fractures, who were operated with open reduction and internal fixation with distal femoral locking plates, and followed up for 1 year. Functional and radiological outcomes, and associated complications were evaluated. **Results:** Out of 20 cases, 17 achieved union, 1 had delayed union and there was a single case of non-union. 75% cases the knee range of motion was excellent to very good, gait and weight bearing after complete union was satisfactory. **Conclusion:** Complications associated with the plate were few and the functional outcome was excellent. Thus, many of the common complications of the conventional plating can possibly be avoided. We therefore recommend the use of locking plate, especially in elderly patients with osteoporotic bone and comminuted fracture.

**Keywords:** Distal femur fracture, distal femoral locking plates, high energy trauma.

### INTRODUCTION

The incidence of distal femur fractures is approximately 37 per 1, 00, 000 person-years.<sup>[1]</sup> Although good internal fixation results have already been reported with these fractures over 30 years ago the number of revisions for non-union, loss of reduction and implant failure has been high.<sup>[2]</sup> The Distal Femoral Locking Compression Plate (DF-LCP) is a further development from the Less Invasive Stabilisation System (LISS) which was introduced in the mid to late 1990's. It is a single beam construct where the strength of its fixation is equal to the sum of all screw-bone interfaces rather than a single screw's axial stiffness or pull-out resistance as seen in unlocked plates. The study is justified for the fact that it will be one of the solutions for the age old complications associated with the treatment of supracondylar fractures with traditional fixed angle plates and nails, like postoperative loss of reduction

(varus collapse) and malalignment due to their inherent lack of rigidity and in some cases, eventual implant failure.

#### Name & Address of Corresponding Author

Dr. A. Sarkar  
Junior Resident,  
Department of Orthopaedics,  
Burdwan Medical College, Burdwan

#### Aims & Objectives:

The aim of our study is to evaluate functional and radiological outcome of distal femoral fracture fixation by locking plate.

1. Short term Evaluation of functional outcome of distal femoral fracture fixation by locking plate.
2. Short term Evaluation of radiological outcome of distal femoral fracture fixation by locking plate.
3. To evaluate complications associated with procedure.

## MATERIALS AND METHODS

In this study 20 patients with distal femur fracture were studied. All the cases were treated at a rural population based tertiary care institute, within a period of 1 year. The method used for fracture fixation was open reduction and internal fixation with distal femoral locking plate (DFLP). The duration of follow up ranged from 6 months to 18 months.

### Patient Selection

#### Inclusion Criteria

- Patient with age group 18 years and above.
- Absence of any major comorbid illness.
- No patient had previous injuries or symptom related to either extremity
- Patient should be physically and mentally fit for surgery.

#### Exclusion Criteria

- Patient with cardiac, rheumatoid or metabolic diseases.
- Patient with previous injury which influences their general function.
- Pathological fracture
- Patients with head injury and its residual morbidities.
- Patient with neurological and vascular injuries.
- Patients who found the apparatus aesthetically unacceptable.

### Preoperative Investigation

- Skiagram of involved extremity with proximal and distal joint.
- CT scan of distal femur and involved joint.
- Haemogram
- Blood sugar level
- Blood urea level
- Serum creatinine level
- serum electrolytes
- Blood group and Rh typing
- Bleeding time, clotting time and prothrombin time
- Chest X-ray postero-anterior view, electrocardiography, 2D Echo and other investigations done in patients as required during anaesthetic evaluation.

### Surgical Technique for Fixing Distal Femur Fractures

Lateral approach used for ORIF of distal femur fractures.

### Post-operative care and Rehabilitation

Proper postoperative rehabilitation is essential to ensure the attainment and maintenance of satisfactory range of motion, strength and function of the knee joint. Rehabilitation should be custom made to the patient and the fracture type, and is easier, more comfortable and more assured with

firm internal fixation. If fracture fixation is stable, then therapy can be started early. The most useful range of motion can be achieved, in the first few weeks of postoperative period. Early Phase (1-3 Weeks) the primary goal is full range of motion, started on 2nd day, if fixation is stable, emphasizing extension, normal patella mobility, control of oedema and pain. Quadriceps strengthening and hamstring stretching exercises are encouraged. Gentle hip and ankle mobilization exercises are continued.

### Continuous passive motion – when started in 1st week has following

#### Advantages

- Improves early range of motion of knee.
- Decreases incidence of deep vein thrombosis and pulmonary embolus.
- Faster pain relief and shorter stay at hospital.
- Better results when used at a rate of 1 cycle per minute, with 40 degrees of maximum flexion for first 3 days.
- Continuous passive motion reverses collagen loss, improves cartilage nourishment, prevents joint stiffness.

Non – weight bearing with crutches or walker support can be initiated in 1st week, if fixation is stable. Sutures are removed between 10th - 12th postoperative days. Late phase (after 3weeks): Continue isometric quadriceps setting exercises, active and passive range motion exercises, seated knee extension procedures. Partial weight bearing is allowed after 3rd week. Full weight bearing is allowed after radiological evidence of healing. (6-12 weeks). Patients with inter condylar fractures and type B and C fractures are not allowed full weight bearing for at least 12 weeks.

### Scoring System

Neer's Functional Scoring was used to assess the outcome of surgery, for adult distal femoral fractures It consists of: Functional (70 units) and Anatomic (30 units).<sup>[10]</sup> The results were evaluated by taking into consideration the following factors: [Pain – 20 points, Function – 20 points, Motion – 20 points, Work – 10 points, Gross Anatomy – 15 points, Roentgenograms – 15 points]

Excellent	> 85 units
Satisfactory	70-85 units
Unsatisfactory	55-69 units
Failure	< 55 units

## RESULTS

**Table 1: Distribution of Study Population According to Age**

Age Group	No Of Patients
18-40	11
>40	9
Total	20

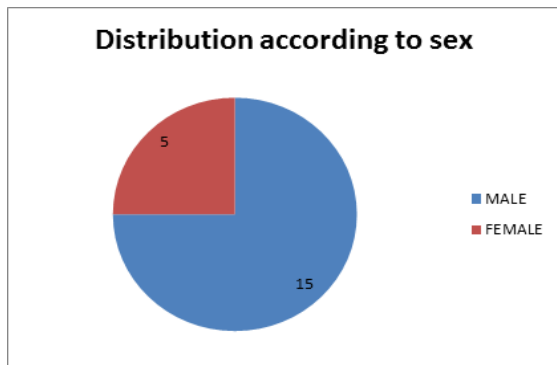


Figure 1: Distribution of Study Population According to Age.

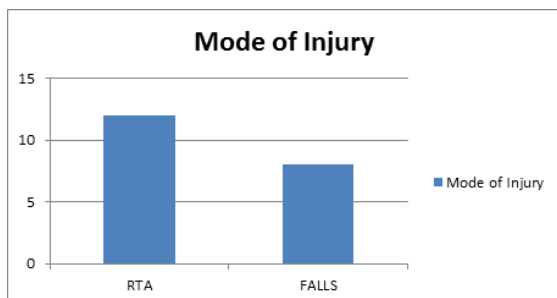


Figure 2: Distribution of study population according to mode of injury.

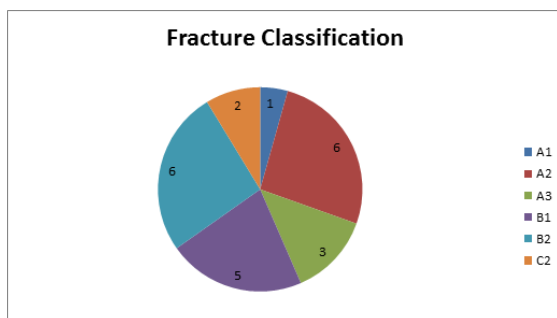


Figure 3: Distribution of study population according to fracture type.

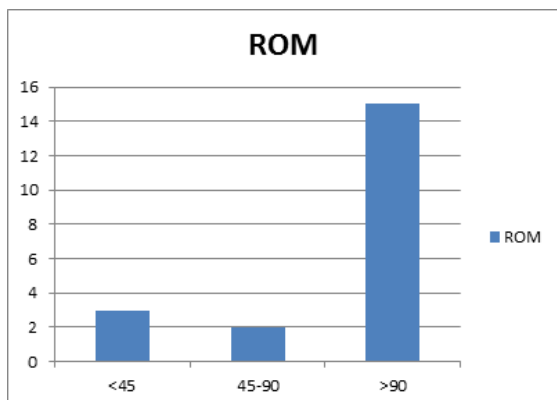


Figure 4: Distribution of study population according to Post-operative Range of Motion.

Table 2: Distribution of Study population according to Complications.

Complications	No of Patients
Infection	3
Non Union	1

Table 3: Distribution of Study population according to Radiological outcome.

Outcome	No of patients
Union	17
Delayed Union	2
Non union	1
Total	20

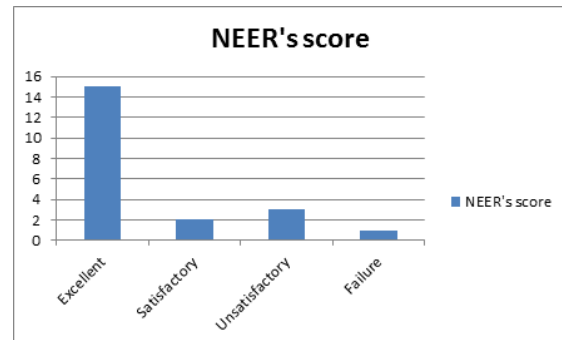


Figure 5: Distribution of Study population according to NEER's functional score.

### DISCUSSION

This study consists of 20 patients with distal femoral fractures, treated with distal femoral locking plates. None of the patients were having bilateral fractures. There were males 15 and 5 females. 5 patients had associated fractures. There were 3 compound fractures (all cases were grade 3). Successful treatment of intra-articular fractures, especially in weight bearing joint, requires restoration and maintenance of the congruence of the two articular surfaces. Distal femoral alignment is one of the treatment priorities. The femoral shaft is oriented 7° of valgus in relation to the knee joint.<sup>[4]</sup> Maintaining this alignment is critical to the function and durability of the limb.

Coronal plane alignment has been shown to be the most difficult factor to control and the most crucial to overall outcome.<sup>[5]</sup> Mal-alignment in the axial and sagittal planes also affect knee kinematics and range of motion.<sup>[6]</sup> When comminution is present, supracondylar femoral fractures are especially prone to varus collapse.<sup>[6]</sup> The current study supports the reduced rate of fixation loss due to the utilization of locked plating and shows that additional lag screws do not influence varus collapse. Patients with greater loss of fixation tend to have a worse outcome. Previous studies stated that open fractures are common in the setting of distal femur fractures (19%–54%).<sup>[7]</sup> Open fractures were related to high-energy injury mechanism and a greater prevalence of infection. Therefore, the outcome of distal femoral fractures, similar to other major injuries, not only depends on bony reconstruction but also on soft tissue management. The DFLP system offers a number of advantages in fracture fixation combining angular stability through the use of locking screws with traditional fixation techniques. However the system

is complex, requiring careful attention to biomechanical principles and good surgical technique. The angular stability provided by DFLP at the plate-screw interface, allows extra periosteal fixation of the plate to bone. By preserving periosteal blood supply to the bone it addresses the importance of the biological factors involved in fracture healing. The principles of flexible fixation are employed where the goal is for indirect healing with the formation of callus.

In our study of 20 patients there were 15 males and 5 females. Most of the injuries were caused by road traffic accidents affecting mostly males. We had 12 (60%) RTA injuries and 8(40%) falls. In our study of 20 patients belonging to AO type A, B and C of distal femur fractures, one belonged to A1, six to A2, three to A3, five to B1, three to B2, two to C2 type fractures respectively. Majority of fractures belonged to type A fracture which was 60% and remaining 40% belonged to other group. Most of surgery done in our study was beyond 14 days with a range 3-20 days. Delay in surgery is one of the factors contributing to unsatisfactory results. Of the 3 unsatisfactory cases, one was delayed up to 20 days due to late presentation to us. Increased duration of hospital stay was also because of other associated injuries and the need for the strict postoperative physiotherapy which affected the course of treatment and rehabilitation. Post-operative physiotherapy was started in bed on the 2nd post-operative day or according to the tolerance of patient and associated injuries. The patients were started with quadriceps strengthening exercises, knee and ankle mobilization exercises. The average time to union was 3.83 months (15.36 weeks) with a range of 2-8 months (8-32 weeks) and a standard deviation of 1.482 in our study. We conclude that time to union in distal femur fractures are generally longer than usual fracture union due to high incidence of comminution and osteoporosis. Type C fractures took longer time to unite compare to type A. Range of motion in our study the mean flexion was 100°. (Range 40°-140°). It was attributed to the stable and study construct and the early range of motion achieved with DFLP. The average knee flexion in type C fractures was less compared to type A fractures, which shows that intra articular fractures lead to intra articular stiffness and decreased range of motion. Four of our patients had extension lag which persisted even after physiotherapy. 15 cases had excellent functional outcome as per NEERs scoring system. 1 case had satisfactory result, 3 had unsatisfactory results. There was a single case of failure due to non-union. We conclude that DFLPs are a useful option in patients with osteoporotic bones and patients with poor bone stock.

### **Summary**

Road traffic accident was the most common mode of injury (90%). There was not a single case with

bilateral fractures. Most of the patients, reported within 1st week of injury to the hospital. AO Type A2 fracture was the most common fracture type 6 out of 20 patients (30%).The shortest follow up period was 6 months and the longest follow up period was 16 months. The average range of knee flexion achieved was about 100 degree. Maximum gain in knee flexion was 140° and minimum gain about 40°. Early complications were encountered in 3 patients and these were superficial wound infection, wound gaping. Late complications due to plate breakage in one patient, and exposed implant in one patient were observed. Postoperative immobilization with knee brace was advised for severely comminuted fractures, for 3 weeks, although gentle physiotherapy exercises were started earlier. The distal femoral locking plate is the treatment of choice in the management of distal Femoral Fractures especially Type A. Though Neer scores are lower in Type C Fractures, it still remains the implant of choice even in Type C fractures.

### **CONCLUSION**

Distal Femoral Locking Plate is the treatment of choice in the management of comminuted distal femoral fractures especially Type A fractures where we have found higher Neer scores. DFLP also prevents compression of periosteal vessels. It may not completely solve the age old problems associated with any fracture like nonunion and malunion, but is a valuable technique in management of these fractures.<sup>[8,9]</sup>

However in type C fractures the outcome is poorer. But still DFLP remains the implant of choice for type C fractures, though complications like knee stiffness and extensor lag were encountered in a few cases.

DFLP shows better results than DCS and Angle Blade Plate.<sup>[8,9]</sup>

This is ideal to prevent metaphyseal collapse and to maintain limb length in severely comminuted fractures. This technique has a lesser chance of complications like plate or screw breakage, but careful selection of patients and strict adherence to the basic principles of fracture fixation will go a long way in reducing the complications of fracture fixation using locking compression plates.

### **REFERENCES**

1. Martinet, J Cordey, Y Harder, A Maier, M Buhler, G E Barraud. Epidemiology of Fracture of Distal Femur. *Injury*2000; 31: 62-63.
2. Thomas P Reudi, Richard E Buckley, Christopher G Moran. *A O Principles of Fracture Management*. 2nd edition. Switzerland: A O Publishing; 2007.
3. Neer CS II, Grantham SA, Shelton ML. Supracondylar Fracture of the Adult Femur – A Study of One Hundred and Ten Cases. *JBJS Am* 1967 June; 49-A(4): 591-613.

4. Stover M. Distal femoral fractures: Current Treatment, Results and Problems. *Injury* 2001; 32(3): 3-13.
5. Thompson JC. *Netters Concise Atlas of Orthopaedic Anatomy*. 1st edn. Philadelphia: Elsevier Inc;2001.
6. Collinge C A, Wiss D A. Distal Femur Fractures. In: Court-Brown Charles M, editor. *Fractures in adults*, 8th edn. Philadelphia: Wolter Kluwer; 2015. p. 2226-2266.
7. Zlowodzki M, Bhandari M, Marek DJ, Cole PA, Kregor PJ. Operative Treatment of Acute Distal Femur Fractures: Systematic Review of Two Comparative Studies and 45 Case Series. *J Orthop Trauma* 2006 May; 20(5): 366-371.
8. Christopher E. Henderson, Lori L. Kuhl, Daniel C. Fitzpatrick. Healing Complications Are Common After Locked Plating for Distal Femur Fractures. *ClinorthopRelat Res* 2011; 469:1757-1765.
9. Schandelmaier P, Partenheimer A, Koenemann B, Grun OA, Krettek C. Distal femoral fractures and LISS stabilization. *Injury* 2001;32(suppl 3):SC55–SC63

**How to cite this article:** Kumar SK, Ghosh A, Dasgupta S, Naiya S, Chatterjee D, Sarkar A. Short Term Evaluation of Distal Femoral Fracture Fixation by Locking Plate. *Ann. Int. Med. Den. Res.* 2017; 3(4):OR15-OR19.

**Source of Support:** Nil, **Conflict of Interest:** None declared