

# Functional Outcome of Closed Distal Third Tibia Fractures Treated With Open Reduction and Internal Fixation With Locking Compression Plate with Screws and Intramedullary Interlocking Nailing: A Prospective Study.

Gopi Krishna Reddy G<sup>1</sup>, Venkata Subbareddy E R<sup>2</sup>, Arun kumar. N<sup>3</sup>, Sarada Vemapaty<sup>4</sup>

<sup>1</sup>MBBS, DNB Orthopedics, Junior Consultant, Sri Sri Holistic Hospital, Hyderabad.

<sup>2</sup>MBBS, DNB Orthopedics, MRCS, Orthopedic surgeon, Life Care Hospital Abhudhabi.

<sup>3</sup>MBBS, MS, Orthopedic, Senior Consultant, Deccan Hospital, Hyderabad.

<sup>4</sup>MBBS, DNB General Medicine, Consultant Leaf Hospital, Hyderabad.

Received: June 2017

Accepted: June 2017

**Copyright:** © the author(s), publisher. It is an open-access article distributed under the terms of the Creative Commons Attribution Non-Commercial License, which permits unrestricted non-commercial use, distribution, and reproduction in any medium, provided the original work is properly cited.

## ABSTRACT

**Background:** Management and post-operative treatment plan of distal third tibia fracture has always been challenging for Orthopaedic surgeon because of its subcutaneous location, poor blood supply and decreased muscular cover anteriorly, complications such as delayed union, nonunion, wound infection, and wound dehiscence. Distal third tibial fractures are most common now in modern day of living due to increase in motor vehicle accidents and history of falls from heights. Civilization has its own drawbacks in making humankind suffer with increased morbidity and mortality. **Methods:** 24 patients were included in the study, in which 18 fracture were Distal tibial fractures (not involving the articular surface) and 6 fracture were Tibial plafond fractures (involving articular surface). Among them 14 were treated with closed reduction and internal fixation with intramedullary nail and 10 were treated with Open reduction & internal fixation with locking compression plate between April 2010 and May 2012. Patients were followed up for clinical and radiological evaluation. **Results:** Out of total 24 patients, 18 were male (75%) and 6 were female (25%) with age distribution between 18 years to 65 years had closed distal tibial fractures. Out of which 18 fracture were not involving the articular surface and 6 fracture were involving articular surface (Tibial plafond fractures). Among them 14 were treated with closed reduction and internal fixation with intramedullary nail and 10 were treated with Open reduction & internal fixation with locking compression plate between April 2010 and May 2012. Overall result was excellent in 10 patients, good in 9 patients, fair in 5 patients and non in poor category. Two patients had angulation problems and one patient lost follow up at 12 weeks and on further enquiry over phone, he has been operated with exchange nail with two distal locking screws in other hospital and 1 had deep infection, that patient required debridement and antibiotic coverage as per culture & sensitivity and healed later without any skin grafts or flaps. 2 patients had superficial infection and skin necrosis at suture site but they healed without any intervention. **Conclusion:** Majority of distal third tibial fractures are as a result of road traffic accidents. Closed intra-medullary nailing produces good functional outcomes in distal third tibial fractures without intra-articular extension. In distal third tibial fractures with intra-articular extension open reduction & internal fixation with plate and screws has advantages of articular surface reconstruction and anatomical reduction.

**Keywords:** Fractures, Intramedullary Interlocking Nail, Open Reduction And Internal Fixation.

## INTRODUCTION

Fracture of the distal tibia accounts for 7 to 9% of lower extremity fractures, with the fibula fractured

in about 85% of these cases.<sup>[1]</sup>

Fractures of the distal third tibia have become challenging and very important in view of management and post-operative treatment plan for Orthopaedic surgeon. By its location the tibia is exposed to frequently to injuries. Because of its subcutaneous location in more than 1/3 length, open fractures are common and further precarious blood supply makes tibia more prone for infection and non-union.<sup>[2]</sup> Fractures involving the tibial

### Name & Address of Corresponding Author

Gopi Krishan Reddy G  
Junior consultant,  
Sri Sri Holistic Hospital,  
Hyderabad.

shaft extending into the tibial plafond are much less common than fractures of shaft alone.<sup>[3]</sup> They generally result from fall from height and less commonly from a blow on ankle or foot that drives the talus up into the tibial plafond. Because of the transition from metaphyseal bone to diaphyseal bone in the distal part, comminution chances are high and loss of bone stock from the compression of cancellous bone even in closed injuries.<sup>[4]</sup>

The presence of hinge joint at the knee and ankle allows no adjustments for rotatory deformity after fracture and thus special attention is needed for reduction of fracture and maintenance of reduction.<sup>[5]</sup> The spectrum of injuries to tibia is so great that no single method of treatment is applicable to all fractures. The present study compares functional outcome of closed distal third tibia fractures treated with open reduction and internal fixation with locking compression plate with screws and Intramedullary interlocking nailing.

## MATERIALS AND METHODS

A prospective study was conducted on 24 patients with a fracture of distal tibia admitted in department of orthopaedics, Image hospital, Hyderabad, Andhra Pradesh from April 2010 and May 2012. The inclusion criteria included all fracture of distal tibia who got admitted to our hospital. With exclusion criteria including open fractures treated initially with external fixator and then followed by plating or nailing methods, patients not fit for the surgical procedure, patients who got discharged against medical advice and not willing to participate in to the study. Detailed history was taken with particular emphasize on mode of injury and associated medical illness and clinical examination was done. In the examination swelling of the ankle, blister, open wounds, and neurovascular status were noted. Patients were admitted and radiographs of the injured limb were taken extending from one joint above and one joint below in both antero-posterior and lateral view. The fractures of the tibial plafond are classified by Reudi-Allgower and AO/OTA classifications. Gentle manipulation was done and immobilized in above knee plaster of paris slab. The limb is kept elevated and watched for distal neuro-vascular status. Patients are treated with oral or parenteral NSAIDS in view of relieving pain. Routine blood investigations, blood grouping and typing, complete urine examination and viral screen was done. Necessary and adequate treatment was given for co-morbid conditions like anemia, diabetes, hypertension, COPD and cardiac problems. Informed written consent for surgery is taken. Intravenous antibiotics was given an hour before surgery. Surgery was performed and patient was discharged after stitch removal as per protocol.

Follow-up of patients were done at regular intervals. Done at 6th, 12th, 16th, 20th week and at 6 months and above noting the pain, deformity, shortening, range of motion and radiological union. The criteria for assessment were done in accordance with Johner and Wruhs study.

## RESULTS

Out of total 24 patients who were admitted to our hospital and were ready to participate in the study, 18 were male (75%) and 6 were female (25%) [Figure 1] with age distribution between 18 years to 65 years. 10 patients were between 18-30 years (41.66%), 4 patients between 31-40 years (16.66%), 7 patients between 41-50 years (29.16%) and 3 patients between 51-65 years (12.5%) [Figure 2].

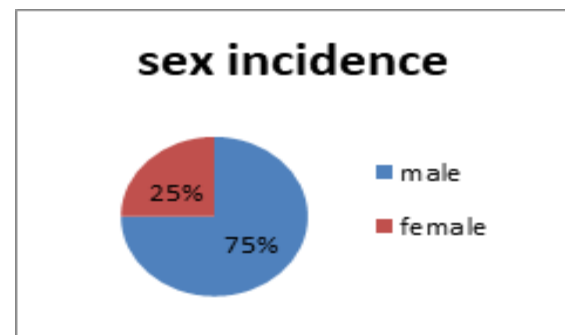


Figure 1: Chart showing sex incidence.

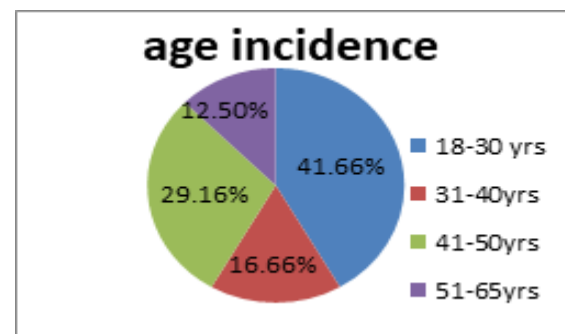


Figure 2: Chart showing age incidence

They had closed distal tibial fractures. Out of which 18 fracture (75%) were not involving the articular surface and 6 fracture (25%) were involving articular surface (Tibial plafond fractures). Incidence of side of limb was 14 in right limb (58.33%) and 10 in left limb (41.66%).

Mechanism of injury was road traffic accident in 16 patients (66.67%), fall in 4 patients (16.67%) and injury at work in 4 patients (16.67%)

Fracture was classified according to AO classification and Reudi & Allgower classification. According to AO classification 18 patients were in type A, 2 patients in type B and 4 patients in type C category. For tibial plafond fracture Reudi & Allgower classification were used. Out of 6

patients, 4 were in type 1, 1 in type 2 and 1 in type 3 category.

Among them 14 (58.33%) were treated with closed reduction and internal fixation with intramedullary nail and 10 (41.67%) were treated with Open reduction & internal fixation with locking compression plate [Figure 3].

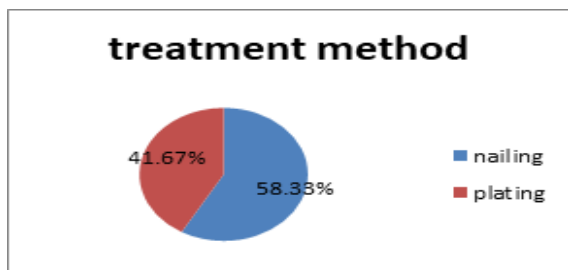


Figure 3: chart-showing percentage of nailing and plating.

With respect to range of motion post operatively there was full range of motion at knee and at ankle full range of movement in 7 patients (70%) in open reduction and internal fixation with plate fixation group and all 14 patients (100%) in intramedullary group and restricted range of movement in 3 patients (30%) in open reduction and internal fixation with plate fixation group and nil (0%) in intramedullary group.

Results with respect to method of treatment were also analysed. 10 patients in which treatment modality was open reduction and internal fixation with locking compression plate had excellent result in 4 patients (40%), Good in 4 patients (40%) and Fair result in 2 patients (20%). 14 patients in which treatment modality was Interlocking nailing had excellent result in 6 patients (42.85%), Good in 5 patients (35.7%) and Fair result in 3 patients (21.4%) [Figure 4].

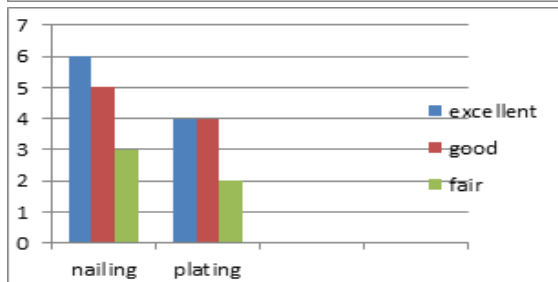
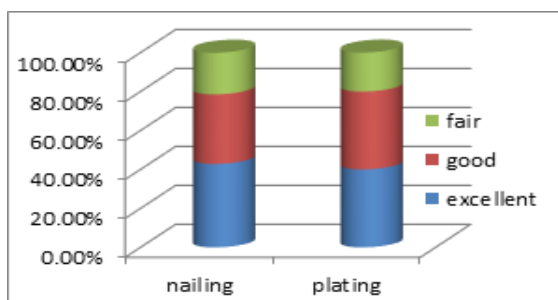
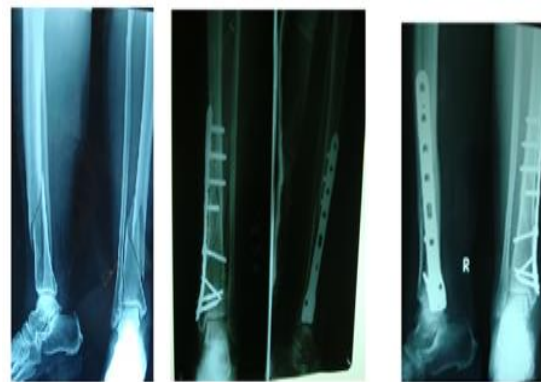

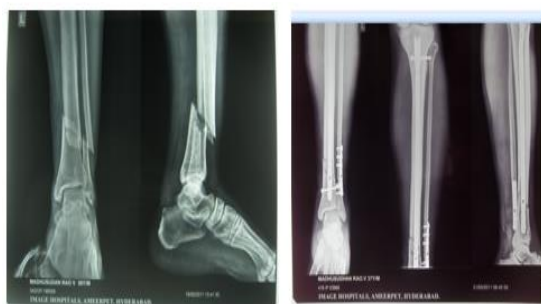Figure 4: chart showing results with respect to method of treatment.

Overall result was excellent in 10 patients, good in 9 patients, fair in 5 patients and non in poor category. Mild angulation and distal screw bending was seen in 1 patient and superficial infections at the surgical site in 2 patients which was treated with wound debridement and antibiotics.

Below are shown some clinical photograph of operated patients [Case 1 & 2].



Case 1: Photograph showing pre-operative x-ray, immediate post-operative x-ray and x-ray at 6 month follow-up after open reduction and internal fixation with locking compression plate.



Case 2: Photograph showing pre-operative x-ray, immediate post-operative x-ray and x-ray at 6 month follow-up after close reduction and internal fixation with intramedullary nail.

Some clinical photograph of complication faced during the study.

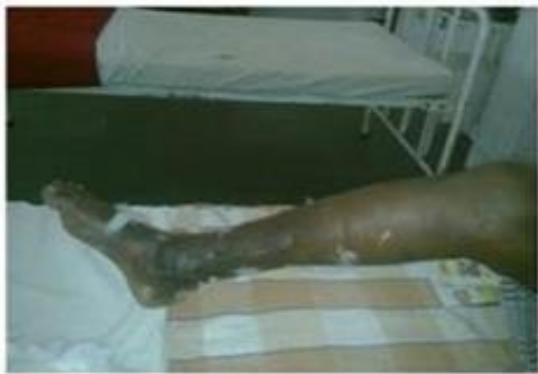**Data Analysis**

Data were analyzed by means and proportions with the help of MS Excel statistical package 2010.

## DISCUSSION

Fractures of distal third tibia are often outcome of high-energy trauma. In many of these cases bone and soft tissue, instability results in unacceptable shortening, angulation or displacement of the fracture. An adequate reduction should be achieved and maintained by some means. A variety of treatment methods are advocated. Eventual radiographic union is not alone a sufficient goal for tibia fracture, the morbidity during treatment, the period of disability, the functional result and the economic consequence must also be considered<sup>6</sup>.

In our study, most of the patients were aged between 18- 30 years. 10 patients between age of 18-30 years (41.66%) and between 41-50 years (29.16%). It showed that distal third tibial fractures are more common in younger individuals and they are attributed to high-energy trauma. Singer BR, McLauchlan GJ, Robinson CM, et al (1998) reported that these fractures are more common in younger age groups.<sup>[7-9]</sup>



**Superficial Infection Healed with secondary intervention.**



**Deep infection healed with debridement and antibiotics.**

In our study, most of the patients were male 18 (75%) and female are 6(25%). Male preponderance has been reported in studies conducted by Michael and Alms (1962) 82% were males and in study conducted by Donald.A.Wiss (1986) 73% were males. Singer BR, McLauchlan GJ, Robinson CM,

et al (1998) reported distal tibial fractures has high incidence in males.<sup>[7,10,11]</sup>

In our series most of the fractures were due to road traffic accidents. 16 out of 24 (66.67%) were due to road traffic accidents and remaining were due to fall from height and injury at work place due to fall of heavy objects.<sup>[12,13]</sup>

In our series of 24 patients, 14 (58.33%) patients had right side involvement. 10 (41.66%) had left side involvement.

The incidence depending on the fracture configuration in our series, as per AO/OTA classification type A is more common. In our series of 24 patients 18 were of type A (75%). Type B fractures were seen in 2 patients and type c i.e. severe comminuted fractures of metaphyses and articular surface were seen in 4 patients.

As per Reudi & Allgower of distal tibial pilon fractures, among 6 intra-articular fractures 4 were of type 1(66.67%). Compared to comminuted fractures simple fractures were common and in simple fractures oblique and spiral fractures were predominant.<sup>[14]</sup>

Treatment methods opted for the study are intra-medullary nailing and open reduction & internal fixation with locking compression plate and screws. In our series of 24 patients, 14 (58.33%) patients were treated with intra-medullary nailing and 10 patients (41.66%) with open reduction and internal fixation with locking compression plate and screws. Among 24 patients, 6 patients had intra-articular fracture extension without displacement to comminution. Tibial pilon fractures are less common than compared to extra-articular fractures. Bone LB (1987) and Mandracchia VJ, Evans RD, Nelson SC, et al (1999) reported that tibial pilon fractures incidence is less.<sup>[12,13]</sup>

In our series, 14 patients were treated with intramedullary nailing, 6 patients (42.85%) showed excellent results. 5 patients (35.7%) were good and 3 patients (21.4%) showed fair results. Average union time was 16.5 weeks. The patient's fair results were due to patient's poor compliance and due to early weight bearing against our advice and comminution. Two patients had angulation problems and one patient lost follow up at 12 weeks and on further enquiry over phone, he has been operated with exchange nail with two distal locking screws in other hospital. One patient had 1cm shortening. One patient had bent distal locking screw, but it didn't show any effect on fracture union. According to Lottes (1974) average union time was 14 weeks 15 and as per Ronaldo et al (1986) average time for union was 15.9 weeks. Donald A Wiss (1986) reported average union time of 18.8 weeks. In a study conducted by Im GI, Tae SK (2005) average union time was 18 weeks.<sup>[16]</sup>

In our series, 10 patients were treated with open reduction and internal fixation with locking

compression plate and screws; we had 40% excellent results, 40% good and 20% with fair results. Average union time was 18.2 weeks. In patients with fair results 1 had deep infection, that patient required debridement and antibiotic coverage as per culture & sensitivity and healed later without any skin grafts or flaps. 2 patients had superficial infection and skin necrosis at suture site but they healed without any intervention. In these patients last 10° of dorsiflexion and plantar flexion was restricted. In a study conducted by Im GI, Tae SK (2005) average union time with open reduction and internal fixation with plate was 20 weeks.<sup>[16]</sup> They reported 20% had superficial infections and 3.3% had deep infections. According to Olereud & Karlstrom, they had healing difficulty in 19% but end results were good.<sup>[2]</sup>

In comparison intra-medullary nailing group had shorter operative times, lesser infection rate and good range of ankle movements. Nailing group had lesser average time of union. Nailing group had chance of early weight bearing as intra-medullary nail is load sharing device.

In nailing group, angulation at fracture site in comminuted fractures is higher. In our study 2 patients had angulation deformity and among them one patient underwent exchange nail in other hospital.

In plating group, fracture reduction is accurate, degree of angulation is less & anatomical reduction will be achieved.<sup>[17]</sup> But this group had higher rates of infection, ranging from superficial infection to deep infections. Deep infection patient required further surgery in the form of debridement and required further hospital stay for intravenous use of antibiotics. Range of movements at ankle like dorsiflexion and plantar flexion are restricted. Plating group had little higher average time of union and this group had higher operative times. This group had delayed weight bearing as plate is load bearing device.

Our study reports are in accordance to reports of study done by Im GI, Tae SK (2005)<sup>[16]</sup> and study by J.J.Guo, N.Tang, H.L.Tang and T.S.Tang et al. and other study by C M Robinson, G J McLauchlan, IP McLean and CM Court Brown et al,<sup>[7]</sup> and Yang SW, Tzeng HM, Chou YJ, et al (2006).<sup>[18]</sup> Rand J.A., Kai Nan An & Kelly P.J.<sup>[19]</sup>

In patients with intra-articular extension of fracture minimally invasive plating method showed excellent results. Plating method helps in reconstruction of articular surface. This is supported by reports of studies done by Oh CW, Kyung HS, Park IH, et al (2003),<sup>[20]</sup> Borg T, Larsson S, Lindsjo U (2004), Wyrsh B, McFerran MA, McAndrew M, et al (1996).<sup>[21]</sup>

In patients treated with intramedullary nailing complications observed were angulation and distal screw bending. Angulation was seen most

probably due to early weight bearing and imperfect reduction and fixation.

In patients treated with locking compression plate and screws complications observed were superficial and deep infections at the surgical site, this resulted in delayed bone union. In these patients diabetes mellitus was most probable predisposing factor.

## CONCLUSION

Majority of distal third tibial fractures are as a result of road traffic accidents. Majority of these fractures are seen in young age groups. Majority of fractures occur in males. We agree with Nicoll's statement – initial displacement, severity of injury and comminution were important factors in determining the fracture outcome. Intra-medullary nailing and open reduction and internal fixation with locking compression plate have similar effect on healing process and their final outcome. Our study concluded that closed intra-medullary nailing produces good functional outcomes in distal third tibial fractures without intra-articular extension. Intramedullary nailing has advantages of shorter operative time, early weight bearing, lesser average time of union and lesser rate of infections and good range of movements at ankle. Our results are comparable to other studies. In distal third tibial fractures with intra-articular extension open reduction & internal fixation with plate and screws has advantages of articular surface reconstruction and anatomical reduction.

## REFERENCES

1. Wyrsh B, McFerran MA, McAndrew M. Operative treatment of fractures of the tibial plafond. A randomized, prospective study. *J Bone Joint Surg Am* 1996; 78:1646-57.
2. Oleurd S. & Karlstrom G.: Tibial fractures treated by A.O.compression osteosynthesis, experiences from a 5 year material, *Acta orthop.Scand. Suppl.* 1972; 140:1.
3. Zucman and Maurer P.: Two level fractures of the tibia. *JBJS* 1969; 51-B: 686.
4. Gestern M, Tscherne H. Pathophysiology of soft tissue injury associated with fractures. In Tscherne H., & Gotzsch; fractures with soft tissue injuries Berlin, Springer-Verlag, 1984.
5. Macnab I. & Dettaas W.G.: The role of periosteal blood supply in the healing of fractures of tibia. *Clin.orthop.* 1974; 105:27,
6. Bohler J, Treatment of non-union of the tibia with closed and semi closed intra-medullary nailing, *clin. orthop.* 1965; 43:92-102.
7. Singer BR, McLauchlan GJ, Robinson CM. Epidemiology of fractures in 15,000 adults: the influence of age and gender. *J Bone Joint Surg Br* 1998; 80:243-8.
8. Nicoll E.A. Fractures of tibia. *JBJS.* 1964; 46B:373.
9. Teeny SM, Wiss DA. Open reduction and internal fixation of tibial plafond fractures. Variables contributing to poor results and complications. *Clin Orthop Relat Res* 1993; 108-17
10. Campbell's text book of operative orthopaedics vol III. 11th edition page 3104-3105

11. Nicoll E.A.: Fractures of tibia, a survey of 705 cases. JBJS 1964; 46B:737.
12. Bone LB. Fractures of the tibial plafond. The pilon fracture. Orthop Clin North Am 1987; 18:95-104.
13. Mandracchia VJ, Evans RD, Nelson SC. Pilon fractures of the distal tibia. Clin Podiatr Med Surg 1999; 16:743-67.
14. Yih-Shiunn Lee, MD; Shih-Hao Chen, MD; Jen-Ching Lin, MD. Surgical Treatment of Distal Tibia Fractures: A Comparison of Medial and Lateral Plating.
15. Velazco A., Whitesides T.R.Jr, Flemming L.L. Fractures of the tibia treated with Lottes nail fixation. South Med. J. 1981; 74:427.
16. Im GI, Tae SK. Distal metaphyseal fractures of tibia: a prospective randomized trial of closed reduction and intramedullary nail versus open reduction and plate and screws fixation. J Trauma 2005; 59:1219-23.
17. Janssen KW, Biert J, van Kampen A. Treatment of distal tibial fractures: plate versus nail: a retrospective outcome analysis of matched pairs of patients. Int Orthop 2007; 31:709-14.
18. Yang SW, Tzeng HM, Chou YJ. Treatment of distal tibial metaphyseal fractures: Plating versus shortened intramedullary nailing. Injury 2006; 37:531-5.
19. Rand J.A., Kai Nan An & Kelly P.J. A comparison of the effect of open intramedullary nailing and compression plate fixation on fracture site, blood flow and fracture union. JBJS 1981; 63A:427.
20. Oh CW, Kyung HS, Park IH. Distal tibia metaphyseal fractures treated by percutaneous plate osteosynthesis. Clin Orthop; 2003; a: 286-91.
21. Borg T, Larsson S, Lindsjo U. Percutaneous plating of distal tibial fractures. Preliminary results in 21 patients. Injury 2004; 35:608-14.

**How to cite this article:** Reddy GKG, Subbareddy VER, Kumar AN, Vemapty S. Functional Outcome Of Closed Distal Third Tibia Fractures Treated With Open Reduction And Internal Fixation With Locking Compression Plate With Screws And Intramedullary Interlocking Nailing: A Prospective Study. Ann. Int. Med. Den. Res. 2017; 3(5):OR08-OR13.

**Source of Support:** Nil, **Conflict of Interest:** None declared