

Temporal Bone Lesions - An Observational Radiographic Study.

Menon Sachin Venugopal¹, Suresh Padmini¹, Sholy K Vareed²

¹Associate Professor, Department of Medicine.

²Associate Professor, Department of Radiology.

Received: May 2017

Accepted: June 2017

Copyright: © the author(s), publisher. It is an open-access article distributed under the terms of the Creative Commons Attribution Non-Commercial License, which permits unrestricted non-commercial use, distribution, and reproduction in any medium, provided the original work is properly cited.

ABSTRACT

Background: CT examination has helped in early diagnosis, accurate localisation and planning of treatment of temporal bone disease and abnormalities. The aim of the present study is to study the normal anatomical perspective and congenital lesions of temporal bone and to see the accuracy of CT in detecting intra-canalicular space occupying lesion. **Methods:** This prospective and observational study was carried out in 32 patients. Patients were scanned in the axial and coronal planes. The incidence and symptoms of disease were studied according to age and gender. The radiological and intra-operative findings of different temporal lesions were studied and compared. **Results:** Common clinical features were hearing loss (56.2%), ear discharge (37.5%) and facial nerve weakness (37.5%). Commonest lesion of temporal bone was neoplasm. Female preponderance was noted. In our study the commonest tumor was acoustic neuroma. There was excellent correlation between CT and operative findings in case of infections and tumors. **Conclusion:** CT is the best method of choice in detection of temporal bone lesion.

Keywords: Computer tomography scan, Neoplasm, Temporal bone.

INTRODUCTION

Anatomically the temporal bone consists of 5 parts- Temporal squamous including its zygomatic process and root, tympanic, mastoid, petrous and styloid. The petrous bone houses the inner ear (otic labyrinth). Inner ear consists of 2 parts. Osseous labyrinth, a series of bony cavities within the petrous bone, and the membranous labyrinth, a series of communicating membranous sacs and ducts, contained within the bony labyrinth. The knowledge of normal anatomy is indispensable for the recognition and evaluation of pathological conditions.^[1]

Name & Address of Corresponding Author

Suresh Padmini
Associate Professor,
Department of Medicine.

The external auditory canal in the adults is about 2-3 cm in length, oriented directly along the coronal plane. Except for the most superior part, it is completely surrounded by the tympanic bone, which forms an incomplete ring over the meatus. It is covered superiorly by the squamous temporal bone.^[2]

The middle ear is a flattened rectangular chamber oriented along the same oblique plane as the temporal bone. It is divided into mesotympanum or tympanum proper, the epitympanic recess and the hypotympanum. The ossicles for the most part reside within the epitympanic cavity, with the handle of malleus and long process of incus extending downward into the mesotympanum. The hypotympanum is empty and essentially featureless. It is the smallest of the 3 division of the middle ear cavity. The epitympanic recess communicates with the mastoid antrum via the aditus. Korner septum, the remnant of petrosquamous suture, is a thin osseous partition vertically oriented along the sagittal plane eccentrically protruding downward into the mastoid antrum.^[3,4]

Invention of CT by G.N.Hounsfield in 1972 has created remarkable impact upon the practice of neuroradiology. The first CT scanner available for clinical use was designed specifically for the examination of the head. CT has the advantage of producing images with higher contrast and better spatial resolution. Temporal bone is well adapted to High resolution- CT because of its very high inherent contrast.^[5-7]

CT examination has helped in early diagnosis, accurate localisation and planning of treatment. Recent advances like high resolution CT and 3D-CT have revolutionised the role of CT in the study of temporal bone.^[8-10]

The development of external and middle ear is independent of the development of inner ear. Therefore, significant malformation of external and middle ear accompany each other. Inner ear anomalies usually occur independently. External auditory canal stenosis is a common anomaly which can be focal or diffuse narrowing. The trapped epithelial debris in the medial end can give rise to cholesteatoma.^[11-13] Similarly, in atresia of external auditory canal there is a bony plate across the external auditory canal with fusion of the malleus neck to the atretic plate. Clinically, patients born with external auditory canal atresia are seen with deformity of the auricle and no visible external auditory canal. Various other anomalies include- 1st and 2nd Branchial Arch Dysplasia, Inner ear anomalies like Micheal anomalies - Aplasia of labyrinth, Mondini malformation, Vestibular aqueduct anomalies etc.^[14-20]

The aim of the present study is to study the normal anatomical perspective and congenital lesions of temporal bone and to see the accuracy of CT in detecting intra-canalicular space occupying lesion.

MATERIALS AND METHODS

This prospective and observational study was carried out in 32 patients. All the scans were performed on a Wipro GE Prospeed 5x advantage. Patients were scanned in the axial and coronal planes. Axial images are the easiest for the patient positioning since they can be acquired by minor gantry tilt or head angulation in the supine position.

Scout films were taken routinely in all patients before starting the scan. The plane is not strictly speaking true axial but a plane at 30° to the radiographic baseline, which is the orbito-meatal line drawn from the center of external auditory canal meatus to the outer canthus of eye. Scanning commenced from lower margin of external auditory meatus and extended upwards to the arcuate eminence of superior semicircular canal. Slight extension of the head was given to avoid gantry tilt and there by protect the lens from radiation. Coronal images were obtained perpendicular to the axial plane from cochlea to the posterior semicircular canal.

Intravenous contrast was administered to study hypervascular lesions like glomus tumors, Cerebello pontine angle masses and intracranial and extracranial extension of middle ear disease. Usually 3mm thick sections with 3 mm interval or 5mm thick section with 5 mm interval (130 MA, 120KV, scantime 3 sec). In HRCT 1mm thick section with 1 mm interval (60 MA, 80 IN) using bone algorithm and wide window setting around 4000. Accessory parameters: Plain radiograph of temporal bone, hearing tests.

The values were expressed as mean \pm SD. Statistical analysis was done by using Student's paired t-test for

quantitative and Chi-square test for qualitative parameters. The p value of <0.05 was considered as statistically significant.

RESULTS

The age group involving maximum patients with temporal bone abnormalities is 41-50 years and minimum in 71-80 years [Table 1]. The males and females presented with temporal bone lesions mainly in age group of 11-20 yrs and 41-50 yrs respectively [Figure 1].

Table 1: Distribution of temporal bone abnormality according to age.

Age(Years)	Number	Percentage
0-10	2	6.25
11-20	6	18.75
21-30	3	9.37
31-40	6	18.75
41-50	7	21.88
51-60	4	12.50
61-70	3	9.37
71-80	1	3.12

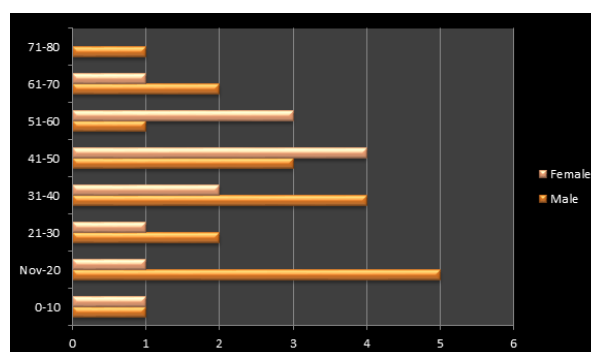


Figure 1: Graphical representation of age and gender distribution of temporal bone abnormalities.

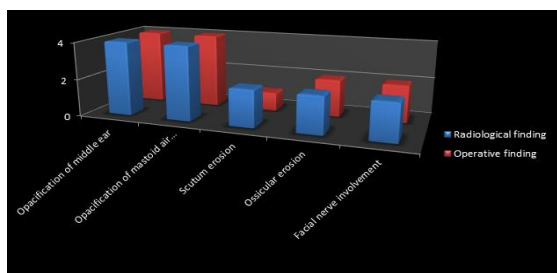
Table 2: Clinical representation of patients with temporal bone abnormality.

Features	No. of cases	Percentage
Hearing loss	18	56.2
Ear discharge	12	37.5
Facial nerve weakness	12	37.5
Head ache	10	31.2
Ear pain	6	18.8
Tinnitus	6	18.8
Cerebellar signs	5	15.6
Diplopia	2	6.2
External ear deformity	2	6.2

[Table 2] depicts that highest number of patients presented with complaint of hearing loss (56.2%) followed by ear discharge (37.5%) and facial weakness (37.5%). Figure 2 and table 3 depicts the comparison between the radiological and intra-operative findings and showed statistically insignificant difference ($p < 0.05$).

Table 3: Comparison of CT findings with operative/biopsy findings of tumor.

Tumors	No. of patients	CT features	Operation findings and biopsy
Acoustic neuroma	5	Left - 4 Right - 1 Hypodense to slightly hyperdense cerebello-pontine angle mass showing contrast enhancement with erosion of porous acousticus	4 patients were operated and CT findings were correlated with operative findings. 1 patient was unwilling for operation biopsy — schwannoma
Facial nerve neuroma	1	Illdefined enhancing, isodense mass lesion in the course of left 7th nerve involving labyrinthine, tympanic and extracranial portion without extension into parotid gland. Bony facial canal is irregularly expanded'	Patient was operated and found to have tumor at specified location and extent. Biopsy — myxoneuroma
Carotid body tumor with metastasis in sternum, D2 vertebrae	1	Destruction of apex of petrus bone with involvement of carotid canal and adjacent clivus with soft tissue component on left side. MR: Isointense lesion in T1 weighted image in the posterior aspect of left parapharyngeal space in the neurovascular bundle region encasing ICA, causing indentation in posterior wall of pharynx. The lesion is hyperintense in T2 weighted image and enhancement on contrast	Advised radiotherapy biopsy; carotid body tumor

**Figure 2: Comparison between CT and operative finding in infections.**

DISCUSSION

Computed tomography is acquiring an increasingly important role in the radiographic assessment of temporal bone. Radiographic assessment of temporal bone is difficult owing to complicated anatomical structure of middle and inner ear.^[15]

This study is undertaken to develop a systematic method for evaluation of temporal bone as there are a variety of other imaging modalities. The lowest radiation dose to the lens, visualization of small bony structures, technical factors, case of patient positioning, interpretation of the images and economic factors were all considered.

HRCT has the advantage of excellent topographic visualization, devoid of artifacts from superimposition of structures. It helps in accurate assessment of pathology prior to surgical exploration regarding location, extent and complication of the disease.^[11,19]

This study showed that there is excellent correlation between CT interpretation and surgical finding in patients with infections of ear. Mafee et al studied cholesteatoma in 48 patients with CT,^[21] preoperatively. Operative reports of these patients were correlated with the CT findings in all the patients. The hallmark of cholesteatoma on CT scans are a soft tissue mass in the attic and mastoid antrum associated with smooth bony expansion, scalloping of the mastoid, erosion of lateral wall of attic and erosion of ossicles. Comparing the imaging changes in the attic with findings at operation, they found agreement between the radiographic interpretation and surgical findings in 90% of cases.

Maffee et al demonstrated in 45 patients with mixed hearing loss that CT is a better modality for appreciating the otosclerosis and to differentiate from other causes of conductive/mixed hearing loss.^[21] 42 CT can determine the extent or degree of pathologic involvement of foot plate of stapes which is not possible by clinical evaluation.

Temporal bone fractures visualized on plain radiograph may not adequately define ossicular disruptions or facial canal abnormalities. To obtain optimal information from temporal bone CT images, we try to have clinical findings. The common serious consequences of trauma to temporal bone are hearing loss and/or facial paralysis.^[10]

Acoustic Neuroma: Out of 13 neoplastic lesions (40%) that were scanned, 5 were diagnosed as acoustic neuroma. Left cerebellopontine angle predominance was noted in our study. All cases were hypodense to isodense to the surrounding brain with dense enhancement on contrast administration and depicted internal auditory meatal erosion. Taylor S,^[5] in his study has reported bony erosion on CT in upto 87% of cases. This 'difference can be seen because we encountered all large sized acoustic neuromas. Acoustic neuroma was the most common internal auditory canal and/or cerebellopontine angle lesion, in a study by Curtin HD.^[19]

Facial nerve neuroma: Facial nerve neuroma constitutes 7% of temporal bone neoplasms. In our study we had one patient, a 33 year old female who presented with facial nerve weakness. CT showed erosion and widening of facial canal. MR demonstrated involvement of labyrinthine and tympanic part of facial nerve without extension to parotid gland. Surgery finding was similar to radiologic image finding.

Joseph T Latak et al studied about facial neuroma in 8 patients with high resolution CT and posterior fossa computed tomography.^[22] Their study showed bone erosion and soft tissue masses conforming to the course of the facial nerve. According to them radiologic imaging frequently permits a correct preoperative diagnosis and accurate definition of the extension of facial nerve neuroma.

CONCLUSION

1. Common clinical features were hearing loss (56.2%), ear discharge (37.5%) and facial nerve weakness (37.5%).
2. Commonest lesion of temporal bone was neoplasm. Female preponderance was noted.
3. In our study the commonest tumor was acoustic neuroma.
4. There was excellent correlation between CT and operative findings in case of infections and tumors.
5. CT is the best method of choice in detection of temporal bone lesion.

REFERENCES

1. Chat Virapongse, Stephen L.G Rothman, E. Leon Keir and Mahammad Sarwar. CT Anatomy of Temporal bone. J. AJR 1982 Oct, 139:739-749.
2. Martha Brogen and Donald W Chakeres: CT and MRI of the normal anatomy of the temporal bone. J. Seminars in USG, CT and MRI. 1989;10(3):178-194.
3. Mahamood F Mafee, Galdino E Valvassori, Glen D Dobben and Chicago IL. CT of temporal bone. J. Laryngoscope 1982, May 92:562-565.
4. Donald W Chakeres and Peter K Spiegel. A systemic technique for comprehensive evaluation of the temporal bone by CT. J. Radiology 1983;146:97-106.
5. Soul Taylor. Petrous temporal bone including CP angle. J RADIOL. CLIN. NORTH AMERICA. March 1982;20(1):67-86.
6. Donald W Chakeres, Jhon E Sunderland, Martha Brogan. Temporal bone in CT and MRI of the whole body (volume I): John R Haago MD, Charles F Lanzieri MD, David 3 Sartoris, MD, and Elias A Zerhouni MD, 3rd edition, 1994 Mosby Chapter 14, pp 428-470.
7. Joel D Swartz. The facial nerve canal. J. Radiology. 1984; 153:443-447.
8. Hough D Curtin MD. Congenital malformation of the ear. J. Otolaryngologic Clinics of North America 1988 May; 21(2):317-335.
9. Elizabeth A Eelkema and Haugh Curtin. Congenital anomalies of the temporal bone. J Seminars in CT, MRI and USG 1989 June;10(3):195-212.
10. Joel D Swartz and Eric N Faerber. Congenital malformation of the external and middle ear HRCT findings of surgical importance. J. AJR 1985;March 144;501-506.
11. Joel W Yeakley and Robert A Jahrsdoerfer. CT evaluation of congenital aural atresia. Journal of computed assisted tomography 1996;20(5):724-731.
12. Marc M Lemmerling, Anthony A Mancuso, Patrick J Antonelli, and Paul S Kubilis. Normal modiolus; CT appearance in patients with a large vestibular aqueduct. J. Radiology 1997;204:213-219.
13. Jerry Stern and Marvin Goldenberg. Jugular bulb diverticula in medial petrous bone. AJR May 1980;959-961.
14. Thomas V Lloyd, Michael Van Anan and Jhon C Jhonson. Aberrant Jugular bulb presenting as a middle ear mass. J Radiology April 1979;131:139-141.
15. Roy A Holiday. Inflammatory disease of the temporal bone. Evaluation with CT and MRI. J. Seminars in CT, MRI and USG. 1989;10(3):213-235.
16. Mahamood F Mafee, Edward L Singleton, Galdino E Valvassori, Gustavo A Espinosa, Arvind Kumar and Kenji Aimi. Otomastoiditis and its complication. J. Radiology 1985;155:391-397.
17. Marc M Lemmerling, Hilda E stambuk, Anthony A Mancuso, Patrick J Antonelli, and Paul S Kubilis. Normal and opacified middle ears. J Radiology 1997;203:251-256.
18. Anton N Hasso and John A Ledington. Imaging of infection by CT. J. Otolaryngologic clinics of North Aericia. 1988 May;21(2):219-223.
19. Hugh D Curtin, Patrick Wolfe and Mark May. Malignant external otitis. CT evaluation. J. Radiology 1982;Nov 145;383-388.
20. Anton N Hasso and John A Ledington. Traumatic injuries of temporal bone. J. Otolaryngologic Clinics of North America 1988 May;21(2):295-315.
21. Mahammad F Mafee, Kenji Aimi, Howard L Kahen, Galdino E Valvassori vlastimil capek. Chronic otomastoiditis. A conceptual understandings of CT findings. J. Radiology 1986;160:193-200.
22. Joseph T. Latak, Trygave O.Gabrielsen, James E. Knake John L Kemink, Malcom D.Graham, Stephen S.Gebarski and Peter J Yang. Facial nerve neuromas. Radiologic evaluation. J. Radiology 1983;149;731-739.

How to cite this article: Menon SV, Padmini S, Vareed SK. Temporal Bone Lesions - An Observational Radiographic Study. Ann. Int. Med. Den. Res. 2017; 3(4):ME33-ME36.

Source of Support: Nil, **Conflict of Interest:** Nil.