

Mirror Image Dextrocardia in a Left Handed Female Presenting With Left Sided Appendicitis.

Gagandeep Singh Shergill¹, Hari JP², N.S Neki³, Amritpal Singh⁴, Alok Verma⁵, Divyanshu Dhamija⁶

¹Junior Resident, Department of Medicine, Govt. Medical College and Guru Nanak Dev Hospital, Amritsar, India.

²Junior Resident, Department of Surgery, Armed Forces Medical College and Hospital (AFMC), Pune, Maharashtra, India.

³Professor of Medicine, Govt. Medical College Amritsar, Punjab, India.

⁴Senior Resident, Dept. of Medicine, Govt. Medical College, Amritsar, Punjab, India.

⁵Junior Resident, Department of Radiodiagnosis, Govt. Medical College and Guru Nanak Dev Hospital, Amritsar, India.

⁶Intern, Department of Medicine, Govt. Medical College and Guru Nanak Dev Hospital, Amritsar, India.

Received: May 2017

Accepted: May 2017

Copyright: © the author(s), publisher. It is an open-access article distributed under the terms of the Creative Commons Attribution Non-Commercial License, which permits unrestricted non-commercial use, distribution, and reproduction in any medium, provided the original work is properly cited.

ABSTRACT

Dextrocardia associated with situs inversus totalis is an uncommon congenital condition in which the organs are located in a symmetric or mirror position on the opposite side of the body. Some diseases, like appendicitis in this case report, can present with unusual characteristics and may pose diagnostic dilemma. This uncommon feature was detected in a left handed, another uncommon variable- hence this interesting case report. Also, the report might open up new areas for research.

Keywords: Dextrocardia; situs inversus totalis; left sided appendicitis; dextrocardia in left handed.

INTRODUCTION

By virtue of abnormal location of heart and other organs; dextrocardia presents with abnormal ECG and atypical presentation of diseases such as angina pectoris, myocardial infarction, acute cholecystitis, acute appendicitis, and diverticulitis- which are good enough to create panic and puzzle in emergency rooms. Dextrocardia has been studied to be associated with splenic abnormalities, congenital cardiac anomalies and Kartagener's syndrome. Handedness has also been widely studied in various spheres of psychology, medicine, anthropology, criminology and economics. But interestingly, their association with each other has not been studied. While dextrocardia can be identified or excluded via a thorough history and physical examination, chest radiography, electrocardiography and echocardiography; the detection of a southpaw takes little efforts.

Name & Address of Corresponding Author

Dr. Gagandeep Singh Shergill,
Flat Number 3, Registrar Flats,
Govt. Medical College & Guru Nanak Dev Hospital,
Amritsar, Punjab, 143001

CASE REPORT

A 22 years old unmarried female presented to surgery emergency with complains of pain in the left

side of abdomen associated with nausea. Our internal medicine team was requested to comment upon the "abnormal ECG" encountered during her routine work up. The patient was experiencing pain in the left iliac fossa, had pulse rate of 126/min and blood pressure was 126/90 mm of mercury. Her apex beat was palpable in the fifth right intercostal space with heart sounds clearly audible on the right side of the thorax. The ECG showed inverted P wave, negative QRS, inverted T wave in lead I, Positive QRS complexes with upright P and T waves in aVR, dominant S waves in leads I and V1 to V6, R wave regression in chest leads V1-V6, low voltage QRS axis in V3 to V6 and Right axis deviation [Figure 1]. When the precordial leads were placed in a mirror-image position on the right side of the chest after reversing the left and right arm leads, the ECG showed normal features [Figure 2].

The provisional diagnosis of dextrocardia with most probably situs inversus and left sided appendicitis was suggested to the surgery team. The findings were later confirmed by ultrasonography of the abdomen and x-ray chest in which aortic knuckle, cardiac apex and gastric bubble were visible on the right side while; hepatic opacity was observed on the left thorax along with slight leftward deviation of trachea [Figure 3]. Similar observations of dextrocardia inversus totalis were made upon computed topography (CT scan) of the abdomen and chest [Figure 4&5]. An interesting point of our

patient being left handed amongst all her family was made. Her general physical along with respiratory and nervous system examination was found to be normal. Except dextrocardia, her cardiovascular examination otherwise was also normal. The patient was the eldest of her 5 siblings- 3 sisters and 2 brothers. All her siblings and her parents were clinically examined and their chest x-rays along with ECGs were taken. None were found to share the abnormality. The patient was operated by the surgery team and was discharged in satisfactory condition with a strong advice to always tell the doctors that “my heart is on the right and the abdominal organs are also in the inter-changed places- please take a note of it!”

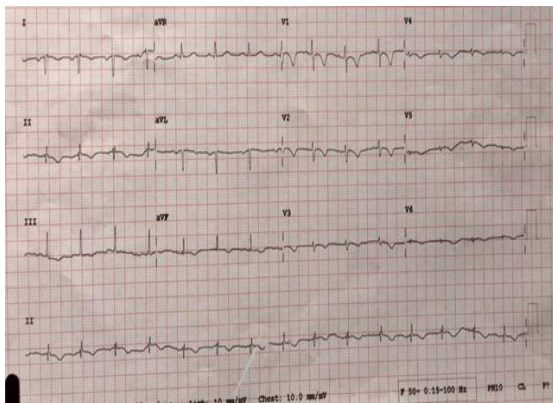


Figure 1: showing ECG with normal or usual lead placement.

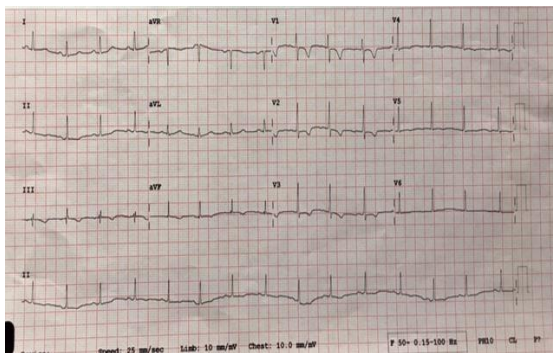


Figure 2: Showing ECG after right sided placement of precordial leads and reversal of arm leads.

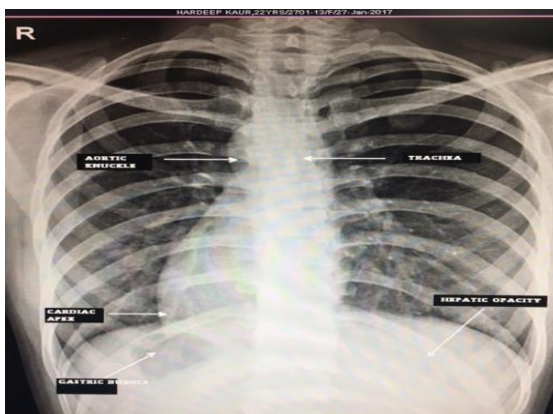


Figure 3: Showing dextrocardia with right sided gastric bubble.

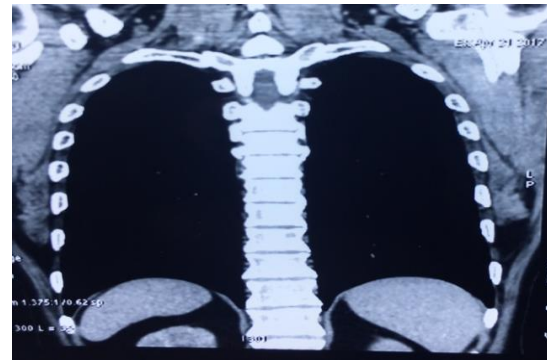


Figure 4: CT scan of the patient showing liver on the left and spleen on the right side of the body.

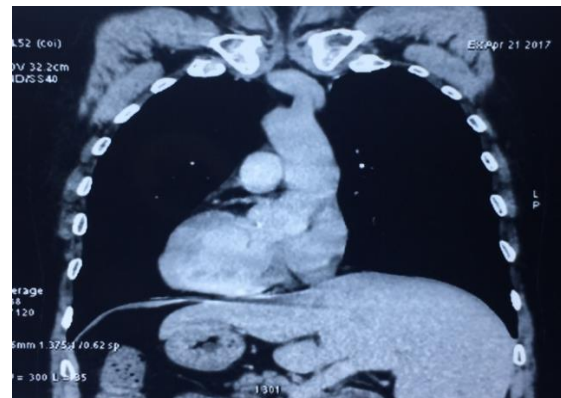


Figure 5: CT scan of the patient showing cardiac apex towards the right side of the thorax and liver on the left side of the abdomen.

DISCUSSION

Normal arrangement of human body is Situs solitus with levocardia. Levocardia, dextrocardia and mesocardia are general terms that indicate the position of only the cardiac apex and do not give any indication of the cardiac structure or abdominal situs. Levocardia indicates that heart is mainly on the left of chest and its apex points to the left. On the other hand, dextrocardia indicates the heart is mainly on the right and its apex points to the right. Midline heart is referred to as mesocardia.

Situs refers to the position of the atria and abdominal viscera relative to the midline. The term has no relation with position of the cardiac apex. Situs solitus means normal arrangement of abdominal organs with stomach and spleen situated on the left, while liver, appendix and duodenum on the right side of the body. In situs inversus, viscera which are normally present on the right side are situated on the left, while viscera normally present on the left are situated on the right side. Isolated dextrocardia usually displays situs solitus, while mirror image dextrocardia has situs inversus. Mirror-image dextrocardia is the most common form of cardiac malposition encountered. In situs ambiguous (situs indeterminatus or heterotaxia), there is abnormal arrangement of the organs and major blood vessels,

which is different from that of situs solitus and situs inversus. The stomach and liver are typically midline, with congenital heart disease occurring in 50%–100% of cases. Major subcategories of situs ambiguous include asplenia and polysplenia. Another form of cardiac malposition is the criss-cross heart which is characterised by abnormal rotation of the ventricular axis.^[1,2]

The extent of right rotation of heart in isolated dextrocardia is less than mirror image dextrocardia. Normal arrangement of the heart, Situs solitus with levocardia, is associated with less than 1% incidence of congenital cardiac diseases. Situs inversus with dextrocardia have a 3%–5% incidence of congenital heart disease and the rare situs inversus with levocardia (incidence of 1:22,000) is almost always associated with severe congenital heart diseases carrying poor prognosis with only 5%–13% of patients surviving for more than five years. Splenic abnormalities like asplenia or polysplenia syndrome are also frequently associated with this type. The common congenital cardiac anomalies associated with different dextrocardias are atrial situs solitus (93%), discordant AV connection (44%), and discordant ventriculo-atrial (VA) connection (30%). The most anomalies were congenital corrected transposition of great arteries (C-TGA) (33%). About 25% of these patients will have associated sinusitis and bronchiectasis (Kartagener's syndrome) as well.^[1,3]

This condition is fairly uncommon: Its true incidence worldwide is not completely known but it is estimated to occur in about 1 in 12,019 pregnancies in the United State of America,^[4] slightly more common in men than in women, although the actual frequency may be higher as it is entirely possible to live a long, normal life without ever knowing one has dextrocardia. Its incidence in Indians is not known. Both autosomal dominant and autosomal recessive patterns of inheritance have been suggested by different researchers.^[5,6]

Thorough physical examination along with chest x-rays, ECG and echocardiography are generally sufficient to diagnose dextrocardia. CT and CMR may be used to gather greater anatomic information of visceral organ position, cardiac apical position, intracardiac anatomy and great vessel branching.^[7] Electrocardiographic features include: inversion of all complexes, aka 'global negativity' (inverted P wave, negative QRS, inverted T wave) in lead I, Positive QRS complexes (with upright P and T waves) in aVR, dominant S waves in leads I and V1 to V6, reversed R wave progression in chest leads, low voltage QRS axis in V4 to V6, Right axis deviation, flattened T waves in V4 to V6 and aVR and inverted T waves in lead I and aVL.^[8]

Early diagnosis of situs inversus totalis is important because the thoracic and abdominal surgical approach is different and certain diseases could be presented with unusual characteristics. The risk in

these patients lies in the atypical presentation of diseases such as angina pectoris, myocardial infarction, acute cholecystitis, acute appendicitis, and diverticulitis where pain is referred to the "wrong" side.^[9,10] Recognizing the presence of dextrocardia will also help avoid unnecessary workup for abnormal ECG. Also, after the diagnosis of situs inversus, the presence of associated pathologies such as primary ciliary dyskinesia can be studied.

The dextrocardiac patients should ideally wear a medical identification tag to warn emergency medical staff that the patient's internal organs are reversed from normal so they can act accordingly. But in a poor country like ours where such things can't be easily done, the patient should be told about the advantages of mentioning her condition whenever he/she is examined by a medical professional. To get this info incorporated into "aadhar card" could prove immense.

Since dextrocardia could run in families, all family members of the patient should be evaluated in order not to miss important diagnosis at the earliest as they may have some severe malformation but may remain asymptomatic for long periods.

An interesting aspect of this case report is of the patient being "left handed". Approximately 10% of the world's population is left-handed.^[11] Annett proposed a genetic model of handedness, stating that handedness is determined by one gene with two alleles. One allele is dominant (RS+) and selects for right-handedness, while the other is recessive (RS-) and selects for both right- and left-handedness. Recessive trait is maintained because of a cognitive advantage for individuals with both alleles (RS+ RS-) relative to left-handers (RS- RS-) and individuals who are very strongly right-handed (RS+ RS+).^[12]

Although, handedness has been widely studied in various domains - ranging from psychology to medicine, anthropology to its relationship between handedness and adult wages,^s yet its association with dextrocardia has not been studied anywhere to the best of our knowledge. Whether this association is just a co-incidence? Could this association, if it happens to exist, be of any significance? A research in this direction may answer these queries! Hence this being a rare case report.

CONCLUSION

Early diagnosis of situs inversus totalis is important because some diseases can have atypical presentation. Also, presence of associated pathologies can be studied. As the condition is genetic, all family members of the patient should be evaluated to clinch important diagnosis of possibly associated serious pathologies at the earliest. The dextrocardiac patients should be encouraged to wear a medical identification tag. The association of

dextrocardia with southpaws should be researched upon and it might lead to interesting discoveries.

REFERENCES

1. Winer-Muram HT, Tonkin IL. The spectrum of heterotaxic syndromes. *Radiol Clin North Am.* 1989;27:1147–70.
2. Swarhib M, Das S, Htwe O. A case of situs inversus totalis: embryological and clinical considerations. *Int Med J.* 2013;20:264–65.
3. Fulcher AS, Turner MA. Abdominal manifestations of situs anomalies in adults. *Radiographics.* 2002;22:1439–56.
4. Bohum CM, Potts JE, Casey BM, Sandor GG. A population-based study of cardiac malformations and outcomes associated with dextrocardia. *Am J Cardiol.* 2007;100(2):305–09.
5. Chib P, Grover DN, Shahi BN. Unusual occurrence of dextrocardia with situs inversus in succeeding generations of a family. *J Med Genet.* 1977;14:30–32
6. Ibrahim A. Familial dextrocardia in a Nigerian Family. *Niger Med J.* 2013;54(4):282-83.
7. Ogunlade O, Ayoka AO, Akomolafe RO, Akinsomisoye OS, Irinoye AI, Ajao A et al. The role of electrocardiogram in the diagnosis of dextrocardia with mirror image atrial arrangement and ventricular position in a young adult Nigerian in Ile-Ife: a case report. *Journal of Medical Case Reports.* 2015; 9: 222.
8. Neki NS, Shergill GS, Singh A, Kaur S, Tyagi P, Singh T. ECG in Dextrocardia. *WJPMR.* 2017;3(3): 219-20.
9. Huang SM, Yao CC, Tsai TP, Hsu GW. Acute appendicitis in situs inversus totalis. *J Am Coll Surg.* 2008;207:954.
10. Seifmanesh H, Jamshidi K, Kordjamshidi A, Delpisheh A, Peyman H, Yasemi M. Acute left-sided appendicitis with situs inversus totalis: a case report. *Am J Emerg Med.* 2010;28:1058.
11. Aggleton JP, Kentridge RW, Good JMM. “Handedness and Musical Ability: A Study of Professional Orchestral Players, Composers, and Choir Members” *Psychology of Music.* 1994;22:148–56.
12. Annett M, Kilshaw D. “Mathematical Ability and Lateral Asymmetry” *Cortex.* 1982;18:547–68.
13. Johnston DW, Nicholls MER, Shah M, Shields MA. Nature’s Experiment? Handedness and Early Childhood Development. *Demography.* 2009;46(2):281-301.

How to cite this article: Shergill GS, Hari JP, Neki NS, Singh A, Verma A, Dhamija D. Mirror Image Dextrocardia in a Left Handed Female Presenting With Left Sided Appendicitis. *Ann. Int. Med. Den. Res.* 2017; 3(4): ME24-ME27.

Source of Support: Nil, **Conflict of Interest:** None declared