

## Disseminated Cysticercosis - A Case Report.

Saruchi Garg<sup>1</sup>, Heena Kathuria<sup>1</sup>, Satish Sachdeva<sup>2</sup>, Tarvinderjit Khurana<sup>3</sup>

<sup>1</sup>Junior Resident, Department of Medicine, GMC, Patiala.

<sup>2</sup>Associate Professor, Department of Medicine, GMC, Patiala.

<sup>3</sup>Senior Resident, Department of Medicine, GMC, Patiala.

Received: October 2016

Accepted: October 2016

**Copyright:** © the author(s), publisher. It is an open-access article distributed under the terms of the Creative Commons Attribution Non-Commercial License, which permits unrestricted non-commercial use, distribution, and reproduction in any medium, provided the original work is properly cited.

### ABSTRACT

Cysticercosis is a common public health problem in the Tropics. One of the uncommon manifestations and a rare complication is its disseminated form (DCC). Here, we report a case of disseminated cysticercosis with history of generalized tonic clonic seizures for 2 years with characteristic MRI findings and biopsy evidence from para vertebral muscles.

**Keywords:** Disseminated Cysticercosis, Generalized tonic clonic seizures.

### INTRODUCTION

Neurocysticercosis (NCC) is one of the seven neglected endemic zoonoses targeted by the World Health Organization. It is considered a common infection of the nervous system and is known to be the primary cause of preventable epilepsy in many developing countries.<sup>[1]</sup> Neurocysticercosis is the most common parasite disease of the central nervous system. However, disseminated cysticercosis is a very rare manifestation of the neurocysticercosis and fewer than 50 cases of disseminated cysticercosis have been reported in the world.<sup>[2]</sup>

This case report describes a rare presentation of disseminated cysticercosis.

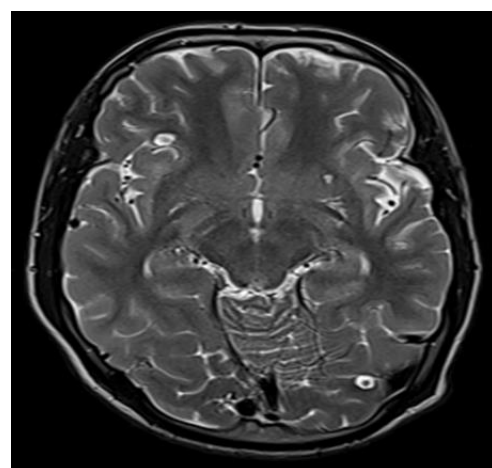
#### **Name & Address of Corresponding Author**

Dr. Satish Sachdeva  
Associate Professor,  
Govt Medical College,  
Patiala, Punjab, India.

### CASE REPORT

A 22 years old male, native of Lucknow, Indian district in Uttar Pradesh migrated to Punjab 8 years back presented in outpatient department with chief complaint of Generalised Tonic Clonic seizures for 2 years. He used to eat cooked mutton, chicken, fish and raw vegetables. There was no history of limb weakness, diplopia, sensory deficits, bladder or bowel disturbances. There was no history of fever or trauma. He was taking anti-epileptic treatment irregularly and was not seizure free for last 2 years. He was taking Carbamazepine 200 tds and Clobazam 10 HS. Last seizure occurred in form of

GTCS 7 days ago presenting in OPD. General examination revealed multiple pea-sized nodules over right forearm, right and left hypochondrium and lower back. The central nervous system examination and fundus examination were normal. Routine blood investigations like Complete hemogram, Renal function tests, Blood sugar level, Urine complete examination were within normal limits. MRI brain revealed multiple round well defined ring enhancing lesions scattered in bilateral cerebral hemispheres, basal ganglia, thalamus and left cerebellar hemisphere and even scalp with features suggestive of Granular nodular and nodular calcified stages of NCC [Figure 1 & 2].



**Figure 1: MRI Brain: Axial T2W: Showing cysticerci in right cerebrum and left cerebellum.**

Multiple similar lesions were noted in the muscles and soft tissues of the neck, Orbit and Tongue muscles [Figure 3 & 4].

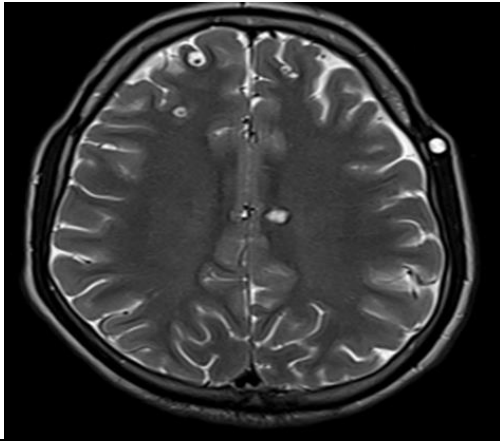


Figure 2: MRI Brain: Axial T2W: Hypertintense signal in scalp.

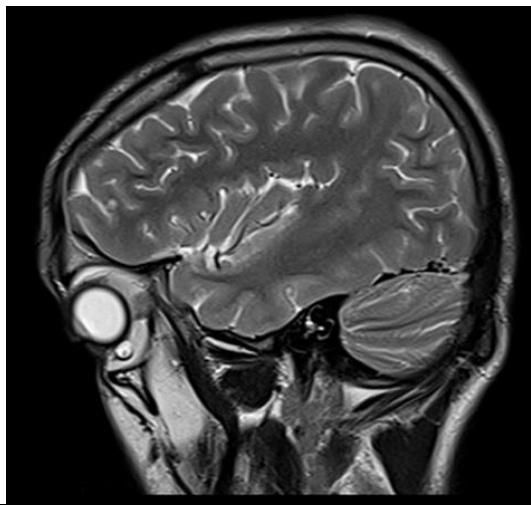


Figure 3: MRI Brain: Saggital T2W: Showing well defined hyperintense signal in orbit with eccentric hypointense signal.

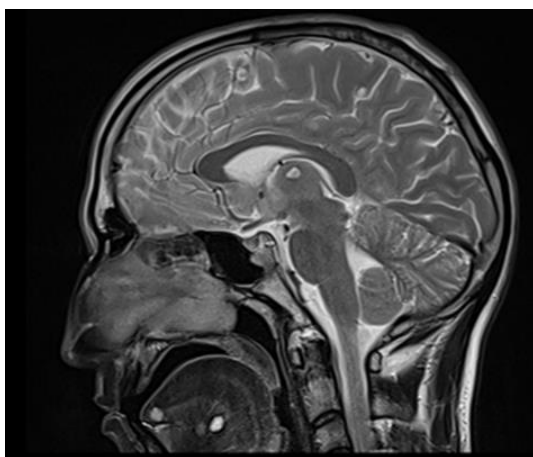


Figure 4: MRI Sagittal T2WI through the upper cervical region: High signal oblong shaped cystic lesions in the extrinsic muscles of the tongue.

MRI screening of whole spine was done and found similar lesions [Figure 5].

X ray AP and Lateral view of bilateral forearms were unremarkable. Excision biopsy from Right lower paravertebral muscle was taken. It measured approximately 0.8 cm and revealed findings of cysticercosiscellulosae. Patient was put on treatment in form of Prednisolone 60 mg for 5 days and Albendazole 400 mg BD for 28 days along with anti-epileptics. Patient is under treatment and on Follow up and is seizure free.

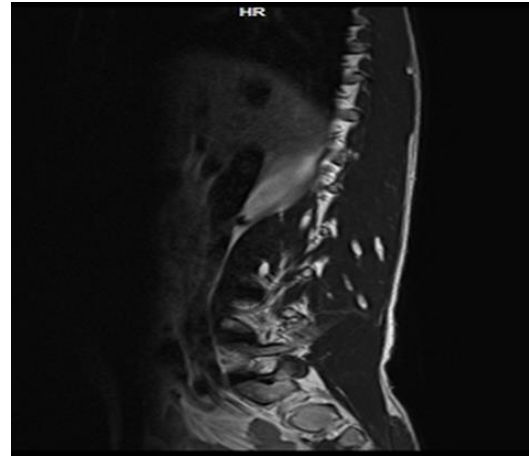


Figure 5: MRI Spinal Cord: Saggital T2W: showing hyperintense signals in paraspinal muscles suggestive of cysticerci.

## DISCUSSION

Cysticercosis is a common tropical disease. Disseminated cysticercosis (DCC) is an uncommon manifestation of a common disease.<sup>[3]</sup> Widespread dissemination of cysticerci throughout the human body was reported as early as 1912 by British Army medical officers stationed in India.<sup>[2]</sup> Priest in 1926, describes a British soldier patient presenting an inflammation of the skeletal muscles, seizures, mental dulling and a large amount of subcutaneous nodules distributed throughout the body.<sup>[4]</sup> An intensive search performed in 1988 revealed 22 cases and only 16 additional cases were reported until 2006 reported in the international medical literature most of than from India. Cysticercus cellulosae are the larval forms of the tapeworm *Taeniasolium*. The adult tapeworms are found in the small intestine of humans, the definitive host, and the larval forms are found in the skeletal muscle of the intermediate host, the pig. To develop cysticercosis, a human has to replace the pig in the *T. solium* life cycle and the eggs must mature within the human small intestine as they would do in the pig's intestine. Entry of the eggs into the human small intestine may occur through autoinfection or by ingestion or inhalation of egg-contaminated food or water. Finally these cysticerci spread through the intestinal wall and are carried by the blood stream to muscles, brain and subcutaneous tissues, leading to clinical manifestations.<sup>[3]</sup>The usual organs involved

are subcutaneous tissue, skeletal muscles, lungs, brain, eyes, liver and heart.<sup>[2]</sup> The pathogenesis and clinical manifestations vary with the site of infection and accompanying host response.<sup>[5]</sup> Symptomatic disease results almost exclusively from the invasion of the nervous system (neurocysticercosis) and the eye and is clearly different than parenchymal neurocysticercosis and extraparenchymal neurocysticercosis. The usual presentation of parenchymal neurocysticercosis is with seizures, which can be controlled with antiepileptic drug therapy. Occasionally, the cysts may grow and produce a mass effect. Extraparenchymal infection may cause hydrocephalus by mechanical obstruction of the ventricles or the basal cisterns, either by the cysts themselves or by an inflammatory reaction (ependymitis and/or arachnoiditis). The so-called racemose variety occurs in the ventricles or basal cisterns and is characterized by abnormal growth of cystic membranes with degeneration of the parasite's head (scolex). These cases follow a progressive course, and even after ventricular shunting, the membranes or inflammatory cells and proteins frequently block the shunt.<sup>[6]</sup> The main features of disseminated cysticercosis include intractable epilepsy, dementia, enlargement of muscles, subcutaneous and lingual nodules and a relative absence of focal neurological signs or obviously raised intracranial pressure, at least until late in the disease.<sup>[2]</sup> Clinical presentations of our patient was generalized tonic-clonic seizures and multiple pea sized subcutaneous nodules were found on general physical examination. There were no visual disturbance, muscle hypertrophy with tenderness. Computed tomography scans and magnetic resonance imaging (MRI) are useful in anatomical localization of the cysts. An MRI is more sensitive than a CT, as it identifies scolex and live cysts in cisternal spaces and ventricles and identifies the response to treatment. Unenhanced CT scans of the muscles can show innumerable cysts standing out clearly against the background of the muscle mass in which they are embedded; the CT image appears like a honeycomb or leopard spots. The radiological findings of cysticercosis – a cystic lesion with a central nodule that represents the scolex – are very similar in all affected organs. On MRI, cysticercosis lesions appear hyperintense, with well-defined edges, which show a hypointense eccentric nodule within, representing the dead parasite's head, which is called the scolex. The presence of a scolex in a cystic lesion usually suggests the diagnosis of cysticercosis.<sup>[7]</sup> Management of DCC includes symptomatic treatment of central nervous system lesions using steroids and antiepileptics. In patients with raised intracranial tension, surgical removal of cysts and ventriculoperitoneal shunting can alleviate symptoms. Pharmacological management with the cysticidal drugs praziquantel and albendazole is indicated as they help by reducing the parasite

burden. These drugs hasten the death of the cysts, which may occur even in the absence of such treatment. Pharmacological treatment may be associated with severe reactions, which may result from enlargement of cysts, massive release of antigens causing local tissue swelling and generalized anaphylactic reaction. Priming with corticosteroids before starting the cysticidal drug decreases the incidence of such complications.<sup>[3]</sup>

## CONCLUSION

Disseminated cysticercosis is a very rare infectious disease. It is important to recognise disseminated cysticercosis clinically and to perform appropriate radiological investigations, because this condition requires an appropriate therapy. Patients who have not undergone treatment and who have active cysts remain at a risk of serious complications.

## REFERENCES

1. Rizvi SA, Saleh AM, Frimpong H, Al Mohiy HM, Ahmed J, Edwards RD, Ahmed SS. Neurocysticercosis: A case report and brief review. *Asian Pac J Trop Med.* 2016;9(1):100-2.
2. Park SY, Kong MH, Kim JH, Song KY. Disseminated cysticercosis. *J Korean Neurosurg Soc.* 2011 Mar;49(3):190-3
3. Bhalla A, Sood A, Sachdev A, Varma V. Disseminated cysticercosis: a case report and review of the literature. *J Med Case Rep.* 2008;30:137.
4. Wadia N, Desai S, Bhatt M. Disseminated cysticercosis. New observations, including CT scan findings and experience with treatment by praziquantel. *Brain.* 1988;111 ( Pt 3):597-614.
5. White AC Jr. Neurocysticercosis: updates on epidemiology, pathogenesis, diagnosis, and management. *Annu Rev Med.* 2000;51:187-206.
6. Garcia HH, Evans CA, Nash TE, Takayanagui OM, White AC Jr, Botero D, Rajshekhar V, Tsang VC, Schantz PM, Allan JC, Flisser A, Correa D, Sarti E, Friedland JS, Martinez SM, Gonzalez AE, Gilman RH, Del Brutto OH. Current consensus guidelines for treatment of neurocysticercosis. *Clin Microbiol Rev.* 2002;15(4):747-56.
7. Bothale KA, Mahore SD, Maimoon SA. A rare case of disseminated cysticercosis. *Trop Parasitol.* 2012;2(2):138-41.

**How to cite this article:** Garg S, Kathuria H, Sachdeva S, Khurana T. Disseminated Cysticercosis - A Case Report. *Ann. Int. Med. Den. Res.* 2017; 3(1):ME01-ME03.

**Source of Support:** Nil, **Conflict of Interest:** None declared