

# Observation of Anterior Ethmoidal Artery in Coronal CT Scans of Paranasal Sinuses in Patients Attending Katihar Medical College, Katihar.

Faulad Md Noori<sup>1</sup>, Md Akbar Ali<sup>2</sup>, Rizwan Karim<sup>3</sup>, Sanjay Kumar Mandal<sup>4</sup>, Saif Omar<sup>5</sup>, Md Gajanphar Ali<sup>6</sup>

<sup>1,2</sup>Asst. Prof., Department of ENT, Katihar Medical College, Katihar.

<sup>3</sup>Associate Professor, Department of Radiodiagnosis, Katihar Medical College, Katihar.

<sup>4</sup>1<sup>ST</sup> YR PGT, Department of ENT, Katihar Medical College, Katihar.

<sup>5</sup>Associate Professor, Department of Anatomy, Katihar Medical College, Katihar.

<sup>6</sup>Senior Resident, Department of ENT, Katihar Medical College, Katihar.

Received: January 2017

Accepted: January 2017

**Copyright:** © the author(s), publisher. It is an open-access article distributed under the terms of the Creative Commons Attribution Non-Commercial License, which permits unrestricted non-commercial use, distribution, and reproduction in any medium, provided the original work is properly cited.

## ABSTRACT

**Background:** Anterior ethmoidal artery is a very important artery particularly useful in frontal and ethmoid sinus surgery. **Aims and objective:** Identification of landmarks of AEA in the medial wall of orbit and in the lateral wall of olfactory fossae and its relationship with the presence of supraorbital cell. **Methods:** Retrospective study was performed in 145 direct coronal CT scan of paranasal sinus from January to November 2016. **Results:** Anterior ethmoidal foramen was present in almost all scan (98%). The AEA canal was present in 33% (49 scan). Supraorbital pneumatization was present in 28% (41 scan). **Conclusion:** Anterior ethmoidal foramen was present in almost all coronal CT scan of PNS. There was strong relationship between presence of supraorbital cell and AEA canal appearance.

**Keywords:** Anterior ethmoidal artery, CT scan, supraorbital pneumatization.

## INTRODUCTION

The anterior ethmoidal artery is a branch of ophthalmic artery traverse from orbit, and through the roof of nasal cavity to the anterior cranial fossa. In the nasal cavity AEA lies usually in a bony canal called anterior ethmoidal canal leaves orbit through anterior ethmoidal foramen.<sup>[1]</sup> The artery runs through the roof of ethmoid in posterolateral to inferomedial direction and then it penetrates the junction between cribriform plate and lateral lamella of olfactory cleft, this region is most fragile and prone to injury causing CSF leak<sup>[2]</sup>. Within olfactory cleft it gives off meningeal branches and again it descend in to nasal cavity where it supply anterior third of nasal septum and lateral wall of nasal cavity.<sup>[3]</sup>

### Name & Address of Corresponding Author

Dr. Md Akbar Ali  
Asst. Prof.,  
Department of ENT,  
Katihar Medical College,  
Katihar.

According to stammberger et al the location of anterior ethmoidal artery lies 1-2mm posterior to the

anterior wall of bulla ethmoidal is at the highest point.

Whereas lund et al postulates that posterior wall of frontal recess is the reference point.<sup>[4]</sup>

AEA is an important anatomical point of reference to locate the anterior skull base and frontal sinus.<sup>[5]</sup> An unwanted damage to this artery during surgery may cause serious complication such as severe bleeding, csf leak, artery retraction in to orbit resulting in orbital haematoma, blindness, cerebral infection.

Gotwald et al used coronal scan to analyse the anatomical landmarks for locating AEA and he found that notch in medial wall of orbit (anterior ethmoidal foramen) and focal funneling in the olfactory fossa ( anterior ethmoidal groove ) were landmark for identification of the position and orientation of AEA in nasal cavity.<sup>[6]</sup>

## MATERIALS AND METHOD

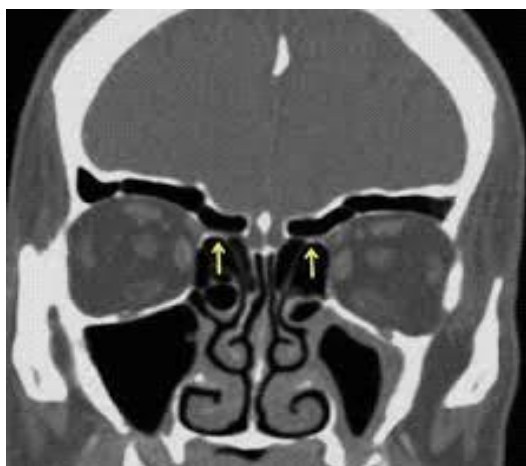
Retrospective study was done in 145 CT of PNS from January 2016 to November 2016 in Katihar Medical College and Hospital. Research ethical committee of the institution has approved the project. Exclusion criteria were age below 14 yrs, any type of history of surgery done of paranasal

sinus or any trauma in paranasal sinus or skull base, any malignant lesion of PNS and or involving head and neck region or any congenital anomalies of the face.

Computed tomography was done using a 16 slice CT SCANNER. Images were taken from anterior wall of frontal sinus to the anterior border of clivus. Only the coronal images were used for study purpose. Position of the patient was ventral decubitus. Slice thickness of 3mm was used for study. Window setting was done at 2500/ 400HU.

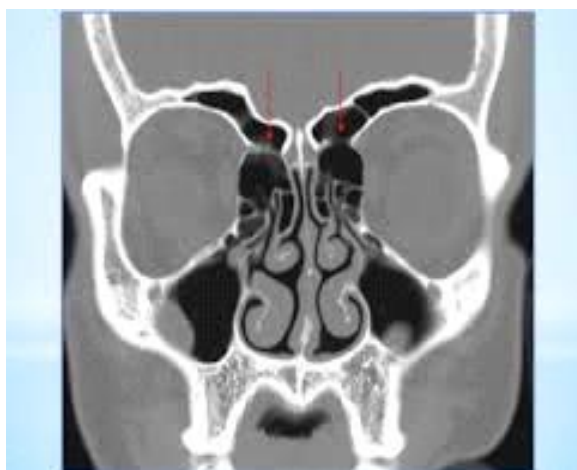AEA location was done by using different landmarks.

Anterior ethmoidal foramen which is present in the medial wall of orbit [Figure 1].



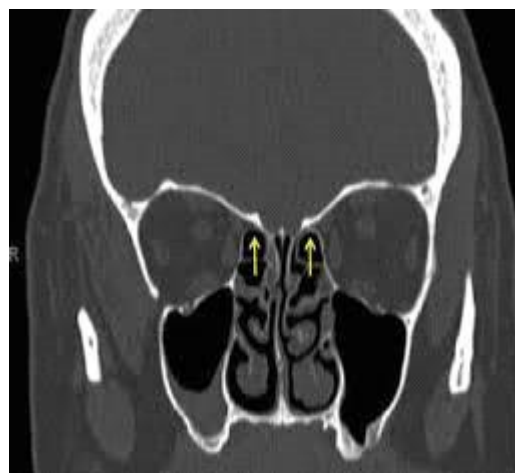**Figure 1: Anterior ethmoidal foramen at the medial wall of orbit.**

Supraorbital pneumatization—This is the pneumatization of orbital roof by ethmoid air cells which lies posterolaterally to frontal recess. [Figure 2]



**Figure 2: Supraorbital pneumatization.**

Presence of anterior ethmoidal artery canal which can be seen fully or partially [Figure 3]



**Figure 3: Presence of anterior ethmoidal artery canal.**

## RESULT

In our present study of 145 patient, number of male patient was 93(64%) where as number of female patient was 52(36%) [Table 1]. Age of patient was from 14 yrs to 80yrs. Anterior ethmoidal artery canal was seen in 33% (49) scan. Most of those were complete type. Anterior ethmoidal foramen was seen in 98% of CT scan. Supraorbital pneumatization was seen in 28% (41) scan [Table 2].

**Table 1: Incidence of sex distribution**

Male	93 (64 %)
Female	52(36 %)

**Table 2: Incidence of different landmarks**

Anterior ethmoidal artery canal	33%(49) scan
Anterior ethmoidal foramen	98%
supraorbital pneumatization	28% (41)

## DISCUSSION

Anterior ethmoidal artery is very important artery in functional endoscopic sinus surgery. It is a very good anatomical landmark in frontal sinus surgery and anterior ethmoid surgery.<sup>[7,8]</sup> The position of anterior ethmoidal artery is an important landmarks as it is considered high risk area in endoscopic sinus surgery.<sup>[9]</sup> 2-3mm behind the bulla ,the anterior ethmoidal artery is seen as a classical breaking of the medial orbital wall . The artery may lies close to skull base or may cross low within anterior ethmoid in which case the orbitocranial canal with its bony mesentery is clearly seen.<sup>[10]</sup> The anterior ethmoidal artery appears to lie low along the base of skull when that region of skull is pneumatized by supraorbital cell. In such case, the artery has a bony mesentery attaching it to the base of skull or it may even be dehiscence<sup>[11]</sup>. Injury to this artery may leads to catastrophic complication that depends upon the site of injury. If injury happens near the orbital region

then in some cases it may retract in to orbit and leads to orbital haematoma. If it is not managed urgently then optic nerve compression can occur which finally cause blindness. Intraorbital haemorrhage is one of the most serious complications that can occur during endoscopic sinus surgery. It has a high potential to cause visual loss.<sup>[12]</sup> If damage happens near to cribriform plate then the chances of CSF rhinorrhoea will be much more. So in nutshell the localization of anterior ethmoidal artery is important preoperatively to reduce the chances of injury during surgery.

Nowadays CT scan is widely used to localize the anterior ethmoidal artery especially coronal section computed tomography is a reliable and informative part of the preoperative evaluation. A screening coronal sinus ct (5mm) images delineates the extent of disease and relevant anatomy.<sup>[13]</sup> CT for evaluation of chronic sinus disease are best scanned 4-6 wks after medical therapy and not during an acute infection.<sup>[14]</sup> Identifying and avoiding dissection on the vessels can reduce the risk of bleeding and orbital haematoma, decrease the chance of skull base injury with csf leak and aid in the identification and dissection of frontal recess.<sup>[15]</sup> While the screening sinus ct provides a cost efficient evaluation of important bony anatomy, a 3-dimensional high resolution ct such as those used for computerized guidance during surgery may provide additional information in significant detail.<sup>[16]</sup>

In our study we found that notch on the medial wall of the orbit so called anterior ethmoidal foramen, was a very good landmark in coronal section CT PNS to locate AEA. Anterior ethmoidal foramen was found in 98% of scan. Gotwald et al assessed 40 coronal plane ct exams using same technique and he found in 95% of ct exam.<sup>[6]</sup> Macdonald et al analyzed 50 ct exams in coronal plane and he also found anterior ethmoidal foramen in 95% of cases.<sup>[17]</sup>

In our study we have found anterior ethmoidal artery canal in 33% of cases. Basak et al who studied the location of anterior ethmoidal artery relative to skull base in 43% of cases.<sup>[18]</sup> Gotwald et al has found orientation of the course of anterior ethmoidal artery in 79% of cases.

In our study supraorbital pneumatization was seen in 28% of cases. There was a strong correlation ship between presence of supraorbital pneumatization and visualization of anterior ethmoidal artery canal. And in all cases where supraorbital pneumatization was present artery were lying freely in mesentery away from ethmoidal roof. In such cases great measure or precaution should be taken to avoid anterior ethmoidal artery injury during surgery.

## CONCLUSION

It was concluded that notch which was present in the medial wall of orbit was a very good landmark to

locate anterior ethmoidal artery and it was found in 98% of cases and in 28% of CT scan supraorbital pneumatization was found which has a very close relationship with visualization of anterior ethmoidal artery canal.

## REFERENCES

1. Moon hyoung -jin, hyung -ung, kim Surgical anatomy of anterior ethmoidal canal in ethmoidal roof. Laryngoscope. 2001; 111:900-4.
2. Stammberger H. functional endoscopic sinus surgery: The messerklinger technique st. louis mo: mosby year book 1991; p70-6
3. Ohnshit-yangisawa. Endoscopic anatomy of anterior ethmoidal artery, Ear Nose and Throat Journal. 1994;634-6.
4. Lund .vj. Anatomy of nose and paranasal sinus, in glesson M, ed. Scott Brown otolaryngology, 6<sup>th</sup> edition London: Butterworth, 1996.
5. Lee WC, KU PKM, Hasselt ca. New guidelines for endoscopic localization of anterior ethmoidal artery: A cadaveric study. Laryngoscope. 200; 110 :1173-8.
6. Gotwald TF, Menzler A Beauchamp NJ, Zur nedden D Zinreich SJ. Paranasal and orbital anatomy revisited: Identification of ethmoid arteries on coronal CT scan crit rev compt tomog, 2003; 44(5): 263-78.
7. S Lee WT, Kuhn FA, CITARD mj. 3D Computed tomographic analysis of frontal recess anatomy in patient without frontal sinusitis. Otolaryngol Head Neck Surg. 2004; 131:164-73.
8. Wormald, PJ. Surgery of frontal recess and frontal sinus Rhinology. 2005; 43(2): 82-5.
9. Dipak ranjan nayak, Produl Hazarika (manual of endoscopic sinus surgery) 2<sup>nd</sup> edn. 2013 p. 54.
10. Renuka Bradoo (Anatomical Principal of endoscopic sinus surgery ;a step by step approach) 1<sup>st</sup> ed reprint. 2016: p.78.
11. Milind V Kirtane (endoscopic endonasal surgery; sinuses and beyond), 1st ed 2015: p.09.
12. Kalusker sk, S Sachdeva. Complication in endoscopic sinus surgery 1<sup>st</sup> ed p 73(5).
13. Kaluskar S.K., Patil Sharkey A.N. Role of CT in functional endoscopic sinus surgery. Rhinology. 1993; 31:49-52.
14. Kennedy Bolger zinreich. Disease of the sinuses diagnosis and management p.134.
15. Kennedy Bolger zinreich. Disease of the sinuses diagnosis and management p.10
16. Tabae A Kacker Kassenoff TL, Anand V 9 outcome of computer assisted sinus surgery: a 5 yr study. Am. J Rhinology. 2003;17:291-7.
17. Mcdonald SF, Robinson PJ, Nuez DA. Radiological anatomy of the anterior ethmoidal artery for functional endoscopic sinus surgery. J Laryngology otology. 2007;7:1-4.
18. Basak S, akdilli A, karaman cz kunt. Assessment of some important anatomical variation and dangerous areas of the paranasal sinuses by computed tomography in children. Int Journal Paediatric Otolaryngol. 2008; 29:55 (2):81-9.

**How to cite this article:** Noori FM, Ali MA, Karim R, Mandal SK, Omar S, Ali MG. Observation of Anterior Ethmoidal Artery in Coronal CT Scans of Paranasal Sinuses in Patients Attending Katihar Medical College, Katihar. Ann. Int. Med. Den. Res. 2017; 3(2):EN04-EN06.

**Source of Support:** Nil, **Conflict of Interest:** None declared