

Giant Poroid Submental Hidradenocarcinoma: Radiological Evaluation – Case Report.

B B Sharma¹, Shweta Sharma², Naveen Bhardwaj³, Mir Rizwan Aziz⁴, Sakshi Dewan³, Nitish Virmani⁵

¹Professor & HOD, Dept.of Radio-diagnosis, SGT Medical College Budhera (Gurgaon).

²Senior Resident, Dept.of ENT & Head and Neck Surgery ,SGT Medical College Budhera (Gurgaon) 122505.

³Assistant Professor. Dept.of Radio-diagnosis,SGT Medical College Budhera (Gurgaon).

⁴Senior Resident, Dept.of Radio-diagnosis,SGT Medical College Budhera (Gurgaon) 122505.

⁵Lecturer.Faculty of Allied Health Sciences, SGT University,Gurgaon (Haryana).

Received: February 2017

Accepted: February 2017

Copyright: © the author(s), publisher. It is an open-access article distributed under the terms of the Creative Commons Attribution Non-Commercial License, which permits unrestricted non-commercial use, distribution, and reproduction in any medium, provided the original work is properly cited.

ABSTRACT

Hidradenocarcinomas are rare tumors of the sweat gland origin and can be of great aggressiveness. These become important entity as these have got high rate of recurrence, metastasis and the management is not encouraging. There may be pre existing adenoma from which these tumors develop without producing any alarming symptomatology. The causative factor is still unknown. We present 54-years old male who presented with huge submental swelling without much of the complaints except cosmetically and that of huge mass. The patient was subjected to cross sectional imaging by contrast enhanced computerized tomography (CECT) and contrast enhanced magnetic resonance imaging (CEMRI). The diagnosis remained inconclusive before surgery. The patient underwent total surgical excision and histopathologically was diagnosed as hidradenocarcinoma.

Keywords: Hidradenocarcinoma, Sweat gland, US, CECT, CEMRI.

INTRODUCTION

Eccrine rich sweat gland tumors are seen in the location of axilla, palm and sole but the neck region is a very rare place for the occurrence. The incidence from dermpathology is 1 in 13000 specimens. There is no sex predilection for the entity and occurs in almost all races equally.

Name & Address of Corresponding Author

Dr. B B Sharma
C - 35 First Floor,
Anand Niketan,
New Delhi.
110021.

CASE REPORT

54-years old male reported to the ENT outpatient department with the history of swelling in submental region for the last fifteen years. The swelling had increased in size with the passage of the time. Now this had caused some cosmetic problem along with some uneasiness in the neck region [Figure 1].

There was no family history of any such types of swellings. On examination the patient was of average built without any history of systemic disease. Locally the swelling was 23 x 19 cm of size.

This was multinodular with cauliflower appearance and hard to feel. There was no superficial ulceration but slight deep pigmentation was noticed. It was non tender without any fluctuations. Plain x-ray of the neck had revealed a huge mass in the neck region with slight compression of the underlying structures [Figure 2].

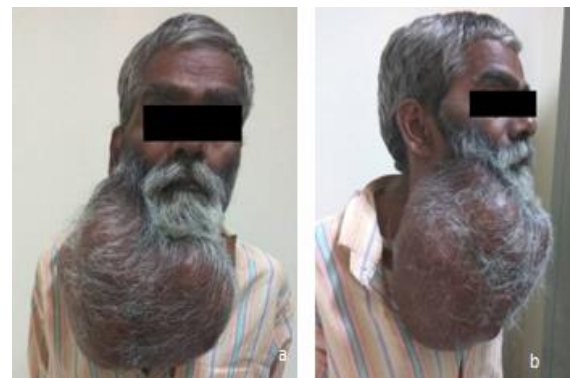

Figure 1: 54-years old male with submental swelling. (a) front view (b) side view.

Patient was subjected to non contrast computerized tomography (NCCT) of the neck region. This revealed the large mass of mixed density without any evidence of calcification. There was no

destruction of the underlying bone and other structures [Figure 3a, b].

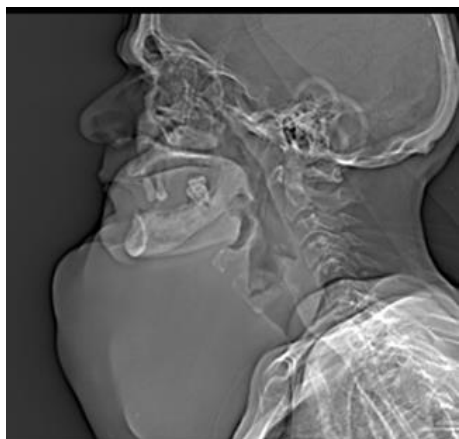


Figure 2: Cervical region lateral view. There is a soft tissue mass in front of the neck region below the mandible region. There is no evidence of any calcification seen in the region. The tracheal shadow underneath is not compressed.

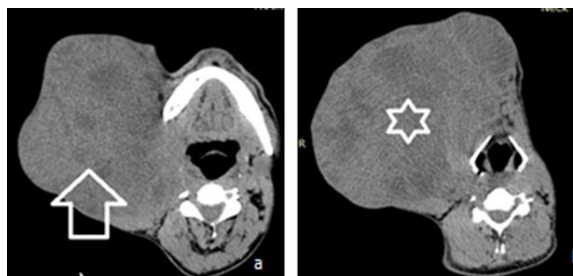


Figure 3: Axial sections of NCCT of the neck region. (a) Soft tissue mass seen predominantly on right side in the upper neck region (white arrow). There are a few regions of hypo densities depicting necrosis within the mass but no calcification seen. (b) at slightly lower part

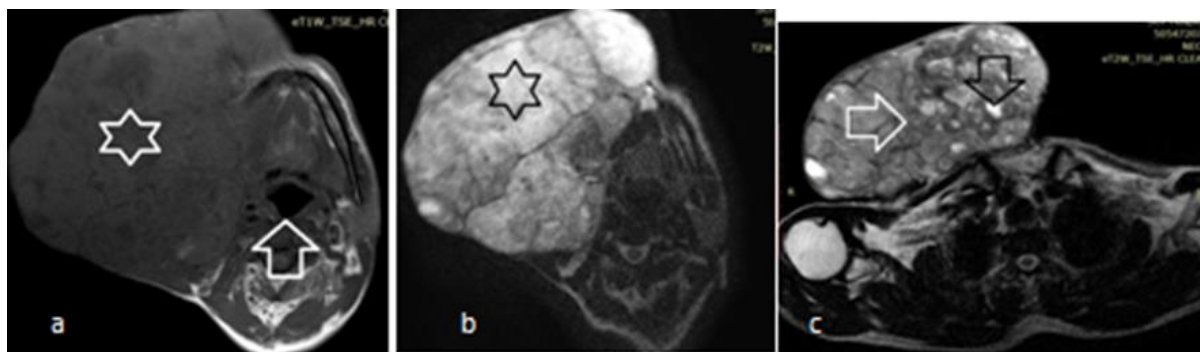


Figure 5: Magnetic resonance imaging axial sections of the mass. (a) T1WI shows the mass as hypointense with well defined margins (white star) (b) T2WI in the upper part shows hyper intensities with intervening hypo intense septation causing lobulations (black star) (c) T2WI at the lower part shows the same mass (white arrow) with a few cystic components (black inverted arrow).

DISCUSSION

Poroid hidradenocarcinomas arise either de novo or from the already existing benign counterpart.^[1] In our case also the history was very long and likelihood of earlier benign tumor was very high. The size can be very big and this also indicates the

the same mass is extending towards the midline with increase in size (white star).

Contrast enhanced computerized tomography (CECT) revealed neck mass with patchy enhancement and areas of necrosis [Figure 4a, b]. Patient was subjected to MRI study also which had shown the tissue characterization. The mass was hypointense on T1W and as that of mixed intensity in T2W sequences. There were also a few cystic areas noticed within the mass ([Figure 5a, b and c]. Fine needle aspiration cytology confirmed the diagnosis as poroid hidradenocarcinomas. The patient underwent complete wide excision of the mass without any complications. The diagnosis was also confirmed on histopathological specimen examination. Microscopic examination revealed vacuolated cells with clear cytoplasm because of high glycogen content. Follow up after a month was uneventful. Three monthly follow up had been planned.

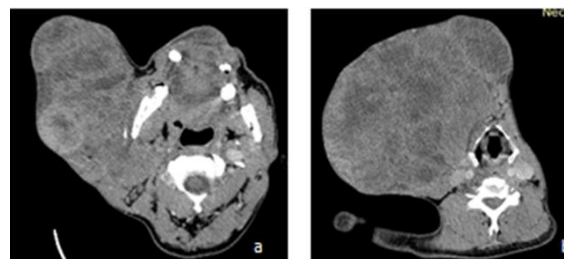


Figure 4: Axial sections of CECT of the neck mass. (a) upper part of the mass shows patchy enhancement with a few areas of necrotic regions. (b) lower neck region also shows similar enhancement pattern with perseveration of soft tissue planes.

aggressiveness of the tumor.^[2] These can present with some complication like acute cardiac failure.^[3] These tumors require differentiation from metastatic and other malignancies like squamous cell and basal cell carcinomas.^[4] Hemangiomas and lymphangiomas can also present in similar fashion. Recurrence rate is 10-70% and are more prone to

metastasis. Cross sectional imaging modalities like CECT and MRI plays a great role in delineation of the lesion. The lesion is of iso to hypodense in nature in plain scan and shows patchy post contrast enhancement. This also picks up the involvement and enlargement of the local nodes. On MRI study the lesion is hypointense on T1W sequences and slightly hyperintense on T2W sequences. This also reveals the cystic component of the mass. There is again patchy enhancement seen in post contrast study. PET/CT is advised to see any metastatic disease but many times fail to locate the lymph node deposits. Management is total excision of the mass depending upon the extent of the tumor. Radiation or chemotherapy is not required. As the recurrence rate is high so three monthly follow up is required Mohs micrographic surgery may also be the best option for the clear margins.^[5,6] Firstly these tumors were labeled as clear cell papillary carcinomas and there was great diagnostic challenge. This is of poorly circumscribed growth in nature. Five years survival rate is less than 30% of the cases.

CONCLUSION

Swelling in the upper part of the neck is usually considered as one from the adjoining salivary glands, thyroid or other soft tissue components.. In our case the mass seems to be from one of these mentioned sites but histopathology turned out to be that of hidradenocarcinoma of sweat gland. These masses pose a great challenge for the physicians because of their asymptomatic nature for a long duration. Cross sectional modalities ruled out tumor of thyroid or salivary gland origin but it was very difficult to rule out the origin from eccrine sweat gland. The final stay lies on the histopathological examination to see the nature and origin of the mass.

Thorough work up is required for deciding the management protocol.

Acknowledgement

We are thankful to Mrs Shilpa Singh, Mr Rajdeep, Miss Nikita Khanna and Raushan for carrying out all the radiological investigations and helping in preparation of the manuscript.

REFERENCES

1. Mlika M,Chelly B,Ayadi-Kaddour A,Boudaya S,Kilani T,Mezni FE,Poroid hidradenoma:A case report .Our Dermatol Online.2012;3:43-5.
2. Lim SC, Lee MJ, Lee MS, et al. Giant hidradenocarcinomas: a report of malignant transformation from nodular hidradenoma. *Pathol Int*, 1998;48(10):818-823.
3. Khalil HMB, Yusuf H, Kaddour HS. Malignant Eccrine idradenoma of neck causing acute heart failure. *Auris, Nasus, Larynx* 2003;30(3):307-310.
4. Nazarian RM, Kapur P, Rakheja D, Piris A, Duncan LM, Mihm MC, et al. Atypical and malignant hidradenomas: A histological and immunohistochemical study. *Modern Pathol*. 2009;22:600-10.
5. Smeets NW, Krekels GA, Osterfag JU, et al. Surgical excision vs Moh's micrographic surgery for basal-cell carcinoma of the face: randomized controlled trial. *Lancet* 2004;364(9447):1766-72.
6. Wildermore JK, Lee JB, Humphreys TR. Mohs surgery for malignant Eccrine neoplasms, *Dermatologic Surgery: Official Publication for American Society for Dermatologic Surgery* 2004;30:1574-1579.

How to cite this article: Sharma BB, Sharma S, Bhardwaj N, Aziz MR, Dewan S, Virmani N. Giant Poroid Submental Hidradenocarcinoma: Radiological Evaluation – Case Report. *Ann. Int. Med. Den. Res.* 2017; 3(2):EN01-EN03.

Source of Support: Nil, **Conflict of Interest:** None declared