

Innovating Functional Chew In Method To Establish Balanced Occlusion In Complete Denture – A Case Report.

Kumar L¹, Khurshid A Mattoo²

¹Assistant professor, Faculty of dental sciences, KGMC University, India

²Assistant Professor, Department of Prosthodontics, College of dentistry, Jazan University, (KSA)

Received: September 2017

Accepted: September 2017

Copyright: © the author(s), publisher. It is an open-access article distributed under the terms of the Creative Commons Attribution Non-Commercial License, which permits unrestricted non-commercial use, distribution, and reproduction in any medium, provided the original work is properly cited.

ABSTRACT

Creating a balanced occlusion in complete denture prosthesis has always been an area where many have developed their own technique to achieve the desired results. Most of such innovations are based on sound principles that work within the mandibular envelope of motion as the outer range and intra border mandibular movements as the inner range. In short terms, balancing is achieved when the Christenson phenomenon is compensated in denture occlusion. A female completely edentulous patient reported for complete denture fabrication with excellent neuromuscular control and coordination. History, examination and investigations were insignificant. An innovation of functional chew-in method was utilized to achieve balanced occlusion. Basis was if Christensons phenomena is compensated during jaw relation procedures the when teeth are arranged against that compensation, the balancing will be achieved naturally.

Keywords: occlusion, centric relation, vertical relation, anatomic teeth, christensons phenomena.

INTRODUCTION

Balancing of occlusion in the complete denture infers that the occlusal contacts in both static and dynamic position will contribute in one way or the other to the equilibrium and stability of the denture on their respective residual alveolar ridges. Such type of occlusion is comfortable, readily adaptive in nature, minimizes trauma and more importantly preserves residual alveolar ridge through even distribution of forces. Conventionally, balancing is achieved during teeth arrangement on a semi adjustable articulator that has been programmed to the patient condylar guidance. Teeth are arranged so as they compensate the christensons phenomena which is achieved by incorporating of the anterior - posterior curve (curve of Spee) and medio lateral curves (curve of monsoon and Wilson).^[1-3] A correct centric relation is mandatory to achieve balanced occlusion. Functional (chew-in) methods,^[4,5] have been mentioned in the literature to record centric relation. In order to achieve

balance one needs to know the starting point where opposing teeth touch and the second point where the same teeth touch each other during protrusion or lateral excursion.

This article in the form of clinical case reports describing a modification of functional chew in method (Patterson technique) to achieve balanced occlusion in the complete denture prosthesis. The principle that this case utilizes is if during centric relation record the maxillary occlusal rim is carrying a functional record that has compensated Christenson phenomenon, then when teeth are arranged against such record, occlusion will be balanced on its own.

CASE REPORT

A completely edentulous female patient aged 47 years, reported to the post graduate section of the department of Prosthodontics for replacement of her missing natural teeth. The patient did not report any underlying systemic health problems and had got her teeth extracted about 6 months back. Loss of teeth was due to mobility as well as caries. Social, diet, drug and other related histories were insignificant. Extra oral examination showed normal clinical features with patient exhibiting a good neuromuscular control and coordination [Figure 1a]. Intra oral examination revealed well-

Name & Address of Corresponding Author

Dr. Khurshid A Mattoo
Assistant Professor,
Department of Prosthodontics,
College of dentistry,
Jazan University, (KSA)

formed completely edentulous residual alveolar ridges. After radiographic investigations, the patient consented to a treatment plan that was a complete denture prosthesis with balanced occlusion. The primary diagnostic impression was made following which secondary impressions were made on a custom tray based on selective pressure theory [Figure 1b]. Jaw relations were recorded following which maxillary casts were mounted using an arbitrary face bow (Hanau, Waterpik, Ft Collins, CO, USA) on a Hanau Widevue semi adjustable articulator (Waterpik, Ft Collins, CO, USA) [Figure 1c]. Once the vertical dimensions were established, the centric relation record was made with a functional chew in technique [Figure 1d, e]. A trench was made in the mandibular occlusal rim and a mixture of half plaster and half pumice was then placed in the trench. The mandibular movement generated compensating curves in the recording media. When the plaster and pumice were reduced to the pre-determined vertical dimension of occlusion, the patient was instructed to retrude the mandible and the occlusion rims were joined together. Once the occlusal rims were ready, the maxillary rim was placed as such while the mandibular teeth were arranged first against the generated maxillary rims [Figure 2a].

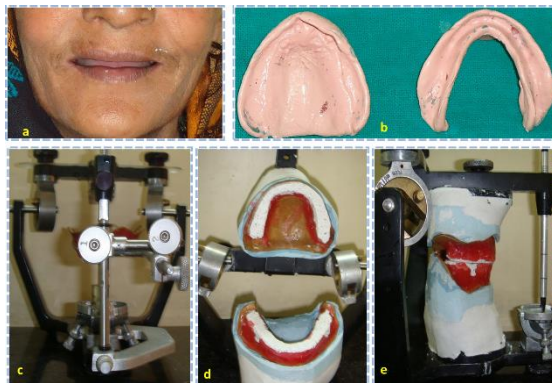


Figure 1: (a) Extra oral view (b) Secondary impressions (c) Face bow transfer (d) and (e) Functional chew in record.

After mandibular teeth were arranged, the maxillary teeth were then placed following their opposing fossa. Clinical and laboratory steps that followed were conventional. Balancing was corrected during laboratory remounting of denture processing [Figure 2b]. Complete denture was inserted and balancing was verified [Figure 2c]. Minor corrections were done using a clinical remount procedure. Instructions regarding denture care were given to the patient. The patient was satisfied with her complete denture prosthesis and reported no problems in occlusion over a period of three follow ups [Figure 2d].

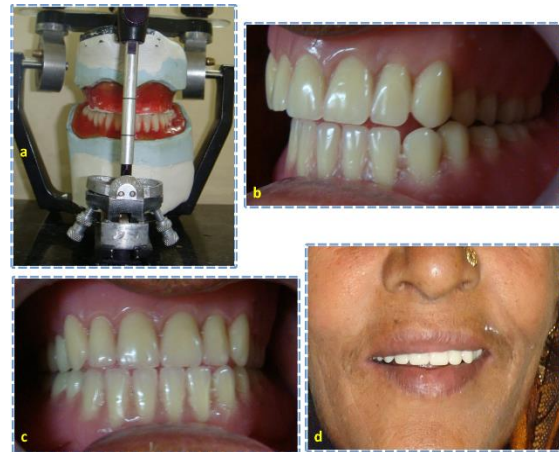

Figure 2:(a) Mandibular teeth arranged against functional maxillary record (b) Processed denture showing balancing contacts (c) Balancing contacts during protrusion (d) Finished complete denture prosthesis

DISCUSSION

There are multiple factors involved in establishing an occlusion that is balanced. Functional chew-in method works by compensating Christensons phenomena which is the space that occur between opposing occlusal surfaces during mandibular protrusion. This space is present in the natural dentition and cannot be provided in complete denture occlusion. If such space exists in the denture, then the dentures will be unstable as they will fall within this space. However, if some contact between cusps is provided, then the space will be obliterated and dentures won't fall. Balancing of occlusion involves five major criteria given by Hanau.⁶ The same principles have been utilized in the present case. Selection of patients is important to minimize errors in recording this space. The patient had very good Neuro muscular control and she demonstrated excellent coordination to the commands given to her by the dentist. The patient was able to control the mandible in one position while the material was setting. Any error at this time will decrease the space between the occlusal rims and will indirectly affect the angulation of compensatory curves later, which in turn will not produce effective balancing contacts between the cusp tips even if the curves are exaggerated. In short, occlusal plane will be affected which is significant for developing balancing as it indirectly affects the cuspal inclination and the compensatory curves.^[7,8] Therefore, selection of cases for such procedure is essential.

One advantage with complete denture prosthesis is that discrepancies in occlusion will not affect stomatognathic system however,^[9] it does affect the residual alveolar ridges in one way or the other.

CONCLUSION

The concept of balanced occlusion is geometrical which has certain ideals that are difficult to accomplish. Utilizing patients neuromuscular ability one can record the Christenson phenomena very easily and achieve balance without having to go through the arduous procedure of mathematical calculations.

Acknowledgements

The authors would like to acknowledge the efforts of all the postgraduate students of department of prosthodontic for their selfless help during the case completion.

REFERENCES

1. Stansbery CJ. Balanced occlusion in relation to lost vertical dimension. JADA. 1938;25:229
2. Pleasure MA. Prosthetic Occlusion a Problem in Mechanics. JADA.1937 24:1303
3. Meyer FS. Balanced and Functional Occlusion in Relation to Denture Work. J.A.DA. 1935; 22:1156
4. Kurth IE . Mandibular Movement and Articular Occlusion. JADA.1949; 39:37-46.
5. Kurth IE. Mandibular movements in mastication. JADA. 29:1769, 1942.
6. Hanau R H. Articulation defined, analyzed, and formulated. J Am Dent Assoc.1926; 13:1694
7. Kurth IE. The Posterior Occlusal Plane in Full Denture Construction. JADA.1940 27:88.
8. Jordan, L. G.: Selective incisal guidance in full denture construction. J Am Dent Assoc. 1933; 20:976
9. Jankelson B, Hoffman GM, and Hendron JA . The physiology of the stomatognathic system. JADA.1953:375-386

How to cite this article: Kumar L, Mattoo KA. Innovating Functional Chew In Method To Establish Balanced Occlusion In Complete Denture – A Case Report. Ann. Int. Med. Den. Res. 2017; 3(6): DE35-DE37.

Source of Support: Nil, **Conflict of Interest:** None declared