

# Comparative Evaluation of Volumetric Changes of Propoint Obturating System: An In Vitro Study.

Shweta Tekriwal<sup>1</sup>, Aniket kumar<sup>1</sup>

<sup>1</sup>MDS in the Department of Conservative Dentistry and Endodontics, Babu Banarasi Das College Of Dental Sciences.

Received: April 2017

Accepted: May 2017

**Copyright:** © the author(s), publisher. It is an open-access article distributed under the terms of the Creative Commons Attribution Non-Commercial License, which permits unrestricted non-commercial use, distribution, and reproduction in any medium, provided the original work is properly cited.

## ABSTRACT

**Background:** Aim To evaluate the immediate and delayed volumetric changes after obturation with ProPoint using CBCT. **Methods:** A prospective observational study was conducted. Orthodontic patients were selected who was slated for all four premolars extraction. Root canal treatment was performed in 25 extracted premolars using hyflex rotary system and were obturated with ProPoints. An artificially moist conditions were maintained by placing the tooth in a damp cotton to simulate a mouth. The CBCT scans were performed pre and post-operatively to observe the volumetric changes immediately and after four hours of the obturation. **Results:** It was found that there is a considerable amount of expansion after four hours of obturation due to the swellable nature of the sealer and the ProPoint. Volumetric expansion of 13- 27 % approximately was observed. **Conclusion:** It was concluded that considerable amount of expansion has taken place in the present case with ProPoint system which occupies the irregularities and the remaining spaces of the canal, improving the hermetic seal.

**Keywords:** Propoints, Hygroscopic Expansion, Swellable Polymers, CBCT.

## INTRODUCTION

Obturation of root canal system should prevent endodontic re- infection and ultimately prevent periradicular disease. This objective may be achieved by three dimensional filling of the prepared canal and the accessory canals. An obturating system called ProPoint system was introduced to overcome these problems and improve the treatment outcome.

### Name & Address of Corresponding Author

Dr. Aniket kumar

MDS in the Department of Conservative Dentistry and Endodontics,  
Babu Banarasi Das College Of Dental Sciences.

The ProPoint system (Endo Technologies, LLC, Shrewsbury, MA, USA) consists of pre- made, hydrophilic endodontic points and an accompanying sealer and it is a point and paste root canal filling technique. This endodontic point is designed to expand laterally, by absorbing residual water from the prepared canal space and that from naturally occurring intraradicular moisture without expanding axially. (Anthony Didato et al 2013).

The inner core of ProPoint is made up of two proprietary nylon polymers: Trogamid T and Trogamid CX and the outer polymer coating is a cross linked using allyl methacrylate and a thermal initiator (Lumbini Pathivada et al 2013).

As per the claim of manufacturer the lateral expansion of ProPoint is non-uniform and when it contacts with the canal wall the rate or extent of

polymer expansion is reduced. Its expansion depends on the extent to which it is pre-stressed. The sealing ability of the root canal filling can be improved by this non-isotropic lateral expansion, thereby possibility of re-infection is reduced, and there are less chances of root canal treatment failures (Anthony Didato et al 2013) ProPoint covers all tip sizes and it is available in 4% and 6% taper from ISO tip size 15-45.

Manufacturers have also claimed that although ProPoint is capable of achieving a good hermetic seal, there may remain some gaps between the walls of the canal and the expanded point. Consequently, an accompanying sealer must be used to seal those areas.

Till date, there has been no direct comparison of the volumetric expansion of ProPoint immediately and after four hours.

## MATERIALS AND METHODS

25 mature and caries free first premolar teeth were selected which were indicated for the orthodontic extraction. Root canal procedure using propoint (endotechnologies, llc, Shrewsbury, ma, usa) obturating system was planned in maxillary and mandibular first premolars.

A preoperative cbct (i- cat vision denta, hatfield, u.k) scan were done to evaluate the internal root canal anatomy of the studied teeth. Mandibular premolars i.e. 34 and 44 had single canal whereas 14 and 24 had two canals (buccal and palatal)

Access opening were done in all the first premolars using highspeed handpiece (nsk, pana air, japan) with endo access bur (dentsply mallifer, switzerland) and working length was established with the help of 15 no. K-file (dentsply mallifer, switzerland) and using apex locator (x-smart, dentsply mallifer, switzerland) and verified with digital radiography system (.....)

Canals were cleaned and shaped using k- files (dentsply, mallefer, switzerland) and hyflex (coltene whaledent, switzerland) rotary system upto 4% 25 upto the proper working length. Proper regimen of irrigation was followed using 5% sodium hypochlorite, 17% edta and 2% chlorhexidine gluconate.

Cbct (i- cat vision denta, hatfield, u.k) scan of prepared canals was done to evaluate the canal volume. Then the canals were dried using paper points and a c-point verifier of size 4%25 was used to verify the determined working length and the desired tug back.

Radiograph was taken to confirm the corresponding c-point of size 4% 25, which was kept 0.5 mm short of the radiographic apex of the tooth.

Canals were again dried using paper points .bio-ceramic sealer(endosequence, brasseler, usa) was then placed in the canal with the help of lentulospiral (dentsply, switzerland).then the c-point was introduced into the canal using tweezers using a slow firm pressure required to allow the c-point to evenly distribute the sealer down into the canal.

The propoint was then trimmed to the level of the canal orifice using a highspeed handpiece and a diamond bur.

Teeth were then restored immediately with glass ionomer cement (gc, tokyo, japan). All teeth were placed in a moist cotton to simulate the mouth conditions.

A cbct (i- cat vision denta, hatfield, u.k) scan was done to evaluate the volume of the obturated canal immediately after the obturation and after four hours of the obturation to evaluate the volumetric expansion of the obturating material.

**RESULTS**

It was seen in the present study that there is a considerable amount of expansion after four hours of obturation due to the swellable nature of the sealer and the Propoint.

**Statistical Analysis**

**Formula used**

The results were analyzed using descriptive statistics and making comparisons between treatment groups with respect to adaptation parameters. Discrete (categorical) data were summarized as in proportions and percentages (%). The following statistics were calculated in the present analysis

The Arithmetic Mean:

The most widely used measure of Central tendency is arithmetic mean, usually referred to simply as the mean, calculated as

$$\bar{x} = \frac{\sum x}{n}$$

The Standard deviation ( $\sigma$ ): It is calculated by using the formula

$$\sigma = \sqrt{\frac{\sum x^2}{n} - \left(\frac{\sum x}{n}\right)^2}$$

Regression Equation: Regression equations are used to express the mathematical relationship between two variables, so that the value of one variable (y) can be predicted from the knowledge of the other (x).

In the most basic form of this technique, simple linear regression, the value of one variable (x) eg. Time of follow up is used to predict the value of the other variable (y) eg. Crestal bone loss, by means of simple linear regression equation.

This straight regression line is of the form

$$y = a + bx$$

Where a and b are constants which are estimated by the data.

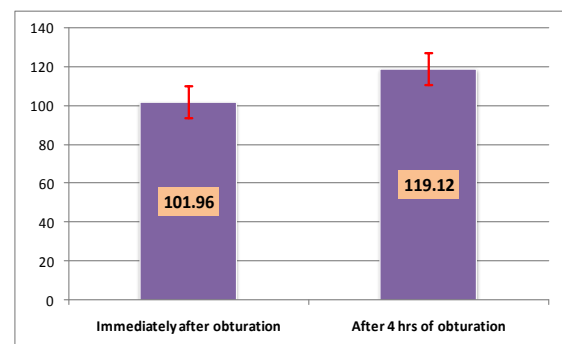
A two-sided ( $\alpha=2$ )  $p<0.05$  was considered statistically significant.

**Observations & Results**

Total no. of Samples = 25

**Table 1: Volumetric Changes after Obturation.**

Factor	Mean	SD	Min	Max
Volume (mm <sup>3</sup> ) immediately after obturation	101.96	9.19	90	116
Volume (mm <sup>3</sup> ) after 4 hrs of obturation	119.12	7.11	107	133
Mean Increase volume %	17.17	4.58	10.71	26.37



**Figure - Volumetric Changes after Obturation**

The mean volume just after obturation was found to be 101.96±9.19 mm<sup>3</sup> with a minimum value reached to 90 mm<sup>3</sup> and maximum reached to 116 mm<sup>3</sup>.

While after 4 hrs of obturation the mean volume was increased to 119.12±7.11 mm<sup>3</sup> with a minimum value reached to 107 mm<sup>3</sup> and maximum reached to 133 mm<sup>3</sup>.

So there was a mean percentage increase of 17.17±4.58 was seen among 25 samples with a minimum percentage increase of 10.71% and maximum percentage increase of 26.37%.

**Table 2: Test of Difference between Volumes at the two time points.**

Variable	Mean Difference	SD	95% CI of Mean Difference		t	P-value
			Lower	Upper		
Immediate Volume vs Volume after 4 hrs	-17.16	3.31	-18.53	-15.79	-25.901	<0.001

The mean difference between Immediate Volume vs Volume after 4 hrs was seen to be - 17.16 with a 95% confidence interval (-18.53, -15.79). According to paired samples Student's t test this difference was found to be highly significant (p<0.001).

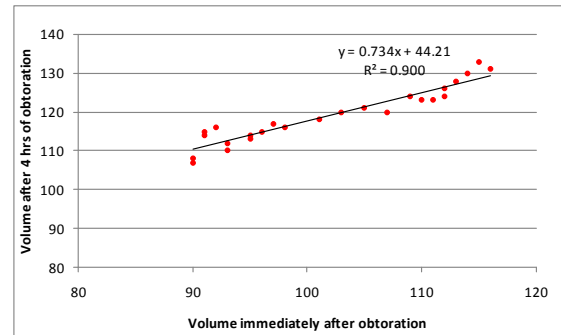
**Table 3: Correlations between Volumes & Volumetric Changes.**

Variable	Parameter	Immediate Volume	Volume after 4 hrs	% Change
Immediate Volume	Pearson Correlation - r		.949**	-.861**
	p - value		<0.001	<0.001
Volume after 4 hrs	Pearson Correlation - r	.949**		-.658**
	p - value	<0.001		<0.001
% Change	Pearson Correlation - r	-.861**	-.658**	
	p - value	<0.001	<0.001	

A high significant positive correlation (r = 0.949, p<0.001) was found between the immediate volume and volume after 4 hrs. It means as value of immediate volume increase, in the same proportion the value of volume after 4 hrs also increase linearly.

On the other hand a high significant negative correlation (r = -0.658, p<0.001) was found between the immediate volume and % change in volume. It means for the larger values of immediate volume, the % change in volume decreases.

The graph showing correlations between immediate volumes and volume after 4 hrs is given below



The following regression equation was estimated to predict volume after 4 hrs on the basis of immediate volume:

$$y = 0.734x + 44.21$$

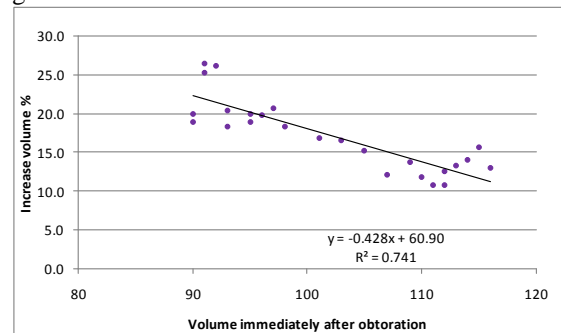
Where x represents the immediate volume, while y represents the volume after 4 hrs.

The above fitted regression line has the goodness of fit value:

$$R^2 = 0.900$$

It means the above equation has 90% predictive accuracy.

The graph showing correlations between immediate volumes and % change in volume after 4 hrs is given below:



The following regression equation was estimated to predict % volume change after 4 hrs on the basis of immediate volume:

$$z = -0.428x + 60.90$$

Where x represents the immediate volume, while z represents the % volume change after 4 hrs.

The above fitted regression line has the goodness of fit value:

$$R^2 = 0.741$$

It means the above equation has 74.1% predictive accuracy.

All the values are calculated using Anatomage version 5.3 of CBCT.

## DISCUSSION

Disparity in root canal anatomy and its tortuous course creates difficulty in three dimensional obturation of the canal space, this may lead to endodontic failure. Different cross-sectional shape of root canal, makes it difficult to achieve a proper

three dimensional obturation (Wu MK & Wesselink PR 2001). Microleakage studies of single cone obturation systems have shown to be inferior in their ability to achieve a fluid tight seal (Monticelli F et al 2007, McKissock AJ et al 2011).

ProPoint being a single- cone obturation technique, is a unique obturating system. This product utilizes the principle of hygroscopic expansion of the in-situ to fill these anatomical gaps, and provide a better three dimensional seal.

Due to the hydrophilic nature of ProPoints the minute amount of water present in the root canal are absorbed by the points which in turn can form hydrogen bond to the polar sites present, enabling expansion within the polymer chains. The rate and extent of this expansion is controlled as a part of manufacturing process. The expansion occurs with a miniscule force that is claimed to be well below the reported tensile stress of dentin (Lumbini Pathivada et al 2013).

According to the manufacturers pro point shows maximum expansion after four hours under in vivo conditions, thus in the present study volumetric changes have been seen after four hours of obturation. The slight positive pressure against the canal wall that is created forms a seal that is believed to be virtually impermeable to bacterial microleakage.

An active polymer is there in bioceramic sealer which controls the degree of swelling. The sealer is dimensionally stable and non- resorbable inside the canal due to the addition of bioceramics. Calcium hydroxide and hydroxyapatite are the by-products of the setting reaction of the sealer, rendering the material both anti-bacterial while setting and very biocompatible once set (Eid et al 2013).

A significant amount of volumetric expansion of ProPoints along with the sealer has been seen in the present study using CBCT. The results were approximately calculated by using Anatomage version 5.3 of CBCT, the latest software. Cementoenamel junction is taken as a standard point for calculating the volume immediately and after four hours of obturation.

## CONCLUSION

From the present study it was concluded that ProPoint can provide a better hermetic seal as compared to other obturating materials due to its hydrophilic nature. It is an excellent biocompatible material which can lead to better prognosis of a root canal treated teeth.

## REFERENCES

1. Anthony Didato, Ashraf A. Eid, Martin D Levin, Sara Khan, Franklin R. Tay, Frederick A. Rueggberg(2013) Time based lateral hygroscopic expansion of a water- expandable endodontic obturation point. Journal of Dentistry, 1-6.

2. Beatty R, Vertucci F, Zakariasen K (1986) apical sealing efficacy of endodontic obturation techniques. International Endodontic Journal 19, 237-41.
3. Eid AA et al (2013) in- vitro Biocompatibility Evaluation of a Root Canal Filling Material that expands on water sorption. Journal of Endodontics 39, 883-888.
4. Grossman L (1981) Endodontic Practice, vol. 10. pp. 279. Philadelphia: Lea and Febiger.
5. Highgate Dj, Frankland JD (1986) Deformable polymeric compositions. United States Patent number 4, 565, 722.
6. Hannigan A, Lynch CD (2013) Statistical methodology in oral and dental research: pitfalls and recommendations. Journal of Dentistry 41, 385-92.
7. Lumbini Pathivada , Karthik Krishna Munagala, Aashima B Dange (2013) Smartseal: New Age Obturation. Annals of Dental Speciality 01, 13-15.
8. Monticelli F, Sadek FT, Schuster GS, Weller RN, Ferrari M, et al (2007) Efficacy of two contemporary single - cone obturation filling techniques in preventing bacterial leakage. Journal of Endodontics 33, 310-3.
9. Michaud RA, Burgess J, Barfield RD, Cakir D, McNeal SF, Eleazer PD(2008) Volumetric expansion of gutta -percha in contact with eugenol. Journal of Endodontics 34, 1528-32.
10. Monticelli F, Sword J, Martin RL, Schuster GS, Weller RN, Ferrari M.....(2007) Sealing properties of two contemporary single-cone obturation systems. International Endodontic Journal 40, 374-85.
11. Mc Kissock AJ, Mines P, Sweet MB, Klyn SL(2011) Ten month in- vitro leakage study of a single -cone obturation system. US Army Medical Department Journal, 42-7.
12. Nagas E, Uyanik MO, Eymirli A, Cehreli ZC, Vallittu PK, Lassila LV,et al (2012) Dentin moisture conditions affect the adhesion of root canal sealers. Journal of Endodontics 38, 240-4.
13. Schilder H (2006) Filling root canals in three dimensions. Journal of Endodontics 32, 281-90.
14. Tronstad L, Barnett F, Flax M (1988) Biocompatibility of calcium hydroxide- containing root canal sealers. Endodontics and Dental Traumatology 4, 152-9.
15. Wu MK, Fan B, Wesselink PR (2000) Diminished leakage along root canals filled with gutta -percha without sealer over time: a laboratory study. International Endodontic Journal 33,121-5
16. Wu MK, Wesselink PR (2001) A primary observation on the preparation and obturation in oval canals. International Endodontic Journal 34, 137-41.

**How to cite this article:** Tekriwal S, Kumar A. Comparative Evaluation of Volumetric Changes of Propoint Obturating System: An In Vitro Study. Ann. Int. Med. Den. Res. 2017; 3(4):DE09-DE12.

**Source of Support:** Nil, **Conflict of Interest:** None declared