

# A Rare Case of Multiple Calcifications and Vascular Malformation within the Parenchyma of the Parotid Salivary Gland Coinciding With an Intracranial Meningioma.

Mahmoud M. Bakr<sup>1</sup>, Pak Poon<sup>2</sup>, Sylvana Parkinson<sup>3</sup>, Nabil Khzam<sup>4</sup>

<sup>1</sup>Lecturer in General Dental Practice, School of Dentistry and Oral Health, Griffith University, Gold Coast, QLD 4222, Australia

<sup>2</sup>General Dentist, Private Practice, Perth, WA 6001, Australia

<sup>3</sup>General Dentist, Private Practice, Perth, WA 6001, Australia

<sup>4</sup>Specialist Periodontist, Gateway Dental Specialists, Booragoon, Perth, WA 6154, Australia

Received: July 2017

Accepted: July 2017

**Copyright:** © the author(s), publisher. It is an open-access article distributed under the terms of the Creative Commons Attribution Non-Commercial License, which permits unrestricted non-commercial use, distribution, and reproduction in any medium, provided the original work is properly cited.

## ABSTRACT

Multiple calcifications in salivary glands have been previously reported in inflammatory and autoimmune disorders. However, the etiology and mechanism of formation of such calcifications are not yet fully understood. A very rare case of a 50 year female with multiple calcifications and vascular malformation within the left parotid salivary gland is presented. Further investigations of the lesion uncovered an intracranial meningioma in the contralateral posterior cranial fossa. Additional investigations and multidisciplinary specialist management was deemed necessary to shed some light on the degree of association between the calcific foci within the parotid gland and the intracranial meningioma.

**Keywords:** Calcification, CT Scan, Parotid gland, Sialolithiasis.

## INTRODUCTION

Sialolithiasis or calcifications within salivary glands are more common in the submandibular gland (80%-90%), when compared to the parotid gland (5%-20%).<sup>[1]</sup> A number of cases reported multiple sialolithiasis in the Stensen's duct of the parotid gland, however there was no statement in relation to calcifications in the parenchyma of the parotid gland.<sup>[2-4]</sup> There might be a possible correlation between sialolithiasis and systemic disorders. However, not enough evidence have been found in the literature. Examples include the coincidence of sialolithiasis and nephrolithiasis was reported in patients with Sjögren's syndrome, a case with renal and pancreatic calcifications,<sup>[5]</sup> a case with arthritis mutilans and tumoral calcifications and a number of cases with pseudotumors with calcifications in the parotid

Gland.<sup>[6-8]</sup> In general, multiple sialolithiasis in the parenchyma of the parotid gland have not yet been reported. Incidentally detected parotid salivary gland calcifications have been associated with chronic conditions including HIV, alcoholism, chronic kidney disease, autoimmune disease, and elevated alkaline phosphatase.<sup>[9]</sup> The proposed association between parotid gland calcification and chronic conditions is a consequence of a chronic lymphocyte-mediated destruction of the exocrine glands that eventually leads to intraductal calcification.<sup>[10-22]</sup>

Several imaging modalities, such as plain X-ray examination,<sup>[23, 24]</sup> sialography, ultrasound (US), magnetic resonance imaging (MRI), 18F-FDG positron emission tomography (PET) and computed tomography (CT),<sup>[25-27]</sup> are available for detection of calcifications in the parotid gland. CT is the most useful tool in detection and evaluation of small calcifications because of its high spatial resolution.<sup>[28,29]</sup> MRI, CT and US are the methods of choice for obstruction of ducts or tumours in the salivary glands whereas scintigraphy is preferred for examination of parenchymal damage and glandular function, especially Sjögren Syndrome. MRI is superior in characterization of local invasion, extension of larger lesions and in identifying nodal spread as well as the extra-cranial

### Name & Address of Corresponding Author

Dr. Mahmoud Bakr  
Lecturer in General Dental Practice  
School Of Dentistry and Oral Health  
Griffith University  
QLD 4222,  
Australia.

part of the facial nerve. CT may also be used for tumour staging possibly in combination with 18F-FDG/PET, which is not used as a primary diagnostic tool. However, it may have a potential for staging and restaging of malignant salivary gland tumours.<sup>[25]</sup>

### CASE REPORT

A 50 year old female was referred to specialist periodontist (NK) for management of her periodontal disease as well as a second opinion on the radiopaque lesions within left parotid gland on the OPG [Figure 1]. The patient is medically healthy apart from a family history of diabetes and is currently on antidepressant medications. The patient was referred for a CT scan for further investigation of the radiopaque lesions [Figure 2]. Unenhanced axial sections of the mandible were obtained. Coronal and sagittal reconstructions were performed in the CT scan. CT scan results revealed seventeen calcific foci with different sizes ranging from 0.2cm to 1.3cm and projected over the left parotid gland. The calcific foci were noted within the parotid gland substance and along the margin of the superficial and deep lobes. The largest focus was noted along the posterior margin of the left ramus of the mandible and measuring 1.1cm X 1.3cm in cross sectional dimensions. The calcific foci within the parotid gland represented either sialoliths (calculi) or dystrophic calcification secondary to long standing chronic inflammation. No evidence of calcification was present along the parotid gland duct, the right parotid gland or submandibular glands. There were no osteolytic lesions or exostoses detected in the mandible. There was an increase in the number of lymph nodes bilaterally, indicating a possible lymph node proliferative abnormality.

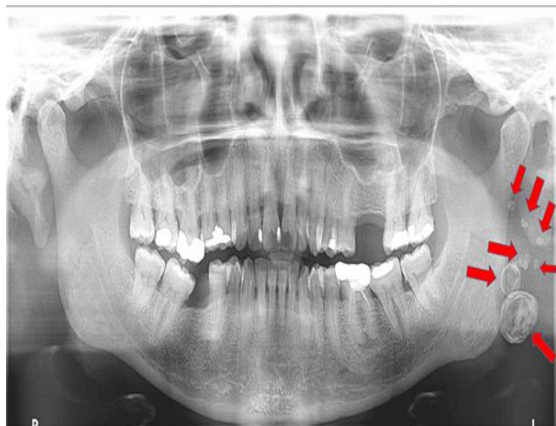

Figure 1: Showing an Orthopantomograph (OPG) of the patient showing the multiple calcific foci on the left side (arrows).

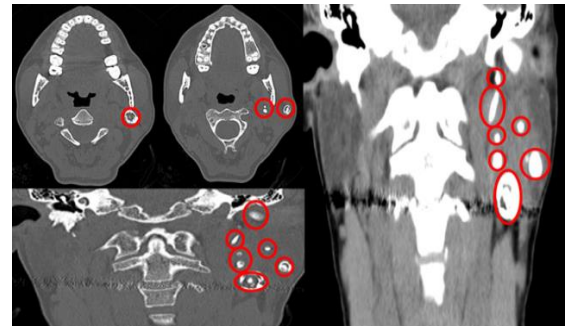


Figure 2: Showing a number of CT scan sections with illustrations of the calcific foci on the left side (red circles).

The patient was then referred for Magnetic Resonance Imaging (MRI). MRI results confirmed the findings from the CT scan and showed a large lesion (5cm) involving the deep lobe and the deep portion of the superficial lobe of the left parotid gland. The lesion represented a typical venous vascular malformation and contained multiple phleboliths [Figure 3]. The lesion had lobular margins without any evidence of arterial vessels within it. Therefore, biopsy of the lesion was not advised and a referral to an Ear Nose and Throat surgeon was recommended. Furthermore, there was an incidental finding of a 1.5cm lesion (Meningioma) on the right posterior cranial fossa with a broad base along the petrous apex posterior to the right internal auditory cana [Figure 4 & 5]. There was no significant mass effect on the brain parenchyma. Referral to a Neurosurgeon was also recommended.

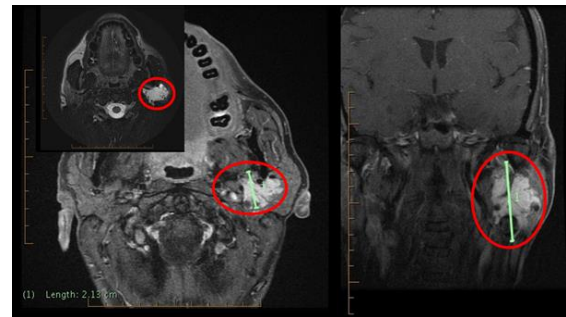


Figure 3: Showing a number of MRI sectional images with the left parotid gland lesion highlighted (Red circles).

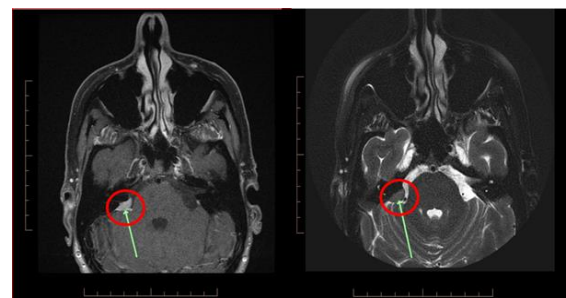
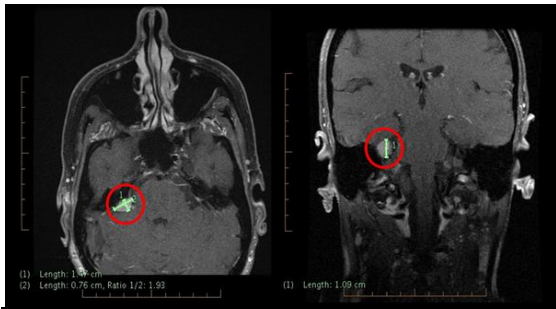


Figure 4: Showing intracranial MRI sectional images highlighting the location of the Meningioma (Green arrows and red circles).



**Figure 5: Showing intracranial MRI sectional images highlighting the size and measurements of the Meningioma (Green arrows and red circles).**

## DISCUSSION

A number of authors reported the multiple calcifications in their sonographic criteria for Sjögren's syndrome, as one of the characteristics in the most severe grade.<sup>[30-32]</sup> The majority of the cases reported are unilateral, however, a case of bilateral multiple sialolithiasis has been reported.<sup>[33]</sup> It was not mentioned in any of the above reports if these calcifications were real or just hyperechoic spots. If they were real microliths, it could be concluded that these microliths only appear in the severely damaged gland parenchyma of Sjögren's syndrome. Beyond Sjögren's syndrome, association of multiple calcifications with other inflammatory salivary diseases has not been characterized beyond individual case reports.<sup>[34]</sup>

With regards to calcifications in salivary glands, they could be a form of sialolithiasis, dysplastic calcifications in inflammatory salivary gland tissues or calcified venous thrombi.<sup>[35]</sup> In the present case, the salivary gland tissues were inflamed and the patient suffered from an intracranial meningioma as well. Therefore, it is difficult to determine the exact etiology of the calcific foci. With regards to association between sialolithiasis and tumors, a case of sialolithiasis in Mucous Associated Lymphoid Tissue (MALT) Lymphoma was described. However, the authors concluded that both conditions have most likely developed independently.<sup>[36]</sup> This is also the most acceptable explanation for the present case as the meningioma was evident on the contralateral side to the multiple calcific foci. There are some limitations to this investigation including the absence of a detailed analysis of the components of the calcific components, the difficulty of determining the exact mechanism of formation of all calcific foci, and the correlation between the multiple calcifications and the meningioma.

Differential diagnosis of this present case could include pleomorphic adenoma, soft tissue chondroma or osteoma, extracranial meningioma, osteocartilaginous tumors arising from bone exostoses,<sup>[37]</sup> vascular ossification of

atherosclerotic lesions, or hereditary conditions such as Albright's syndrome and fibrodysplasia ossificans progressive.<sup>[38]</sup> In the present case, the patient was referred to an ENT surgeon and a Neurosurgeon to exclude any possible malignancies. The importance of clinical suspicion for a malignancy in the presence of a calcified mass has been highlighted in literature.<sup>[39]</sup> The above mentioned referrals were absolutely essential in the present as a biopsy was not recommended for this case due to the vascular malformation that was evident within the lesion. It should be noted that Salivary gland tumors rarely show calcifications in the parenchymal tissue; however, it is commonly seen in inflammatory disorders of salivary glands.<sup>[40]</sup>

The mechanism of parotid calcification in cases of inflammatory/autoimmune disorders is not well understood, but it was hypothesized to involve calcification and calculus formation related to insufficient salivary flow and high concentrations of calcium salts in the saliva.<sup>[22,33]</sup> Therefore, incidental parotid calcifications seen on imaging have been typically linked to chronic autoimmune/inflammatory conditions. A detailed medical history as well as further clinical and serological investigations are necessary for the present case in order to exclude a number of associated medical conditions as well as determining the degree of association between the multiple parotid calcifications and the intracranial meningioma.

## CONCLUSION

A case of multiple calcific foci within the left parotid gland was presented. During the investigation, an incidental finding of a Meningioma in the right posterior cranial fossa. To our knowledge similar cases were not previously reported. The etiology of the calcific foci and the degree of association between them and the intracranial meningioma need further investigations and medical specialist management. For the above mentioned reason a careful medical reassessment of the patient was deemed necessary.

## REFERENCES

1. Lustmann J, Regev E, Melamed Y. Sialolithiasis. A survey on 245 patients and a review of the literature. *Int J Oral Maxillofac Surg* 1990;19:135-8.
2. Nahlieli O, London D, Zagury A, Eliav E. Combined approach to impacted parotid stones. *J Oral Maxillofac Surg* 2002;60: 1418-23.
3. Nahlieli O, Shacham R, Bar T, Eliav E. Endoscopic mechanical retrieval of sialoliths. *Oral Surg Oral Med Oral Pathol Oral Radiol Endod* 2003;95:396-402.
4. Isacson G, Lundquist PG. Salivary calculi as an aetiological factor in chronic sialadenitis of the submandibular gland. *Clin Otolaryngol* 1982;7:231-6.

5. Grindulis KA, Roy S. Case report. Renal and pancreatic calcification in rheumatoid arthritis with Sjögren's syndrome. *Br J Rheumatol* 1987;26:212-5.
6. Monteagudo M, Lima J, Bravo ML, Gracia-Bragado F, Lience E, Vilardeell M, et al. Case report. Arthritis mutilans, tumoral calcinosis, Raynaud's phenomenon and Sjögren's syndrome. *Br J Rheumatol* 1990;29:303-5.
7. Takashima S, Nagareda T, Noguchi Y, Takeuchi N, Tomiyama N, Johkoh T, et al. CT and MR appearances of parotid pseudotumors in Sjögren syndrome. *J Comput Assist Tomogr* 1992;16:376-83.
8. Kurabayashi T, Tanaka A, Ida M, Ohbayashi N, Yoshino N, Sasaki T, et al. CT findings in Sjögren's syndrome with suspected parotid tumor. *Dent Radiol* 1996;36:14-21. Japanese.
9. Buch K, Nadgir RN, Fujita A, Tannenbaum AD, Ozonoff A, Sakai O. Clinical Associations of Incidentally Detected Parotid Gland Calcification on CT. *The Laryngoscope*. 2015;125: 1360-1365.
10. Yousem DM, Kraut MA, Chalian AA. Major salivary gland imaging. *Radiology* 2000;216:19-29.
11. Skinner LJ, Conlon BJ, Hegarty S, et al. Ectopic ossification in the parotid gland. *Rev Laryngol Otol Rhinol (Bord)* 2003;124:243-245.
12. Van den Akker HP. Diagnostic imaging in salivary gland disease. *Oral Surg Oral Med Oral Pathol* 1988;66:625-637.
13. Lustmann J, Regev E, Melamed Y. Sialolithiasis. A survey on 245 patients and a review of the literature. *Int J Oral Maxillofac Surg* 1990;19:135-138.
14. Shi H, Wang P, Wang S, et al. Pleomorphic adenoma with extensive ossified and calcified degeneration: unusual CT findings in one case. *AJNR Am J Neuroradiol* 2008;29:737-738.
15. Song HU, Kwon KJ, Koh KJ. Adenocarcinoma of the parotid gland with calcification. *Dentomaxillofac Radiol* 2003;32:134-136.
16. Weon YC, Park SW, Kim HJ, et al. Salivary duct carcinomas: clinical and CT and MR imaging features in 20 patients. *Neuroradiology* 2012;54: 631-640.
17. King AD, Ahuja AT, To EW, et al. Carcinosarcoma of the parotid gland: ultrasound and computed tomography findings. *Australas Radiol* 1999; 43:520-522.
18. Maruya S, Kurotaki H, Fujita S, et al. Primary chondrosarcoma arising in the parotid gland. *ORL J Otorhinolaryngol Relat Spec* 2001;63:110-113.
19. Sakai O, Nakashima N, Takata Y, et al. Acinic cell carcinoma of the parotid gland: CT and MRI. *Neuroradiology* 1996;38:675-679.
20. Harrison JD. Causes, natural history, and incidence of salivary stones and obstructions. *Otolaryngol Clin North Am* 2009;42:927-47.
21. Harrison JD. Ultrastructural observation of calcification in a pleomorphic adenoma of the parotid gland. *Ultrastruct Pathol* 1991;15:185-188.
22. Guggenheimer J, Wiggins HE. Parotid calcifications in Sjögren's syndrome. *Oral Surg Oral Med Oral Pathol* 1970;30:378-379.
23. Sun Z, Zhang Z, Fu K, et al. Diagnostic accuracy of parotid CT for identifying Sjögren's syndrome. *Eur J Radiol* 2012;27. PubMed ID: 22285605, [Epub ahead of print].
24. Suleiman SI, Hobsley M. Radiological appearances of parotid duct calculi. *Br J Surg* 1980;67:879-80.
25. Afzelius P, Nielsen M, Ewertsen C, Bloch KP. Imaging of the major salivary glands. *Clin Physiol Funct Imaging* 2016; 36:1-10.
26. Shimizu M, Yoshiura K, Nakayama E, et al. Multiple sialolithiasis in the parotid gland with Sjögren's syndrome and its sonographic findings – report of 3 cases. *Oral Surg Oral Med Oral Pathol Oral Radiol Endod* 2005;99:85-92.
27. Williams MF. Sialolithiasis. *Otolaryngol Clin North Am* 1999;32:819-34.
28. Bryan RN, Miller RH, Ferreyro RI, et al. Computed tomography of the major salivary glands. *Am J Roentgenol* 1982;139:547-54.
29. Mandel L, Hatzis G. The role of computerized tomography in the diagnosis and therapy of parotid stones: a case report. *J Am Dent Assoc* 2000;131:479-82.
30. De Vita S, Lorenzon G, Rossi G, Sabella M, Fossaluzza V. Salivary gland echography in primary and secondary Sjögren's syndrome. *Clin Exp Rheumatol* 1992;10:351-6.
31. Salaffi F, Argalia G, Carotti M, Giannini FB, Palombi C. Salivary gland ultrasonography in the evaluation of primary Sjögren's syndrome. Comparison with minor salivary gland biopsy. *J Rheumatol* 2000;27:1229-36.
32. Carotti M, Salaffi F, Manganelli P, Argalia G. Ultrasonography and colour Doppler sonography of the salivary glands in primary Sjögren's syndrome. *Clin Rheumatol* 2001;20:213-9.
33. Konstantinidis I, Paschaloudi S, Triaridis S, Fyrmpas G, Sechlidis S, Constantinidis J. Bilateral multiple sialolithiasis of the parotid gland in a patient with Sjögren's syndrome. *ACTA Otorhinolaryngologica Italica* 2007;27:41-44.
34. Jáuregui E, Kiringoda R, Ryan WR, Eisele DW, Chang, JL. Chronic parotitis with multiple calcifications: Clinical and sialendoscopic findings. *The Laryngoscope*. 2016 [Epub ahead of print]. <http://dx.doi.org/10.1002/lary.26386>
35. Rauch S, Gorlin RJ. Diseases of the salivary glands. In: Gorlin RJ, Goldman HM, editors. *Thoma's oral pathology sixth edition*, vol. 2. Missouri: C.V. Mosby Co; 1970. p. 996-1003.
36. Wickramasinghe A, Howarth A, Drage NA. Multiple bilateral parotid sialoliths in a patient with mucosa-associated lymphoid tissue lymphoma (MALT lymphoma) of the salivary glands. *Oral Surg Oral Med Oral Pathol Oral Radiol Endod* 2005;99:496-8.
37. Kato H, Kanematsu M, Ando K et al. Ossifying pleomorphic adenoma of the parotid gland: a case report and review. *Australasian Radiology* 2007;51(4):B173-B175.
38. Mori M, Kasai T, Shrestha P et al. Heterotopic ossifying tumors in head and neck and heterotopic ossification and calcification. *Journal of Oral and Maxillofacial Surgery, Medicine, and Pathology* 2012; 24(4):222-236.
39. Mohan S, Puram SV, Yarlaga B, Nosé V, Deschler DG. Ossifying Parotid Carcinoma ex Pleomorphic Adenoma. *Case Reports in Otolaryngology* 2015; 395358. <http://dx.doi.org/10.1155/2015/395358>
40. Ananthaneni A, Ponnappalli H, Kiresur MA, Krishna Chaitanya SV. Mucoepidermoid carcinoma involving the palate with lamellated calcifications: A notable finding. *Eur J Gen Dent* 2016; 5:35-8.

**How to cite this article:** Bakr MM, Poon P, Parkinson S, Khzam N. A Rare Case of Multiple Calcifications and Vascular Malformation Within the Parenchyma of the Parotid Salivary Gland Coinciding With an Intracranial Meningioma. *Ann. Int. Med. Den. Res.* 2017; 3(5): DE09-DE12.

**Source of Support:** Nil, **Conflict of Interest:** None declared