

# A Rare Case Report of Non- Hereditary Ectodermal Dysplasia with Impacted Teeth in Maxilla and Mandible in 18 Year Old Male.

Karthik Shunmugavelu<sup>1</sup>

<sup>1</sup>Consultant Dental Surgeon, Mercy Multispeciality Dental Centre. Chrompet, Chennai.

Received: October 2016

Accepted: February 2017

**Copyright:** © the author(s), publisher. It is an open-access article distributed under the terms of the Creative Commons Attribution Non-Commercial License, which permits unrestricted non-commercial use, distribution, and reproduction in any medium, provided the original work is properly cited.

## ABSTRACT

Ectodermal dysplasia is characterised by hypotrichosis, hypohidrosis and hypodontia. This X linked Mendelian type involving one or more ectodermal structures is usually seen in males rather than females. Etiology leads to disorder in the morphological aspect of cutaneous and oral embryonic ectoderm. We report a case of 18 year old male presenting features of ectodermal dysplasia with multiple impacted teeth in maxilla and mandible.

**Keywords:** Hypohidrosis, Hypotrichosis, Hypodontia, Ectodermal dysplasia.

## INTRODUCTION

Defects in the derivatives of embryonic ectoderm involving two or more tissues lead to ectodermal dysplasia. Thurnam introduced the term in 1848 which was later coined by Weech in 1929. This X - linked inheritance, gene locus Xq11 -21.1, is mostly seen in males rather than in females.<sup>[3-5]</sup> The dentition is affected due to its occurrence in the first trimester of pregnancy or even before the sixth week of embryonic life. Remaining ectodermal structures might be involved after eight weeks. Occurrence hints at frequency of 7 cases per 10,000 births.<sup>[2]</sup> Christ-Siemens Touraine syndrome and Clouston syndrome accounts for syndromal involvement. Skin, hair, nails, eccrine glands, and teeth are commonly involved.<sup>[8, 11]</sup> Here, we are present a case of ectodermal dysplasia in 18 year old male with multiple impacted teeth in maxilla and mandible.

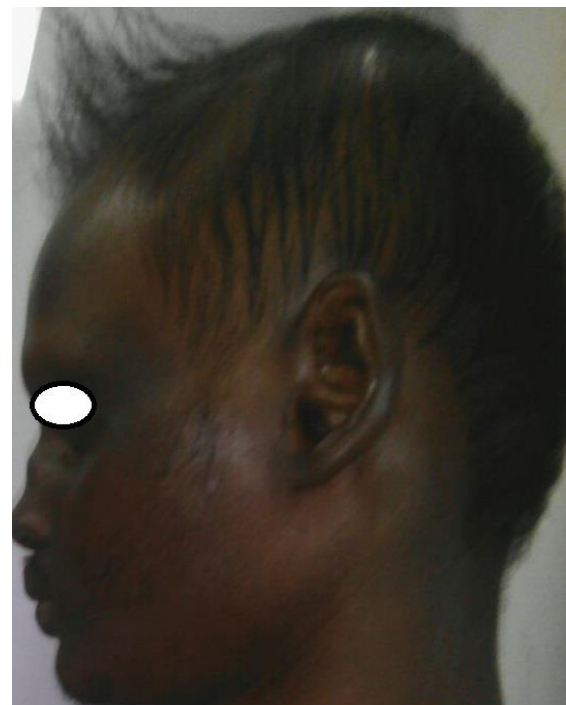### Name & Address of Corresponding Author

Dr. Karthik Shunmugavelu  
Consultant Dental Surgeon,  
Mercy Multispeciality Dental Centre,  
Chrompet, Chennai,  
Tamilnadu, India.

## CASE REPORT

A 18 year old male patient attended the Department of Dentistry with a chief complaint of absence of majority of teeth. Patient was conscious, oriented and afebrile. Vitals stable. Mouth opening and lateral temporomandibular joint movements were

satisfactory. Hair distribution was sparse. Tolerant to heat was unsatisfactory. Skin, palms and soles were dry and parched. Protuberant lips, frontal bossing and depressed nasal bridge were also observed in extraoral examination. Vertical dimension of face was also reduced [Figure 1, Figure 2, Figure 3].



**Figure 1: Left lateral view.**

Majority of the teeth were missing during intra oral examination. Radiological investigations such as

orthopantomograph revealed multiple impacted teeth in maxilla and mandible [Figure 4]. Family history revealed that this condition has been observed only in this individual since generations on both parents side.



Figure 2: Facial view.

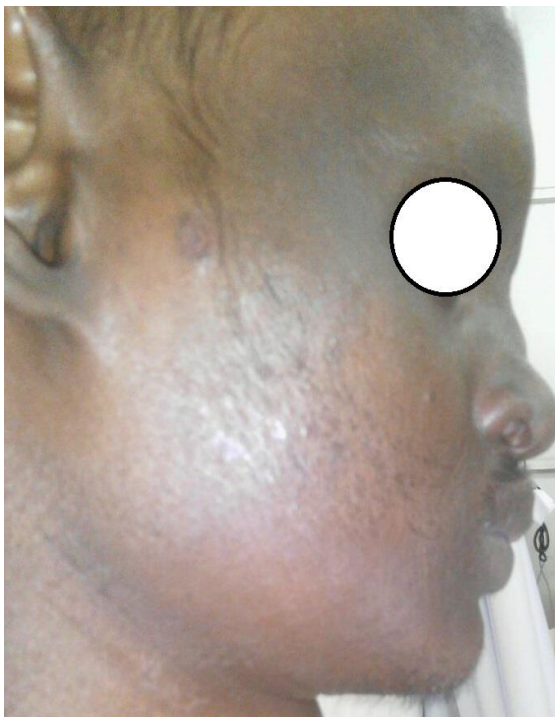

Figure 3: Right lateral view.

## DISCUSSION

First type of ectodermal dysplasia is associated with hypotrichosis, hypohidrosis and hypodontia termed as Christ-Turaine syndrome, a X-linked type. Secondly, Clouston syndrome involving hair, nails and teeth excluding sweat glands is mentioned. Other syndromes depicting hereditary ectodermal dysplasia includes Rapp-Hodgkin Syndrome, Strandberg- Ronchese's Syndrome, Rosseli-Gulienetti Syndrome, etc. The characteristic features include fine, sparse, lustreless fair hair in scalp, scaling of the skin, pyrexia, heat intolerance caused due to anomalies of the skin appendages, which include the hair follicles, sweat glands and sebaceous glands.<sup>[6,7,9]</sup> frontal bossing, depressed malar prominence and nasal bridge, small size of the face, thick everted protuberant lips, wrinkled hyper pigmented, periorbital skin and large low set ears.<sup>[10]</sup> In our case, facial hyperpigmentation, frontal bossing, protuberant lips, decreased facial vertical dimension, normally set ears bilaterally, depressed nasal bridge followed by malar prominence, sparse hair, absence of alveolar processes, missing teeth and impacted teeth (seen radiographically) were presented. Differential diagnosis includes progeria, incontinentia pigmenti, congenital syphilis, idiopathic hypoparathyroidism – Addison's disease – moniliasis syndrome, Rothmund-Thomson syndrome and Chondroectodermal dysplasia.

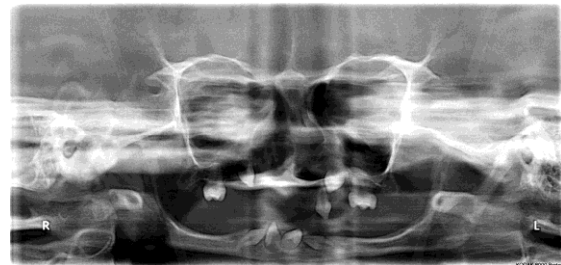


Figure 4: Orthopantomograph revealed multiple impacted teeth in maxilla and mandible.

This condition attracts multidisciplinary approach of a dental surgeon, faciomaxillary surgeon, orthodontist and prosthodontist. Esthetics and function can be enhanced by prosthodontic measures such as implants.<sup>[1]</sup> Mainly, the absence of teeth might have a psychological impact on the individual. All these can be managed in a comprehensive manner if the condition is diagnosed early.

## CONCLUSION

This condition is usually of hereditary nature, whereas in our case the family history played a major role in depicting that non-hereditary type exists as well.

## REFERENCES

1. Geetha Paramkusam,Venkateshwarlu Meduri, Lakshmi Kavitha Nadendla, Namrata Shetty. Hereditary Hypohidrotic Ectodermal Dysplasia – Report of a Rare Case.J Clin Diagn Res.2013 Sep.;7(9):20174-2075.
2. Singh G, Kapoor A, Sharma V, Dhameja M. Ectodermal Dysplasia: A Case Report.Indian J Stomatol 2012; 3(3):187-89.
3. Sharma J, Mamatha G. Hereditary Ectodermal Dysplasia: Diagnostic Dilemmas.Rev Clín Pesq Odontol 2008;4(1):35-40.
4. Bonilla DE, Guerra L, Luna O. Overdenture prosthesis for oral rehabilitation of hypohidrotic ectodermal dysplasia: A case report. Quintessence Int. 1997 Oct;28(10):657–65
5. Ithagarun A, King NM. Ectodermal Dysplasia: A Review and case Report. Quintessence Int. 1997 Sep;28(9):595–02.
6. Gorlin RJ, Pindborg JJ. Syndromes of Head and Neck. 1st ed. New York: McGraw-Hill; 1964.
7. Crawford PJ, Aldred MJ, Clarke A, Tso MS. Rapp-Hodgkin Syndrome:An Ectodermal Dysplasia Involving the Teeth, Hair, Nails And Palate. Oral Surg Oral Med Oral Pathol. 1989;67:50–62
8. Rajendran R. Shafer’s Textbook of oral pathology. 6 ed. Philadelphia: Saunders; 2009.
9. Ramos V, Giebink DL, Fisher JG, Christensen LC. Complete Dentures for a child with Hypohidrotic Ectodermal Dysplasia: A Clinical Report. J Prosthet Dent. 1995;24:329–31.
10. Saggoo S, Munde A, Hebbale M, Joshi M. Ectodermal Dysplasia. Journal of Indian Academy of Oral Medicine and Radiology. 2009;21(2):76–78.
11. Neville BW, Damm DD, Allen CM, Bouquet JE. Oral and Maxillofacial Pathology. 2nd ed. Philadelphia: Saunders; 2002.

**How to cite this article:** Shunmugavelu K. A Rare Case Report of Non- Hereditary Ectodermal Dysplasia with Impacted Teeth in Maxilla and Mandible in 18 Year Old Male. Ann. Int. Med. Den. Res. 2017; 3(2):DE05-DE07.

**Source of Support:** Nil, **Conflict of Interest:** None declared