

Minimum Access for Maximum Success.

Neha S¹, Nagamaheshwari X², Ravichandra C³, Shekar K⁴, Sindhura G⁵, Smitha R⁶

¹Senior lecturer, Department of Conservative & Endodontics, Sri Sai College Of Dental Surgery, Vikarabad, Telangana, India.

²Post Graduate Student, Department of Conservative & Endodontics, Sri Sai College Of Dental Surgery, Vikarabad, Telangana, India.

³Reader, Department of Conservative & Endodontics, Sri Sai College Of Dental Surgery, Vikarabad, Telangana, India.

⁴Professor, Department of Conservative & Endodontics, Sri Sai College Of Dental Surgery, Vikarabad, Telangana, India.

⁵Reader, Department of Conservative & Endodontics, Sri Sai College Of Dental Surgery, Vikarabad, Telangana, India.

⁶Professor, Department of Conservative & Endodontics, Sri Sai College Of Dental Surgery, Vikarabad, Telangana, India.

Received: April 2017

Accepted: April 2017

Copyright: © the author(s), publisher. It is an open-access article distributed under the terms of the Creative Commons Attribution Non-Commercial License, which permits unrestricted non-commercial use, distribution, and reproduction in any medium, provided the original work is properly cited.

ABSTRACT

Access cavity preparation is an important step to attain the longstanding success of endodontically treated teeth. But this success determining step is neglected by clinging to the traditional designs which were formulated based on the armamentarium and restorative materials available at that time. It's the time to shift towards more conservative preparation as nothing can compensate for natural dentine.

Keywords: Pericervical dentine; Molar; Soffit; Stepped access.

INTRODUCTION

The Secret of Change Is To Focus All Your Energy, Not On Figurehting the Old, but On Building the New- Socrates. For the success of endodontic procedure the clinician need to take numerous factors into consideration. They can be categorized into three factors a) Restorative b) Tooth and c) Operator. Traditional endodontic access has focussed much on operator needs and neglected restorative and tooth needs. The inclination towards one of these factors results in imbalance compromising the rest which, ultimately leads to failures. Astonishingly in most of the cases failure was not because of chronic or acute apical lesions but because of structural compromises.

The above facts undoubtedly tells the significance of minimal access preparation of teeth which primarily aims to retain pericervical dentine (PCD) to, reinforces the root canal treated teeth. This conservative access preparation is very much required in the case of molars as they are 1) Nearer to hinge (TMJ) making them the subjects of heavy forces and 2) Their inability to splay the forces as anterior teeth.

Name & Address of Corresponding Author

Dr. Neha Singh
Senior lecture,
Department of Conservative & Endodontics,
Sri Sai College Of Dental Surgery, Vikarabad,
Telangana, India Pincode: 501101

The reasons for the shift from traditional access to conservative dentin saving access. 1) Failure of

endodontic monoblock to reinforce the endodontically treated tooth^[1], 2) Intra coronal composite failed to strengthen the tooth^[2], 3) Placement of posts did not benefit molars^[3] and 4) Many stress tests has proved the crack initiation in endodontically treated root^[4,5]. Hence, for long term biological and functional integrity of root canal treated teeth there is a need to shift from traditional access to more conservative access.

CLASSIFICATION

They can be classified as

- A) Conservative access without the aid of CBCT
- B) Conservative access with the aid of CBCT

Conservative access without the aid of CBCT: Traditional model removes much of the pericervical dentin to serve the following purposes 1) Convenience for the placement of instruments during radicular preparation, 2) Convenience for the placement of instruments during obturation. Such radical treatment ultimately compromises the structural integrity and lastly leads to failure.

Hence utmost importance is given to conserve the pericervical dentin and soffit which includes the dentin over pulp horns to reinforces the tooth structure so has to provide high 3D ferrule. Because no man-made material or technique can become a replacement for tooth structure lost, in strategic areas of the PCD .This can be explained in the following [Figure 1].

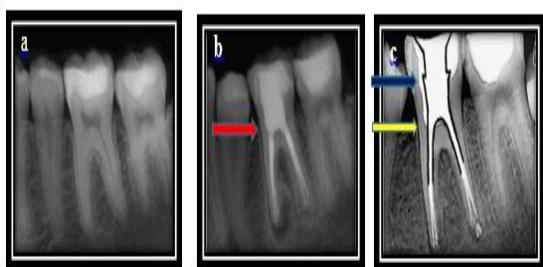


Figure 1: a) Pre-operative view, b) Traditional access preparation which removed PCD (red arrow) c) Minimal access conserving pericervical dentine (Yellow arrow) and soffit (blue arrow).^[6]

Pericervical dentin, cervical enamel, coronal enamel and secondary dentin are tooth structures where in every effort should be made to preserve to maintain optimal strength that ultimately paves the way for obtaining a long-standing fully functioning endodontically treated tooth.

Destructive nature of presently used armamentarium: Any treatment procedure cannot be completed without the aid of armamentarium. But, what if these useful tools become destructive. Yes, literature says that few of them are very aggressive in their action and endanger the integrity of the tooth. A special mention is required about round burs and Gates Glidden burs.

Gates Glidden (GG) burs: With the advent of rotary files, GG no 4, 5 and 6 burs have been used more aggressively to reduce binding and fracture of files. Even though their passive tip and self-centering ability are advantageous, they are accompanied by disadvantages like inability to navigate them away from high-risk anatomy which can weaken or create strip perforations. Hence there has been growing support against their usage.^[6]

Destructive nature of round burs: Literature shows round bur technique during access cavity preparation relies on tactile feedback to de-roof the chamber as the bur drops into the chamber as shown in [Figure 2]. This imaginary model can be applied only in the cases where pulp chamber is large enough. But in day-to-day clinical practice such cases are not so frequent. Application of such imaginary guidelines with burs whose size larger than chamber as shown in [Figure 3.b] and the omnidirectional cutting blades will cause inverse funnelling, blind tunnelling paving the way for iatrogenic trauma as in [Figure 4].

It is not mandatory to deroof completely: Complete deroofing was considered as a mark of a thorough clinician, but authors now began to maintain a soffit, which is a small piece of roof around the entire coronal portion of the pulp chamber. The reason to maintain the soffit: a) To avoid the collateral damage lateral walls when round bur technique is followed b) Soffit act as ferrule. But, some oppose the idea for the fact that it becomes

difficult to remove pulp, sealer and gutta percha that is retained under un-deroofed area.^[6]

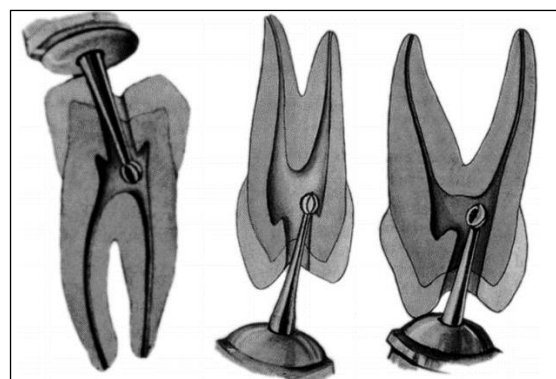


Figure 2: Texts frequently show the round bur technique relying on tactile feedback as the round bur drops into the chamber. From Ingle J Endodontics.

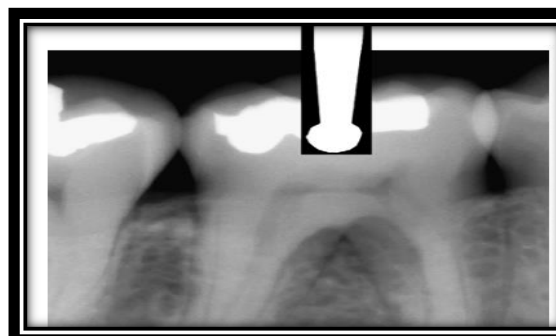
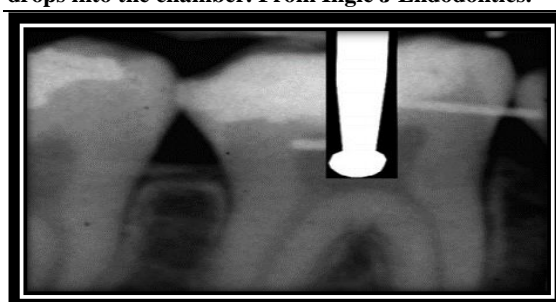


Figure 3: a) Pulp chamber is larger and hence a round bur can drop in to it, b) Trying to drop a round bur into a smaller chamber leads to unsuccessful outcome.^[6]

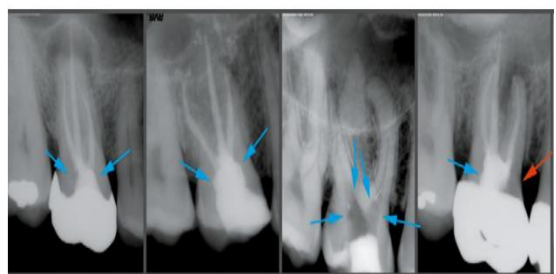

Figure 4: Applying round bur technique lead to gouging (blue arrows) and perforation (red arrow) as in the Figure.^[6]

With the advent of ultrasonics this is not a problem. Having discussed about the aggressive armamentarium and draw backs in the traditional design it is now important to overcome these draw

backs. The new vision-based mental model is Look, Groom, Follow is followed. For this rounded taper burs are preferred over round burs as shown in [Figure 5].



Figure 5: Comparison of the CK, designed by Drs Clark and Khademi endodontic access bur with the corresponding round bur. The tip size of these burs is less than half as wide as the corresponding round bur.^[6]

Conservative access for Maxillary Molar: Literature have made several attempts in determining the outline forms on restoration-free, caries-free teeth but failed to show outline forms on the decayed and restored teeth. The present review provides a guideline for accessing not only on sound tooth but also tooth with full coverage gold or porcelain restorative materials as shown in [Figure 6].

Stepped access which is intentional over-enlarged access is made in the initial phase through the cavosurface of a tooth/restored tooth till dentin is encountered. Restorative materials, occlusal tooth structure should be sacrificed before cervical tooth structure, which should remain as untouched as possible. Then, remaining access is continued based on the vision, drawing clue from the colour map and the presence of any Pulp Tissue Remnants (PTR). Extension of the cavity is not completely based on predetermined outline form but experience, magnification and case difficulty also governs the cavity con Figure ration. Entry into the pulp chamber need not be always perpendicular to the occlusal surface and need no overzealous extension on the distal or palatal sides. The entry path to gain access to MB and MB2 are generally from the distal, but can also be from the palatal as shown in [Figure 7]. In the area of the MB2 notching only the mesial wall with a BUC-1 ultrasonic tip, and, in restoration with LAxess nipple-tipped diamond.

The guiding principles and strategy on access and its extension should recognize the hierarchy of tooth needs listed in [Table 1].

Table 1: Hierarchy of tooth needs.^[6]

Restorative Case Type	Cavosurface Angle
Sound molar to be restored with bonded indirect onlay or composite onlay	1 mm of anatomic flattening (2 mm cusp tip flattening); then 45°angle of penetration until reaching the dentinal map
Sound molar planned for full crown	1.5 mm of anatomic flattening (2.5 mm cusp tip flattening); then 45°angle of penetration until reaching the dentin map
Mutilated molar planned for full crown	2–3 mm of flattening
Tooth with Gold crown	80° angle of penetration until reaching the dentin map
Tooth with PFM crown	45°angle of penetration through the crown until reaching the dentin map
Tooth with Zirconia based porcelain crown	70–90°angle of penetration until reaching the dentin ma

Final cavosurface outline depends on the current restoration, and the restoration to be used. If highly bondable substrate is used and the cavosurface should be Cala Lillied as in Figure 8. If the bond ability is low, a butt joint or 70 to 90 should be the considered as in [Figure 9].^[6]

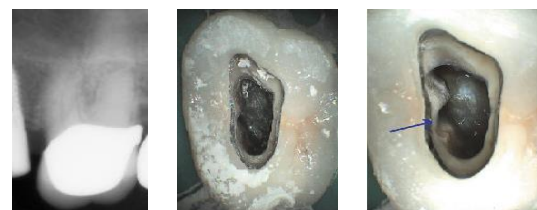

Figure 6: Access in tooth with PFM crown Figure 6.a Pre-operative view, 6.b.Slight fluting and 6.c. Closed fluting.^[6]

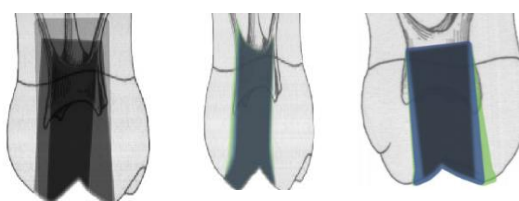


Figure 7: Access in unrestored tooth a. comparison of traditional and conservative access b & c shows buccal and mesial extensions.

Access for mandibular molar: Similar to maxillary molar access mentioned in earlier section.

Conservative access with the aid of CBCT: Roentgen's invention of the dental radiograph, is the critical necessity prior to treatment procedure but being 2D representation of 3D objects complete data can't be drawn from images. Advent of CBCT in to the field of dentistry has made diagnosis more precise. Not only it accurately gives information about the number of canals and its complex anatomy but can also be used as an efficient tool for guided access preparation.

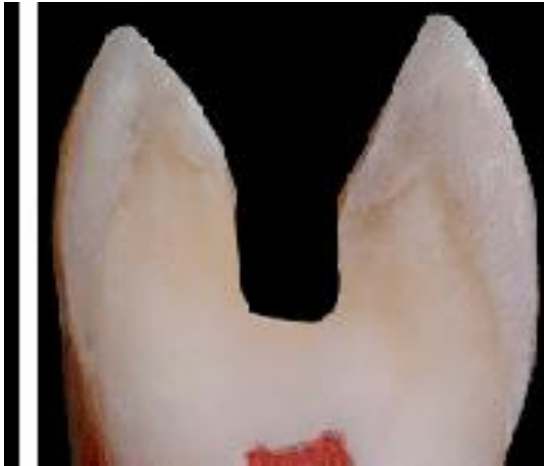

Figure 8: Calla Lilly enamel preparation.^[6]

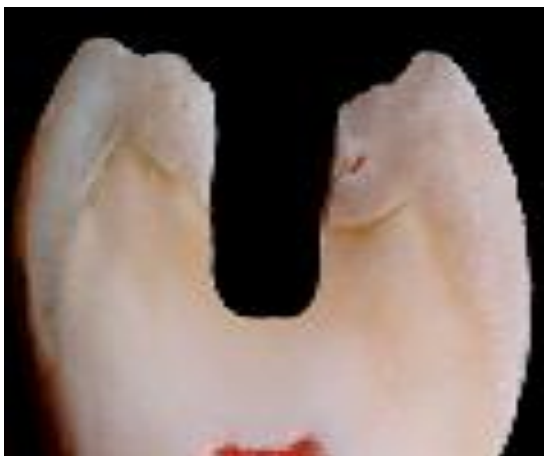

Figure 9: Traditional parallel walls.^[6]

This procedure has its highest significance in the cases where pulp space is partially or completely obliterated due to physiological or pathological reasons. Guided access is a conservative access preparation which limits the access to 3-4, 1mm small pea holes which are made by the aid of CBCT generated drill guides.

The procedure utilizes CBCT scan and an optical surface scan. Once the images are obtained they are matched. A virtual drill is designed and superimposed on the root canal in such an angular orientation so that the drill targets the apex. The above procedure is usually done utilizing software designed for implant placement. After establishing the desired drill pathway virtual template is designed utilizing template designer tool from the surface scan which will be used further to build a template using 3D printer. Computerized numerical control technology sleeve will be fabricated, which will be integrated into the printed template. The template thus fabricated is positioned on teeth to be treated to check for the fit. Before proceeding with the use of the drill a pilot access is created so as to provide the straight line access using diamond bur. The selected drill is used at 10000 RPM with pumping movements to penetrate through the

calcified part of the root canal to gain access to the apical region. The procedure is diagrammatically represented in [Figure10]. Being an innovative method it has its disadvantages like high radiation exposure, integration of CBCT and Surface scans and high cost involved in obtaining images and 3D printed template.⁷⁻¹⁰

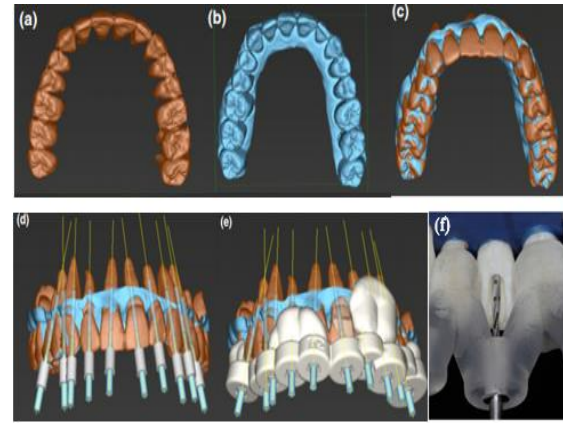


Figure 10 .Matching of CBCT and surface scans: (a) CBCT scan (b) Surface scan (c) Matched scans (d) Superimposition of virtual bur (e) Designed template including sleeves and burs (f) Bur was guided through the sleeve to gain access to the apical third of the root canal.⁹

CONCLUSION

Progress cannot see the light till change occurs. Traditional endodontic access which is based on principles that goes well with instruments and restorative materials available at that point of time, but with the advancements in materials and instruments sticking on traditional principles jeopardize the tooth structure. Hence shifting towards conservative access helps to obtain longstanding success of endodontically treated teeth.

REFERENCES

1. Tay FR, Pashley DH. Monoblocks in root canals: a hypothetical or a tangible goal. *J Endod* 2007;33(4):391–8.
2. Wahl MJ, Schmitt MM, Overton DA. Prevalence of cusp fractures in teeth restored with amalgam and with resin-based composite. *J Am Dent Assoc* 2004;135:1127–32.
3. Schwartz RS, Robbins JW. Post placement and restoration of endodontically treated teeth: a literature review. *J Endod* 2004;30(5):289–301.
4. Lirtchirakarn V. Patterns of vertical root fractures: factors affecting stress distribution in the root canal. *J Endod* 2003;29:523–8.
5. Tamse A. An evaluation of endodontically treated vertically fractured teeth. *J Endod* 1999;25:506–8.
6. Clark D, Khademi J. Modern molar endodontic access and directed dentin conservation. *Dent Clin North Am* 2010;54:249-273.

7. Buchanan S. Cutting endodontic access cavities for long term outcomes. *Endodontics* 2015;1:60-63.
8. Zehnder MS, Connert T, Weiger R, Krastl G, Kuhl S. Guided endodontics: accuracy of a novel method for guided access cavity preparation and root canal location. *Int Endod J* 2016;49:966-72.
9. Krastl G, Zehnder MS, Connert T, Weiger R, Kuhl S. Guided Endodontics: a novel treatment approach for teeth with pulp canal calcification and apical pathology. *Dent Traumatol* 2016;32:240-246.
10. Buchgreitz J, Buchgreitz M, Mortensen D, Bjorndal L. Guided access cavity preparation using cone-beam computed tomography and optical surface scans - an ex vivo study. *Int Endod J* 2016;49:790-5.

How to cite this article: Neha S, Nagamaheshwari X, Ravichandra C, Shekar K, Sindhura G, Smitha R. Minimum Access for Maximum Success. *Ann. Int. Med. Den. Res.* 2017; 3(4): DE01-DE05.

Source of Support: Nil, **Conflict of Interest:** None declared