

Compound Zygomatic Complex Fractures – A Case Series.

Sandhya K¹, Bobby John², Sobitha G³

¹Senior resident, Department of Oral and Maxillofacial Surgery, Government Dental College, Kottayam (corresponding author)

²Assistant Professor, Department of Oral and Maxillofacial Surgery, Government Dental College, Kottayam

³Junior resident, Department of Oral and Maxillofacial Surgery, Government Dental College, Kottayam.

Received: June 2017

Accepted: June 2017

Copyright: © the author(s), publisher. It is an open-access article distributed under the terms of the Creative Commons Attribution Non-Commercial License, which permits unrestricted non-commercial use, distribution, and reproduction in any medium, provided the original work is properly cited.

ABSTRACT

Zygomatic complex fractures are often difficult to manage due to the complex anatomy. Accompanying functional disturbances worsens the situation. A compound zygomatic complex fracture with extensive soft tissue injury is challenge to the operating surgeon. A case series including three compound zygomatic complex fractures are presented in the article.

Keywords: Fracture, Trauma, Zygomatic Fracture.

INTRODUCTION

Zygomatic complex is a complex interdigitation of multiple bones, the orbit, zygoma, facial and the sphenoid. Isolated facial bone fracture is thus usually rare in the zygomatic region. The fracture in these region occur along the lines of least strength, at the sutures. The sutures involved are zygomatico frontal suture, sphenoid, zygomatico temporal and the zygomatic buttress. The fractured complex is displaced downwards and outwards. The lateral width of the facial skeleton is maintained by the zygoma. Fracture in this region causes widening of the facial width. Surgical skill is required for a three dimensional reduction of the zygomatic complex and to restore pre-morbid facial contour.

Zygomatic complex fracture is associated with certain functional disturbances also along with the cosmetic problems. Visual disturbance such as diplopia, blurring of vision and difficulty in opening the mouth are also associated with such fractures. Early surgical intervention can yield good cosmetic results.

Extensive soft tissue injuries may also accompany the facial bone fractures. Debridement and wound closure must be given particular attention in the facial region. Ugly and bad scars are less tolerated in the facial region. The present article is on a case series of compound zygomatic complex fractures.

Name & Address of Corresponding Author

Dr Sandhya K
Kandath House
Anikode
Palakkad
Kerala,
India 678572

CASE SERIES

Case Report 1

A 25 year old male patient presented to our casualty department with a history of fall from height. Emergency care was provided and patient stabilized. Computed tomography was taken and head injury was ruled out. On detailed examination patient had compound zygomatic complex fracture with no associated injury. Vision was normal, except for a mild enophthalmos. Mouth opening was restricted. Ophthalmology consultation was done and globe injury was ruled out. Routine laboratory investigations were taken. After an immediate pre-anesthetic checkup patient was shifted to the emergency operation theatre. Patient was intubated through an oro endotracheal tube. [Figure 1] shows preoperative photograph.

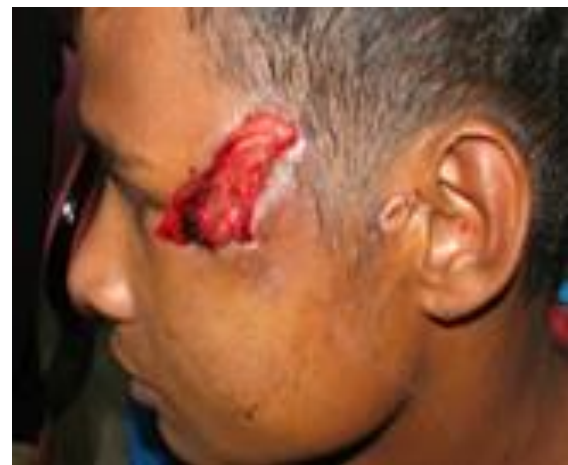

Figure 1: Showing preoperative photograph

Wound was debrided. Through the existing avulsive injury lateral orbital wall, zygomatic arch, infraorbital rim and floor of orbit was approachable. Fractures at all these sites were reduced and was fixed with 1.5mm stainless steel plates. The floor of orbit was comminuted, hence an orbital mesh was placed and fixed to the infraorbital rim. [Figure 2]

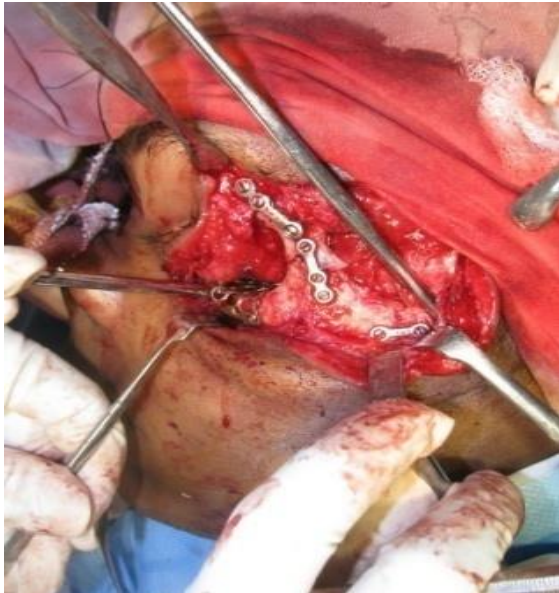

Figure 2: showing fracture fixation

Wound was closed in layers using 3-0 vicryl and 4-0 nylon. [Figure 3]

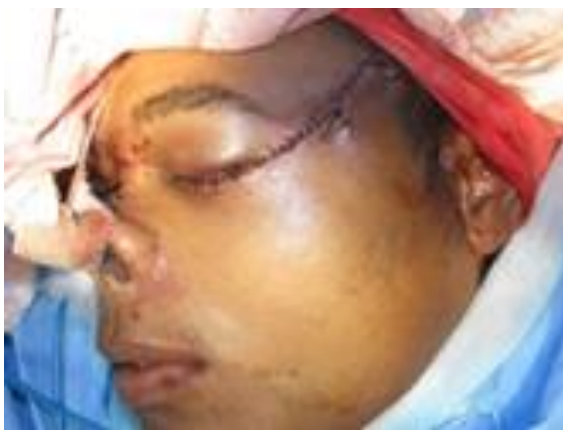

Figure 3: showing post-operative photograph

Post-operative period was uneventful. No cosmetic or functional disturbances were reported.

Case Report 2

A 38 year old male patient reported to our casualty with an alleged history of assault by a known person with an axe. Emergency care was provided and patient was stabilised. Computed tomography (CT) was taken which showed left zygomatico maxillary complex fracture, without any evidence of intracranial pathology. On detailed general examination patient had lacerated wound of 2.5*2

cm on the left upper eyelid involving the lid margin with disruption of the levator palpebrae muscle. Lacerated wound of size 4*2Cm was present on the left lower eyelid involving the lid margin. An irregular lacerated wound of size 7*4*3 cm was present in left forehead extending from the supra orbital ridge to the temporo parietal junction with exposed temporalis muscle. Left side globe was partially exposed. [Figure 4] shows preoperative photograph and [Figure 5] shows CT scan.

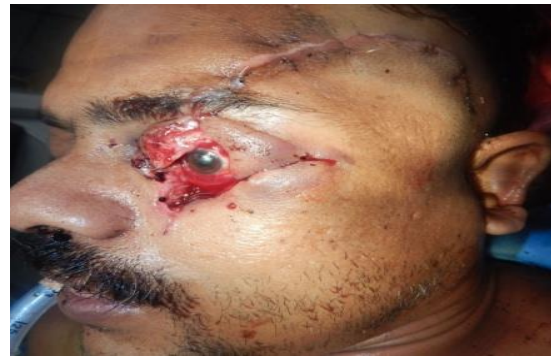

Figure 4: shows preoperative photograph.

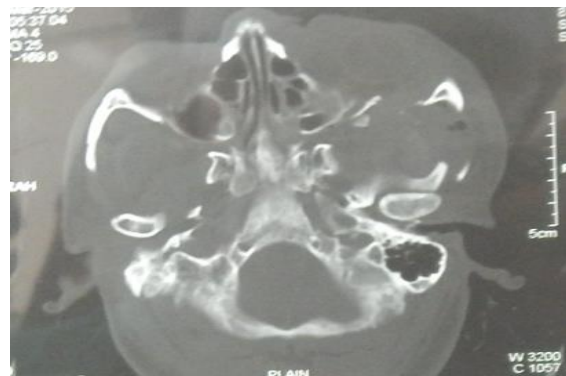

Figure 5: shows preoperative CT scan

Ophthalmology consultation was done and injury to globe and optic nerve also was ruled out. Inj.T.T 0.5 ml I/M stat and Inj.Tetglobe 250 IU I/M stat was administered. Routine antibiotics and analgesics were administered and the patient was transferred to emergency operation theatre. The wound was then debrided under general anaesthesia. Then the lateral orbital wall was exposed through the laceration and fracture segments identified [Figure 6].

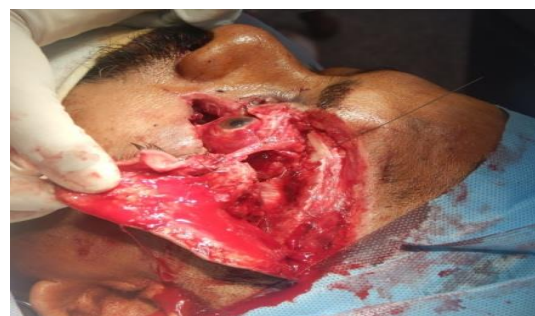

Figure 6: shows the exposed wound through the laceration and lateral orbital wall segments identified.

Lateral orbital wall was fixed with 2mm four hole orbital plate and 2*6 mm screws [Figure 7].

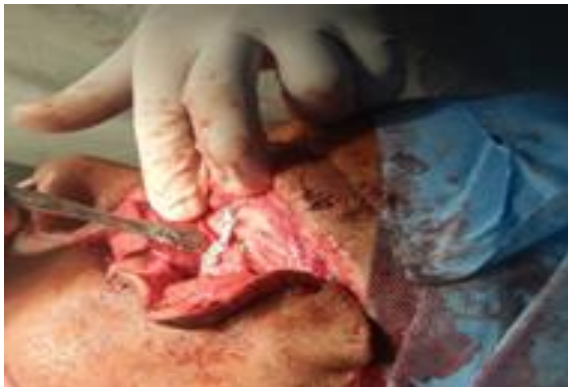

Figure 7: shows lateral orbital wall fixed with 2mm four hole orbital plate and 2*6 mm screws

The infraorbital wall was then exposed through laceration and the fracture segments identified and fixed with 2mm four hole orbital plate and 2*6 screws [Figure 8].

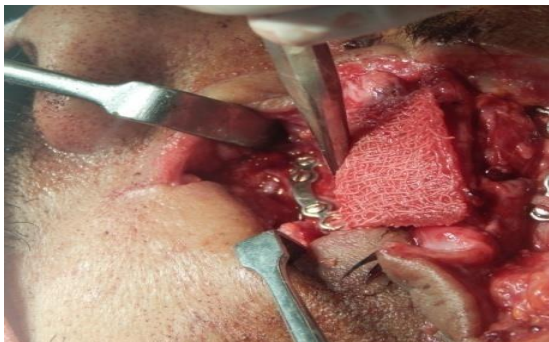

Figure 8: Shows infraorbital wall exposed and fixed with 2mm four hole orbital plate and 2*6 screws

The zygomatic buttress was exposed by introral incision and the fracture segments stabilized with 2mm L shaped four hole plate and 2*6 mm screws. The intra oral wound was then closed with 3-0 vicryl. Lateral canthotomy was done followed by medial advancement of lids. Wound was closed in triple layer. The eyelid skin was closed with 6-0 PDS and forehead skin closed with 4-0 nylon. Vertical mattress technique was used for closure as it will result in a better looking scar [Figure 9].

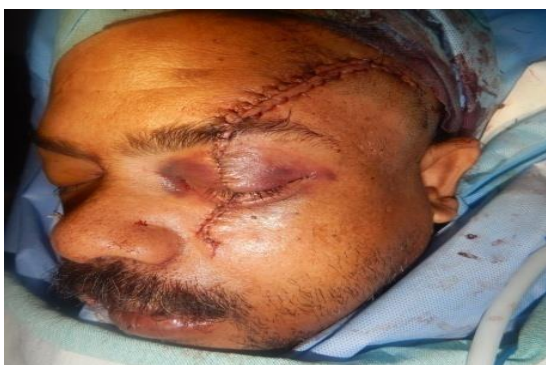

Figure 9: shows the sutured wound

The postoperative period was uneventful. Satisfactory results were obtained, except for the presence of lagophthalmos which occurred as a result of severe injury to levator palpebrae superioris [Figure 7]. There was no visual disturbance and eye movements were all within normal limits [Figure 10-14].

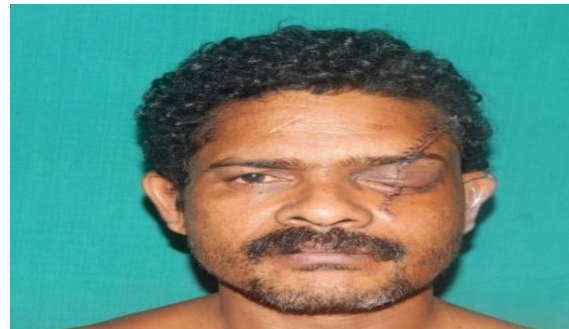

Figure 10: Showing persistent lagophthalmos

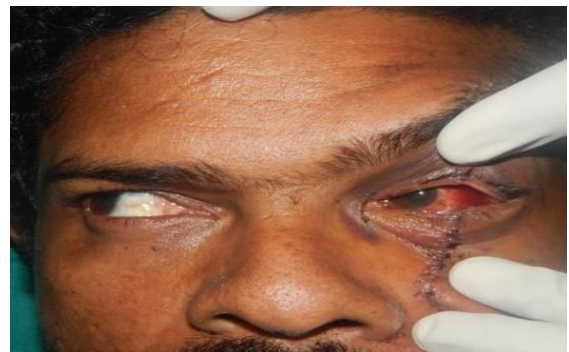

Figure 11: showing eye ball movement to right

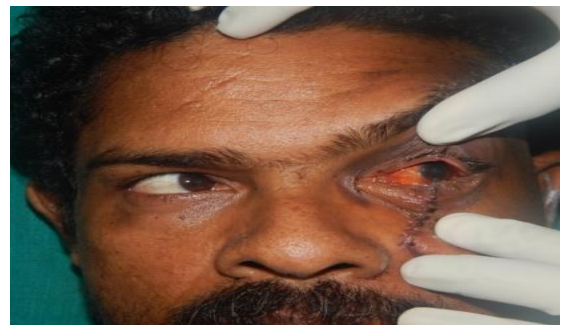

Figure 12: Showing eye ball movement to left

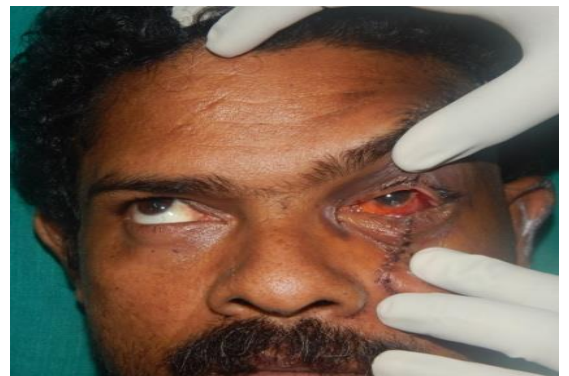

Figure 13: showing eye ball movement in upward direction.

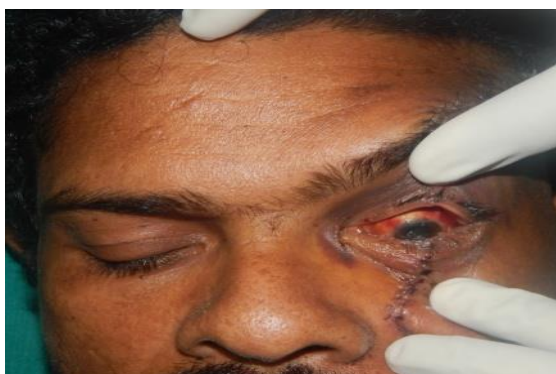

Figure 14: showing eye ball movement in downward direction.

Postoperative x-ray – paranasal sinus view was taken to evaluate the reduction [Figure 15].

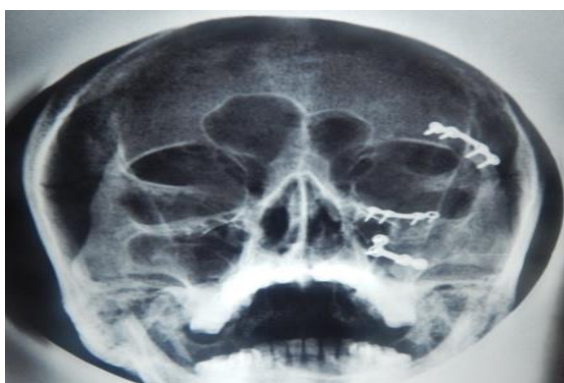


Figure 15: showing postoperative xray

CASE REPORT 3

A 39 year old male patient reported to our casualty department with an alleged history of road traffic accident. Emergency care was provided and patient stabilized. Computed tomography was taken. Patient had mild frontal contusion. Neurosurgery consultation was done and consent was obtained for immediate surgical intervention. Patient was shifted to emergency operation theatre after routine laboratory investigations and pre anesthetic check-up. Patient was intubated under general anesthesia. Wound was thoroughly debrided [Figure 16 and 17].

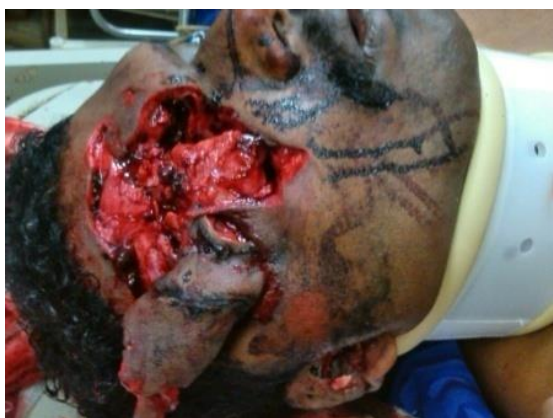

Figure 16: showing preoperative photograph

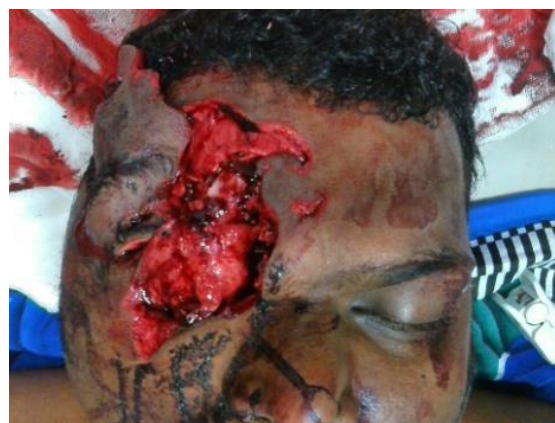

Figure 16: showing preoperative photograph

A three point fixation of zygomatic complex was done with 2mm stainless steel plates. Wound was closed in layers with 3-0 vicryl and 4-0 nylon. [Figure 17]

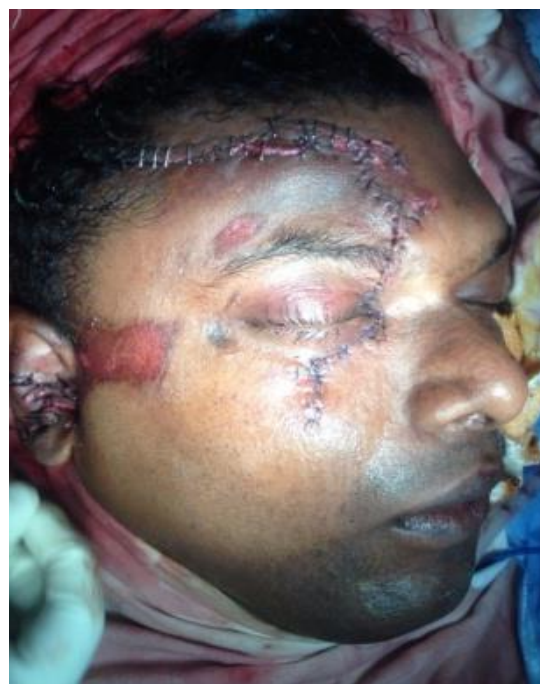

Figure 17: showing postoperative photograph.

DISCUSSION

The zygomatic complex forms the main support to the facial skeleton.^[1-3] An assault, road traffic accident or a fall from height predisposes to zygomatic complex fracture.^[4] The zygomatic complex fractures are associated with various complications such as alteration in facial contour, depression of malar prominence, visual disturbances and restriction in mouth opening.^[5-9] The presence of associated extensive facial injury complicates the scenario. In such situations soft tissue closure alone is not advisable. Proper closure is not possible unless a stable skeletal framework is present underneath.

Only one patient had mild frontal contusion. The presence of extensive facial injury is a blessing in disguise, concerned with head injury. All our three patients were lucky enough to escape severe head injury. Vision could be assessed only in one patient preoperatively. Ophthalmology consultation was done globe injury was ruled out in all the patients. Proper reduction of the zygomatic complex maintained vision normal in all the patients. Such extensive injuries give best results when operated at the earliest as done in this case. Proper anatomic reduction and good surgical skills give excellent result even in compound zygomatic complex fractures.

CONCLUSION

Early intervention, a three dimensional reduction of the zygomatic complex and a tripod or tetrapod fixation gives a stable skeletal framework. Cosmetic skin closure and proper function becomes possible only if a stable facial contour is obtained.

REFERENCES

1. Jansma J, Bos RR, Vissink A. Zygomatic fractures. Ned Tijdschr Tandheelkd. 1997;104:436-9. [PubMed]
2. Fasola AO, Obiechina AE, Arotiba JT. An audit of midfacial fractures in Ibadan, Nigeria. Afr J Med Med Sci. 2001;30:183-6. [PubMed]
3. Hollier LH, Thornton J, Pazmino P, Stal S. The management of orbitozygomatic fractures. Plast Reconstr Surg. 2003;111:2386-92. [PubMed]
4. Gomes PP, Passeri LA, Barbosa JR: A 5-year retrospective study of zygomatico-orbital complex and zygomatic arch fractures in Sao Paulo State, Brazil. J Oral Maxillofac Surg. 2006, 64 (1): 63-67. 10.1016/j.joms.2005.09.012.
5. Banks P, Brown A. 1st ed. Oxford: Wright; 2001. Fractures of the Facial Skeleton; pp. 40-155.
6. Jansma J, Bos RR, Vissink A. Zygomatic fractures. Ned Tijdschr Tandheelkd. 1997;104:436-9. [PubMed]
7. al-Qurainy IA, Stassen LF, Dutton GN, Moos KF, el-Attar A. Diplopia following midfacial fractures. Br J Oral Maxillofac Surg. 1991;29:302-7. [PubMed]
8. Nam IW. Clinical studies on treatment of fractures of the zygomatic bone. Taehan Chikkwa Uisa Hyophoe Chi. 1990;28:563-70. [PubMed]
9. Zachariades N, Papavassiliou D, Christopoulos P. Blindness after facial trauma. Oral Surg Oral Med Oral Pathol Oral Radiol Endod. 1996;81:34-7. [PubMed]
10. Ceallaigh PO, et al: Diagnosis and management of common maxillofacial injuries in the emergency department. Part 1: advanced trauma life support. Emerg Med J. 2006, 23 (10): 796-797. 10.1136/emj.2006.035931.
11. Banks P, Brown A. 1st ed. Oxford: Wright; 2001. Fractures of the Facial Skeleton; pp. 40-155.

How to cite this article: Sandhya K, John B, Sobitha G. Compound Zygomatic Complex Fractures – A Case Series.. Ann. Int. Med. Den. Res. 2017; 3(5):DE01-DE05.

Source of Support: Nil, **Conflict of Interest:** None declared