

## Giant Cell Lesions Of Jaws - A Five Year Study.

Tajamul Hakim<sup>1</sup>, Shahid Farooq<sup>2</sup>, Ajaz A Shah<sup>3</sup>, Nazish Khan<sup>4</sup>, Nida Lankar<sup>5</sup>, Naira Shafat<sup>6</sup>, Aaliya Rashid<sup>7</sup>, Uzma Farooq<sup>8</sup>

<sup>1,2</sup>Postgraduate, Oral & Maxillofacial Surgery, GDC Srinagar, J&K.

<sup>3</sup>Professor & Head, Postgraduate Department of Oral & Maxillofacial Surgery, GDC Srinagar, J&K.

<sup>4,5</sup>Junior Resident, Postgraduate Department of Oral & Maxillofacial Surgery, GDC Srinagar, J&K.

<sup>6,7,8</sup> BDS.

Received: September 2017

Accepted: September 2017

**Copyright:** © the author(s), publisher. It is an open-access article distributed under the terms of the Creative Commons Attribution Non-Commercial License, which permits unrestricted non-commercial use, distribution, and reproduction in any medium, provided the original work is properly cited.

### ABSTRACT

**Background:** Objectives: Giant cell lesions of the jaws are common pathologies in maxillofacial region but there are a few studies on these lesions. Hence, this study was designed to provide a demographic data on giant cell lesions reported from our institute Govt. Dental college & hospital Srinagar J&K. A retrospective analysis giant cell lesions of jaws reported in our institute between the years 2011 and 2016 was done and this data was compared with previous reports from different parts of the world and India. **Methods:** Biopsies of the lesions received between the years 2011 and 2016 were reviewed and patient's history, clinical, radiological and histopathological characteristics were analyzed. **Results:** A total of 84 lesions were received during the 5 year study period. These lesions were more frequently seen in the males, in a younger age group and showed a predilection for the mandible. Most of them presented as radiolucent, slow growing and painless lesions. Giant cell granulomas (72.6%) constituted the majority of these giant cell lesions. **Conclusion:** These lesions showed a definite geographic variation

**Keywords:** Jaw, Giant Cell Lesion.

### INTRODUCTION

Giant cell lesions of the jaws are benign, tumor-like lesions affecting the jaws but also occurring in other bones and soft tissues. Their biologic behavior in the jaws is identical to that in the long bones and is unrelated to patient's age and size of the lesion.<sup>[1]</sup> They consist of multinucleated giant cells in a background of fibrous connective tissue with abundant spindle-shaped mononucleated cells.<sup>[2]</sup> Till date several retrospective studies have been carried out in different parts of the world which show a definite geographic variation in the relative frequency, site and histologic type of these lesions. Although a large number of studies from India demonstrate the frequency of the various odontogenic tumors, reports on giant cell lesions are however very scarce. Hence, the present 5 years retrospective study was conducted to analyze the frequency, clinical presentation, site and character of the giant cell lesions reported in our institute. The aims of our present study were to retrospectively analyze these varied lesions clinico-

pathologically and to compare this data with the data from different studies.

### MATERIALS AND METHODS

A retrospective study was performed on 84 patients with jaw lesions between the years 2011 and 2016. Data was retrieved from case notes, radiographs and histopathology results reported in the department of Pathology Govt. Medical College Srinagar. Patient's history, clinical findings, radiological and histopathological characteristics were analyzed. Hematoxylin and eosin (H&E) stain was used on sections of buffered formalin fixed tissues.

### RESULTS

These lesions were detected in both sexes, with males comprising 45.2% (N = 38) of all the 84 patients seen and the rest 54.8% (N = 46) being females [Table 1]. The male: female ratio was 0.82. The mean age of patients at the time of presentation was 34 years with most being in the age group of 26 to 38 years [Table 2]. Seventy four (88%) out of the 84 tumors were encountered in the mandible with the overall mandible: maxilla ratio being 5:1. Among the giant cell lesions, central giant cell granulomas constituted 72.6% of all the jaw lesions followed by aneurysmal bone cyst (21.4%). Sixty-

#### Name & Address of Corresponding Author

Dr. Tajamul Hakim  
Department of oral pathology,  
Govt. dental college & hospital  
Srinagar, J&K.

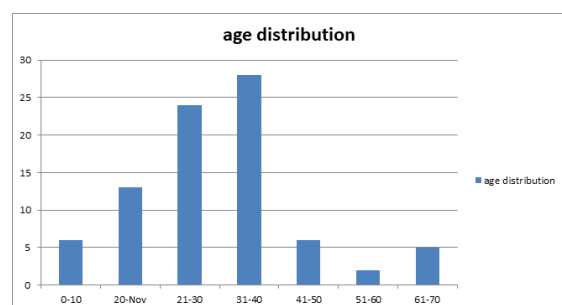
five patients presented with a swelling in one of the jaw bones. Majority of these jaw swellings presented with a slow growth while rapid growth was observed in 9 cases. The swellings were associated with pain in 8 cases while the history of pain in the remaining cases was unavailable in our study. Radiologically out of the 84 jaw lesions, majority were radiolucent lesions. Radiological findings of the remaining 10 cases were unavailable for study. Most of the radiolucent lesions were multilocular.

**Table 1: Gender Distribution**

Gender	Number	%age
Male	38	45.2
Female	46	54.8

**Table 2: Age Distribution**

Age(Years)	No. Of Patients
0-10	6
11-20	13
21-30	24
31-40	28
41-50	6
51-60	2
61-70	5



**Figure 1:**

**Table 3: Different Giant Cell Lesions**

Giant Cell Lesion	No. Of Patients	%Age
Central Giant Cell Granuloma	61	72.6
Aneurysmal Bone Cyst	18	21.4
Cherubism	5	5.95

## DISCUSSION

The aim of our present study was to retrospectively analyze giant cell lesions clinicopathologically and to compare our data with other studies. Till date most of the studies reported on these lesions are mostly from America, Europe and Africa. Very few studies have been reported from Asia, especially from the Indian subcontinent. While the giant cell lesions of the jaws are benign, tumor-like lesions affecting the jaws but also occurring in other bones and soft tissues. Majority of these lesions are located in the mandible.<sup>[3-7]</sup> Stypulkowska has reported a female preponderance (55.5%) of these lesions in his study which is in accordance to the previous studies.<sup>[8]</sup> The mean age of the patients in

his study was however 34 years. In our study, these lesions were found to be more common in females (54.8%) than in males (45.2%) which is in accordance with the mean age of 32.5 years reported by Stypulkowska, including the studies from Ghana.<sup>[6,7]</sup> In addition, a few studies conducted in Nigeria have similarly reported a similar incidence of these lesions in both adults and children and mandible was the commonest jaw bone involved.<sup>[9,10]</sup> Most of these jaw lesions present with swelling, pain and ulceration.<sup>[7]</sup> In our study too most of these lesions commonly presented as slow-growing swellings. However, unlike the previous reports most were painless growths. Pain was observed in only 8 cases with none being ulcerated. Radiologically, most of these jaw lesions appeared as well-defined, multilocular, radiolucent lesions.<sup>[11]</sup> Our study too demonstrated majority of these jaw lesions as radiolucent. Table 3 demonstrates the frequency of distribution of the different giant cell lesions of the jaws encountered in our study. Central giant cell granuloma appears to be lesion that is unique to the jaws. It was formerly regarded as reparative process and was accordingly called central giant cell reparative granuloma.<sup>[12]</sup> It is by far the most common of giant cell lesions of jaws and a history of trauma can often be ascertained.<sup>[13]</sup> It typically occurs more in females in the 2nd and the 3rd decades of life Mandible has been reported as more common jaw bone affected by this lesion. Similar to the above studies, this lesion was the commonest of the 7 giant cell lesions reported in our study with a younger age of presentation and females outnumbering males. Mandible was the commonly involved bone. Two cases of central giant cell granulomas have been reported in the Indian literature who were however both males aged 10 and 27 years.<sup>[14-16]</sup> One presented with the lesion in mandible and the other in the maxilla. Radiologically, most of these lesions initially present as unilocular lesions which eventually become multilocular as they develop [Figure 1]. Microscopically, it shows a large number of multinucleated giant cells, rather multilocular vascular stroma and often new bone formation as demonstrated.<sup>[13]</sup> 21.4% of the lesions were aneurysmal bone cysts and 5.95% were cherubism.

## CONCLUSION

In our present study, an attempt has been made to study the incidence of various giant cell lesions of the jaws reported in our institute and to compare the results with reports from other parts of the world. Based on Indian literature survey to date we are herewith reporting for the first time a study of this nature from our region as it was observed that only few case studies have been reported in the Indian context.. Males are the more commonly

affected gender than females and the age incidence peaked in the second decade of life, the cause of which probably could be related to the life style. Radiology is seen to play an important role in the diagnosis of these lesions. Majority of the lesions had a predilection for the mandible and were multilocular radiolucent swellings. Clinically the majority presented as slow growing painless lumps indicating a benign nature of these lesions. Central giant cell granuloma was the most commonly encountered lesion in the giant cell category. The incidence of other tumors in our study was almost similar to those from other parts of the world.

## REFERENCES

1. Saban L, Abdullah ALQ, Ahmed ALY: Giant cell lesions: Concept controversy and clinical presentations. Saudi Dental J 2006, 18, (SI)- Abstr.098.
2. Lange D J, Maarle VMC, Akker VHP, Redekar EJ: A new mutation in the SH3BP2 gene showing reduced penetrance in a family affected with cherubism. Oral Surg Oral Med Oral Pathol Oral Radiol Endod 2007, 103:378-381.
3. Srimm G, Shetty RP: Odontogenic tumors: A study of 250 cases in an Indian teaching hospital. Oral Surg Oral Med Oral Pathol Oral Radiol Endod 2008, 105(6):214-221.
4. Gupta B, Ponniah I: The pattern of odontogenic tumors in a government teaching hospital in the southern Indian state of Tamil Nadu. Oral Surg Oral Med Oral Pathol Oral Radiol Endod 2010, 110(1):e32-39.
5. Varkhede A, Tupkari JV, Mandale MS, Sardar M: Odontogenic tumors: a review of 60 cases. J Clin Exp Dent 2010, 2(40):e183-186.
6. Parkins GE, Armah GA, Tettey Y: Orofacial tumours and tumour-like lesions in Ghana: a 6 year prospective study. Br J Oral Maxillo fac Surg 2009, 47(7):550-4.
7. Parkins GE, Armah GA, Ampofo P: Tumours and tumour-like lesions of the lower face at Korle Bu Teaching hospital, Ghana-an eight year study. World J Surg Oncol 2007, 5:48.
8. Stypulkowska J: Odontogenic tumors and neoplastic-like changes of the jaw bones. Clinical study and evaluation of treatment results. Folia Med Cracov 1998, 39(1-2):35-141.
9. Ajayi OF, Ladeinde AL, Adeyemo WL, Ogunlewe MO: Odontogenic tumors in Nigerian children and adolescents-a retrospective study of 92 cases. World J Surg Oncol 2004, 2:39-48.
10. Adebayo ET, Ajike SO, Adekeye EO: Tumors and tumor-like lesions of the oral and perioral structures of Nigerian children. Int J Oral Maxillofac Surg 2001, 30:205-208.
11. Scholl RJ, Kellett HM, Neuman DP, Lurie AG: Cysts and cystic lesions of the Mandible-Clinical, Radiologic and Histopathologic Review. Radiographics 1999, 19:1107-1124.
12. Whitaker SB, Waldron CA: Central giant cell lesions of the jaws. Oral Surg Oral Med Oral Patho 1993, 75:199-208.
13. Rosai J: Mandible and Maxilla. In Rosai and Ackerman's Surgical Pathology Volume1. 9 edition. Edited by: Juan rosai. St. Louis: Mosby; 2004:279-304.
14. Hegde RJ: Central giant cell granuloma in child: a case report. J Indian Soc Ped Prev Dent 2004, 22(3):106-108.
15. Sholapurkar AA, Keerthilatha MP, Ahsan A: Central giant cell granuloma of the anterior maxilla. Indian J of Dent Res 2008, 19(1):78-82.
16. Surekha Venkata Mullapudi\*, Uday Kumar Putcha and Sesikeran Boindala: Odontogenic tumors and giant cell lesions of jaws - a nine year study. World Journal of Surgical Oncology 2011, 9:68.

**How to cite this article:** Hakim T, Farooq S, Shah AA, Khan N, Lankar N, Shafat N, Rashid A, Farooq U. Giant Cell Lesions Of Jaws - A Five Year Study. Ann. Int. Med. Den. Res. 2017; 3(6):DE53-DE55.

**Source of Support:** Nil, **Conflict of Interest:** None declared