

A Prospective Observational Study to Assess the Efficacy of Thoracic Epidural Anaesthesia for Mastectomy.

Prabhakaran Vineetha¹, Konnanath Thekkethil Ramadas², Binu Sajid³, Kannammadathy Poulose Biji¹

¹Assistant Professor, Dept. of Anaesthesiology, Govt. Medical College, Kozhikode.

²Former Professor & Head of Department, Dept. of Anaesthesiology, Govt. Medical College, Kozhikode.

³Associate Professor, Dept. of Anaesthesiology, Govt. Medical College, Kozhikode.

Received: February 2017

Accepted: February 2017

Copyright: © the author(s), publisher. It is an open-access article distributed under the terms of the Creative Commons Attribution Non-Commercial License, which permits unrestricted non-commercial use, distribution, and reproduction in any medium, provided the original work is properly cited.

ABSTRACT

Background: We conducted a prospective observational study to find out the effectiveness, complications and technical difficulties of thoracic epidural anaesthesia for modified radical mastectomy. **Methods:** Fifty patients of American society of anaesthesiologists' physical status one or two and age 25-65 years were given thoracic epidural anaesthesia at T₅-T₆ or T₆-T₇ level with 10-16ml of 0.25%Bupivacaine by a qualified anaesthesiologist. Supplementary anaesthesia of axilla, if needed was given with local infiltration of 5-10ml of 1% lignocaine with adrenaline. Postoperative analgesia was given with continuous infusion of 5ml/hr of 0.125%bupivacaine for twenty four hours. Adequacy of surgical anaesthesia and postoperative analgesia, changes in heart rate, blood pressure and respiration, need of supplemental analgesia, other complications, patient acceptance and technical difficulties were noted. Statistical constants like arithmetic mean, standard deviation and percentages were used to interpret results. **Results:** Five cases were excluded from the study as epidural space couldn't be identified. Surgical anaesthesia was adequate for the rest 45patients (100%). Among these, 5 cases (11%) had axillary sparing who were managed effectively with local infiltration. No major hemodynamic or respiratory complications occurred. Postoperative analgesia was excellent in 98% patients and patient satisfaction was 95.6 %. **Conclusion:** Thoracic epidural anaesthesia with 0.25%bupivacaine is effective for modified radical mastectomy along with supplemental analgesia of axilla if needed. Intraoperative and postoperative hemodynamic alterations are minimal. Postoperative continuous infusion with 0.125%bupivacaine provides excellent analgesia.

Keywords: mastectomy, thoracic epidural, analgesia.

INTRODUCTION

Breast cancer being the most common malignancy in women, modified radical mastectomy is now frequently performed. General anaesthesia provided conventionally for mastectomy is associated with pain, stress response, nausea, vomiting etc. Various regional techniques like local infiltration, intercostal block, paravertebral block, brachial plexus block, spinal anaesthesia, cervical epidural and thoracic epidural have been tried.^[1-5] We selected thoracic epidural based on clinical evidence from various studies of the effectiveness of it and the lower incidence of complications.^[6-10] This familiar technique is associated with lower incidence and severity of perioperative physiologic disruptions. It selectively blocks cardiac sympathetic fibres and thus attenuates surgical stress response, improves myocardial oxygen balance and stabilizes intraoperative hemodynamics.^[11] Also it offers significant preventive analgesic effect.^[12] Postoperative analgesia can also be provided through the epidural catheter.^[13,14]

We conducted a prospective study to assess the effectiveness of thoracic epidural block for surgical anaesthesia in patients undergoing modified radical mastectomy. Intra operative hemodynamic changes, other complications, patient and surgeon satisfaction and adequacy of postoperative analgesia were studied.

Name & Address of Corresponding Author

Dr. Vineetha. P,
Madathilthodi (H), Mankada P.O,
Malappuram,
Kerala, India – 680003.

MATERIALS AND METHODS

This prospective observational case study was conducted after approval from institutional ethics committee. Informed written consent was obtained from 50 female patients of American society of Anaesthesiologists' (ASA) physical status one or two, aged 25-65 years scheduled for elective oncologic breast surgery. Exclusion criteria were

patient refusal, difficult airway and contraindications to epidural block.

Patients were advised fasting as per ASA guidelines, tab. lorazepam 1mg on night before surgery and aspiration prophylaxis. On arrival in the operating room ASA standard monitors were attached and baseline vitals recorded. A peripheral intravenous access was established with 18G cannula and ringer lactate infusion started. Patients were then premedicated with inj. glycopyrrolate 0.2mg, inj.morphine 0.1-0.15mg/kg and inj.midazolam 0.01mg/kg intravenously. Oxygen was administered through facemask.

Thoracic epidural block was performed by a qualified anaesthesiologist under strict aseptic precautions with patient in lateral position with side of surgery in dependant position. Under local anaesthesia 18G Tuohy needle was inserted at T₅-T₆ or T₆-T₇ level and epidural space identified by loss of resistance technique. An 18G epidural catheter was inserted three centimetres into epidural space. A test dose of 3ml 2% lignocaine with one in two lakh adrenaline was given after aspiration to exclude intravenous or intrathecal placement and catheter secured.

After confirming the test as negative, two boluses of five ml 0.25% bupivacaine were given at ten minute interval. Anaesthetic dermatomal levels were determined by pinprick every two minutes and subsequent boluses of two ml were given till T₂-T₇ block was obtained. Then patient was placed supine and continuous infusion started with 5ml/hr of 0.25% bupivacaine. In those patients in whom axillary dissection needed supplemental analgesia, surgeon did a local infiltration of the area with 5-10ml of 1% lignocaine. Patients were converted to general anaesthesia if catheter placement was impossible at two vertebral levels. Procedure was considered as failure if targeted dermatomal levels were not attained even after 20ml of bupivacaine epidurally. Changes in blood pressure-hypertension or hypotension ($\pm 30\%$ deviation from baseline for normal patients and $\pm 25\%$ for hypertensives), changes in heart rate- tachycardia (>100) or bradycardia (<60), changes in respiratory rate and saturation were noted every two minutes for initial 20 minutes and every five minutes thereafter. In recovery room, vitals were monitored every 10 minutes for two hours. Then patient was monitored in the postoperative unit. Pain was assessed every 15 minutes for the first 24 postoperative hours. Pain relief was rated by verbal scoring – no pain, mild pain, moderate pain and severe pain. Postoperative pain was controlled with continuous infusion of 5ml/hr of 0.125% bupivacaine for eight hours. If mild to moderate pain, a bolus of two ml 0.25% bupivacaine was given. Inj.diclofenac 75mg intravenously was given as rescue analgesic if patient is not relieved by epidural bolus or has severe pain. Incidence of nausea, vomiting, dizziness and

shivering were noted. Shivering was controlled with inj. tramadol 0.5mg/kg intravenously and nausea with Inj. Ondansetron 0.1mg/kg. Technical difficulties, patient and surgeon acceptance and failure rate were also noted. The statistical constants like arithmetic mean, standard deviation and percentage were computed to interpret the data collected.

RESULTS

Of the 50 cases selected, in five cases we couldn't identify the epidural space. These were obese patients. They were excluded from the study. The rest 45 cases could be successfully completed under thoracic epidural block. The data of 45 patients were collected, tabulated and analysed. Statistical constants like arithmetic mean, standard deviation and percentage were computed to get inferences. Five cases with axillary sparing were effectively managed with local infiltration of the area. Postoperative analgesia was excellent in 98 % patients. One patient complained of mild postoperative pain one hour after surgery. She was relieved by a single dose of epidural bolus. None of the patients needed rescue analgesic.

Average time to attain T₂-T₇ level was 21.5 ± 4.9 minutes and average dose 11.95 ± 1.62 ml. Upper level of blockade attained was T₁ in 21 patients, C₈ in 20 patients and T₂ in four patients. Lower level was T₈ in 18 patients, T₁₀ in 14 patients and T₁₂ in four patients.

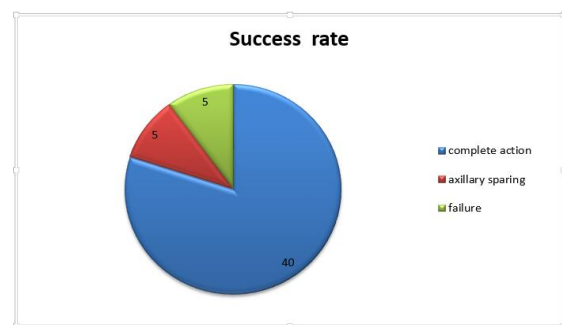


Figure 1: Success Rate.

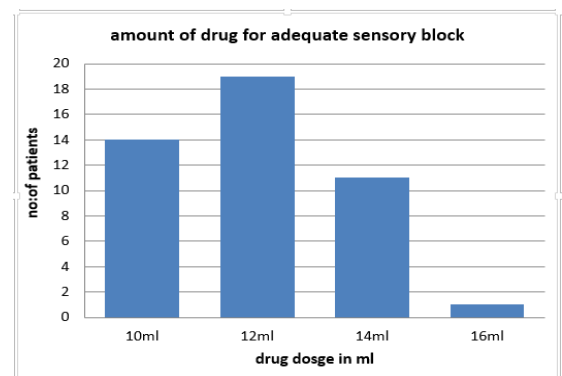


Figure 2: Amount of Drug for Adequate Sensory Block.

Of the 45 cases, 12 cases (24%) had hypotension intraoperatively and two cases (4.4%) postoperatively. Four (8.8%) patients had single episode bradycardia in the intraoperative period which was effectively treated with inj. atropine. Two (4.4%) patients found this technique unsatisfactory due to discomfort of muscle contraction while using cautery. All surgeons were comfortable with this technique.

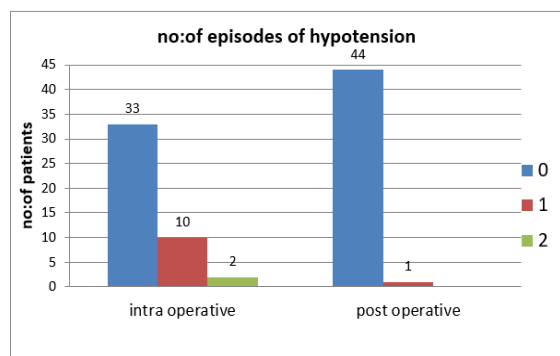


Figure 3: Number of Episodes of Hypotension.

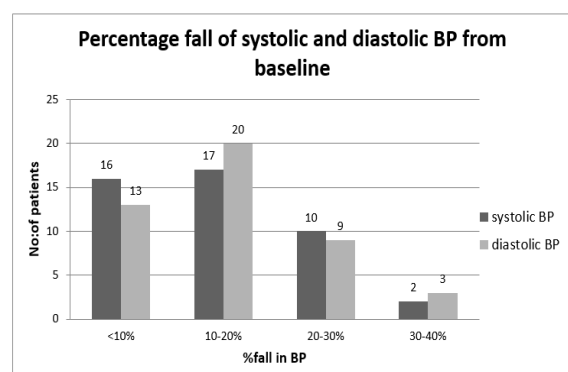


Figure 4: Percentage fall of Systolic/Diastolic Blood Pressure from Baseline.

DISCUSSION

We have attempted to study the feasibility of mastectomy under thoracic epidural anaesthesia. Thoracic epidural anaesthesia at T₅-T₆ or T₆-T₇ level with 0.25% bupivacaine provided adequate surgical anaesthesia for all patients in our study with 95.6% patient satisfaction and lower incidence of complications. Various forms of regional anaesthesia have been tried instead of conventional general anaesthesia for breast surgeries. [1-5] Thoracic epidural anaesthesia has been found effective in various studies. [6-10] Balzarena et al. found its advantages over general anaesthesia with greater satisfaction and earlier discharge. [6] Clinical benefits associated with epidural anaesthesia and analgesia is achieved with the thoracic approach, particularly with the appropriate use of local anaesthetics. These include an effective postoperative analgesia, lower incidence of pulmonary complications, stabilization of endothelial coronary function, earlier return of

bowel function, preservation of immune-competence, early ambulation and a reduction in the cost of perioperative care. It is even reported to have improved hemodynamic stability. It also blocks stress response of surgery and provides excellent postoperative analgesia. Chance of deep vein thrombosis is also less as venous return is preserved. It is also suitable for patients with chronic broncho pulmonary diseases since ventilation is not impeded further. [11] For effective ablation of pain response in breast surgery, it is necessary to block sensory nerves from T₂-T₇ dermatomes. We attained C₈-T₈ blockade in majority patients. One problem we encountered was inadequate analgesia in axilla which is due to the dual innervations of this area. Lower cervical roots innervate the axilla along with second thoracic root. However, when dissection involves medial and behind the pectoralis minor up to 4th cervical root is involved. Belzarena et al. found that infiltration of local anaesthetic 3-5ml in axilla was needed in 15% patients with complimentary sedation in 100% patients despite high level of blockade. [6] In our study 5 patients (11.1%) had axillary sparing, who were managed with local infiltration of axilla with 5-10ml of 1% lignocaine with adrenaline one in two lakh.

Petchara Sundarathiti et al. combined thoracic epidural anaesthesia with ipsilateral brachial plexus block with 0.2% ropivacaine for modified radical mastectomy. [7] They found it very effective in 100% patients with no axillary sparing. It provided better satisfaction and analgesia than general anaesthesia and similar surgical conditions. The main apprehensions regarding regular use of thoracic epidural are technical difficulty and spinal cord injury. Midthoracic spines have deep angulations, with epidural space width about 3-3.5mm. Hence needle angulation at 40° makes 6mm available for space identification. This together with less force applied at 40° and double thickness of dura at midthoracic region compared to lumbar helps prevent accidental dural puncture. Brull et al. reported the incidence of permanent neurological sequelae related to thoracic epidural <0.07%. [14] Sun Young Park et al. studied the incidence of Horner's syndrome with high thoracic epidural block by selecting 450 patients undergoing breast surgeries. [8] Only two patients (0.6%) had dural puncture and six patients (1.6%) had Horner's syndrome. No cases of dural puncture, Horner's syndrome or other neurological complications occurred in our patients. We had difficulty in identifying the space in five patients who were obese and were converted to general anaesthesia. We have selected T₅-T₆ or T₆-T₇ space as they are more accessible. Balzarena et al. and Sundarathiti et al. selected T₄-T₅ space and Sun Young Park et al. selected T₃-T₄/T₄-T₅ space. [6-8] As breast surgery does not need muscle relaxation 0.25% bupivacaine was used. It has an acceptable onset time, long duration of action, profound

conduction blockade and significant separation of sensory and motor blockade. It provides safe, effective and hemodynamically stable analgesia. Ten to fifteen ml of local anaesthetic was used in various studies for effective anaesthesia. We needed an average of 11.95 ± 1.62 ml of 0.25% bupivacaine in addition to volume of test dose with a mean onset time of 12.62 ± 3.9 minutes. Postoperatively continuous infusion with 0.125% bupivacaine at 5ml/hr was found to be sufficient in 98% patients. One patient had mild postoperative pain one hour after surgery, which was relieved with epidural bolus of 2ml 0.25% bupivacaine. Hemodynamic changes were hypotension in 24% cases and bradycardia in 8.8% cases. Hypotension could be easily managed with intravenous fluids and inj. mephentermine and bradycardia with atropine within a couple of minutes like other studies. Ten patients (20%) had single episode hypotension and 2 patients (4%) two episodes. It was treated with 100ml normal saline bolus and inj. mephentermine 6mg. Fluctuations may be mild due to segmental blockade, lower concentration and dose of local anaesthetic and preserved venous return. Even with near total sympathectomy only 15-18% changes in peripheral resistance occur if patient is normovolemic. Only two patients (4.4%) had a single episode hypotension in the postoperative period. Balzarena et al. had an incidence of hypotension in 60% cases and bradycardia in 15%.^[6] Sundarathiti et al. found no difference in the incidence of hypotension and bradycardia between general anaesthesia and thoracic epidural groups.^[7] Hypertension occurred with general anaesthesia group only. In our study no case of hypertension was there.

Yun-song Pan et al. had found that the preventive analgesic effect of epidural anaesthesia provided a better and prolonged postoperative analgesia with less opioid consumption.^[12] The spinal nociceptive neurons anesthetized prior to surgical incision prevent surgical stress response. Furthermore, this may reduce the phantom breast sensation and pain.^[15] But we have not studied this aspect. Incidence of nausea and vomiting was 2% intraoperatively and 4.4% postoperatively which was effectively managed with inj. ondansetron 4mg. Young Hee Baek et al. compared postoperative pain, nausea and vomiting between general anaesthesia and thoracic anaesthesia in patients undergoing mastectomy and found a very lower incidence in thoracic epidural group.^[16] Shivering was seen in six cases intraoperatively which was treated with inj. tramadol 0.5mg/kg and was relieved. Pruritis was another problem encountered in studies which used fentanyl as epidural adjuvant.^[13] We did not use any epidural adjuvant and had no case of pruritis. Several studies have found the advantages of thoracic epidural anaesthesia over general anaesthesia for oncologic breast surgeries. General anaesthesia may reduce the functional residual

capacity especially in pre-existing pulmonary disease, upper abdominal and thoracic incisions, advanced age and obesity. In contrast, thoracic epidural has minimal effect on pulmonary function especially with use of lower concentration of local anaesthetic and block level below C₄. Respiratory depression occurred in none of our patients intraoperatively or postoperatively. 96% patients found this technique acceptable. Two patients had discomfort due to muscle contraction while using cautery. All surgeons were comfortable with the technique. The experience with high thoracic epidural is limited. Our results may not be conclusive, although we did find that thoracic epidural anaesthesia with complimentary sedation can provide adequate surgical anaesthesia with low incidence of cardiovascular, pulmonary or neurologic complications. Postoperative epidural infusion provided excellent analgesia without any major hemodynamic fluctuations which helped to decrease the use of opioids and NSAIDs.

REFERENCES

1. Kulkarni K, Namazi IJ, Deshpande S, Goel R. Cervical epidural anaesthesia with ropivacaine for modified radical mastectomy. Kathmandu University Medical Journal. 2015 May 2;11(2):126-31.
2. Patel LP, Sanghvi PR, Agarwal MB, Prajapati GC, Patel BM. Thoracic paravertebral block for analgesia after modified radical mastectomy. Indian Journal of Pain. 2014 Sep 1;28(3):160.
3. Sidiropoulou T, Buonomo O, Fabbi E, Silvi MB, Kostopanagioutou G, Sabato AF, Dauri M. A prospective comparison of continuous wound infiltration with ropivacaine versus single-injection paravertebral block after modified radical mastectomy. Anesthesia & Analgesia. 2008 Mar 1;106(3):997-1001
4. Pei L, Zhou Y, Tan G, Mao F, Yang D, Guan J, Lin Y, Wang X, Zhang Y, Zhang X, Shen S. Ultrasound-Assisted Thoracic Paravertebral Block Reduces Intraoperative Opioid Requirement and Improves Analgesia after Breast Cancer Surgery: A Randomized, Controlled, Single-Center Trial. PLoS one. 2015 Nov 20;10(11):e0142249.
5. Mahmoud AA, Hussein HA, Girgis K, Kamal AM, Nafady HA. The novel use of spinal anaesthesia at the mid-thoracic level: a feasibility study. The Egyptian Journal of Cardiothoracic Anesthesia. 2014 Jan 1;8(1):21.
6. Belzarena SD. Comparative study between thoracic epidural block and general anaesthesia for oncologic mastectomy. Revista brasileira de anesthesiologia. 2008 Dec;58(6):561-8.
7. Sundarathiti P, Pasutharnchat K, Kongdan Y, Suranutkarin PE. Thoracic epidural anaesthesia (TEA) with 0.2% ropivacaine in combination with ipsilateral brachial plexus block (BPB) for modified radical mastectomy (MRM). J Med Assoc Thai. 2005 Apr 9;88(4):513-20.
8. Park SY, Chun HR, Kim MG, Lee SJ, Kim SH, Ok SY, Cho A. Transient Horner's syndrome following thoracic epidural anaesthesia for mastectomy: a prospective observational study. Canadian Journal of Anesthesia/Journal canadien d'anesthésie. 2015 Mar 1;62(3):252-79
9. Soni R, Dharkar D, Vijayan KG. Thoracic epidural anaesthesia (TEA) for 100 radical mastectomies at Indore Cancer Foundation, India: 231. Regional Anesthesia and Pain Medicine. 2007 Sep 1;32(5):172.

10. Doss NW, Ipe J, Crimi T, Rajpal S, Cohen S, Fogler RJ, Michael R, Gintautas J. Continuous thoracic epidural anaesthesia with 0.2% ropivacaine versus general anaesthesia for perioperative management of modified radical mastectomy. *Anesthesia & Analgesia*. 2001 Jun 1;92(6):1552-7.
11. Unic-Stojanovic D, Babic S, Jovic M. Benefits, risks and complications of perioperative use of epidural anaesthesia. *Medical Archives*. 2012 Sep 1;66(5):340.
12. Pan YS, Hu YF, Tian FB, Xu K. Effects of epidural preemptive analgesia on stress reaction in retroperitoneal laparoscopic adrenalectomy surgery: a randomized controlled study. *International journal of clinical and experimental medicine*. 2015;8(6):9862.
13. Garcha HS, Walia C, Aujla KS, Gupta R. A Study to Compare Intravenous Fentanyl With Epidural Bupivacaine-Fentanyl Combination For Post Operative Analgesia in Patients Undergoing Modified Radical Mastectomy. *International Journal of Scientific Research*. 2016 Apr 12;5(2).
14. Brull R, McCartney CJ, Chan VW, El-Beheiry H. Neurological complications after regional anaesthesia: contemporary estimates of risk. *Anesthesia & Analgesia*. 2007 Apr 1;104(4):965-74.
15. Humble SR, Dalton AJ, Li L. A systematic review of therapeutic interventions to reduce acute and chronic post-surgical pain after amputation, thoracotomy or mastectomy. *European Journal of Pain*. 2015 Apr 1;19(4):451-65.
16. Baek YH, Ok SY, Kim SI, Kim SC, Lee MH. Effects of continuous epidural infusion after thoracic epidural anaesthesia for mastectomy on postoperative pain, nausea and vomiting. *Korean Journal of Anesthesiology*. 2007 Apr 1;52(4):396-402..

How to cite this article: Vineetha P, Ramadas KT, Sajid B, Biji KP. A prospective observational study to assess the efficacy of thoracic epidural anaesthesia for mastectomy. *Ann. Int. Med. Den. Res.* 2017; 3(3):AN09-AN13.

Source of Support: Nil, **Conflict of Interest:** None declared