



## Outcome of Patte Modification of Latarjet Procedure for Recurrent Anterior Instability of the Shoulder

Rabin Chandra Halder<sup>1\*</sup>, Syed Khaledur Rahman<sup>2</sup>, Mahammad Mahbubur Rahman Khan<sup>3</sup>, Omar Faruque<sup>4</sup>, Md. Bahauddin Al Mamun<sup>5</sup>, Md. Al Mamun<sup>6</sup>

<sup>1</sup>Assistant Register, Department of Orthopedic, National Institute of Traumatology and Orthopaedic Rehabilitation (NITOR), Dhaka, Bangladesh, E-mail: rabinsbmc29@gmail.com, Orcid Id: 000-0003-3346-1340

<sup>2</sup>Assistant Register, Department of Orthopedic, National Institute of Traumatology and Orthopaedic Rehabilitation (NITOR), Dhaka, Bangladesh, E-mail: drkhaledurrahman@gmail.com, Orcid Id: 0000-0002-4420-6444

<sup>3</sup>Assistant Register, Department of Orthopedic, National Institute of Traumatology and Orthopaedic Rehabilitation (NITOR), Dhaka, Bangladesh, E-mail: mahbubur37@yahoo.com, Orcid Id: 0000-0001-6279-2662

<sup>4</sup>Junior Consultant, Department of Orthopedic, National Institute of Traumatology and Orthopaedic Rehabilitation (NITOR), Dhaka, Bangladesh, E-mail: omarmmc36@gmail.com, Orcid Id: 0000-0001-8270-3292

<sup>5</sup>Assistant Register, Department of Orthopedic, National Institute of Traumatology and Orthopaedic Rehabilitation (NITOR), Dhaka, Bangladesh, E-mail: drmamun123@yahoo.com, Orcid Id: 000-0003-3346-1340

<sup>6</sup>Resident, Department of Orthopedic, National Institute of Traumatology and Orthopaedic Rehabilitation (NITOR), Dhaka, Bangladesh, E-mail: sunsetbd@gmail.com, Orcid Id: 000-0003-3346-1340

\*Corresponding author

Received: 09 May 2021

Revised: 23 June 2021

Accepted: 02 July 2021

Published: 21 August 2021

### Abstract

**Background:** Glenohumeral instability & recurrent shoulder dislocation is a common clinical entity & the anterior instability is the most common among them. Different surgical technique both open and arthroscopic technique have been described for treating anterior shoulder instability. Among the open procedure, two widely applied surgical procedure: Bankart type capsule retention or reinsertion first described in 1938 and Bone block described by Latarjet in 1954. This Latarjet procedure is modified by Patte in 1980 in this procedure coracoacromial ligament is preserved with coracoid bone graft. Coracoid is fixed with two screw & washer & coracoacromial ligament is anchored with capsule. **Methods:** The current study included sixteen (32) patients with recurrent anterior shoulder dislocation who were enrolled from July 2017 to June 2021 through non randomized purposive sampling considering the inclusion and exclusion criteria. They were surgically treated by Patte modification of Latarjet procedure and were analyzed prospectively. The average follow-up time was 6 months. **Results:** The mean age was 25.88 years with male dominant 13(81%). The right side was affected in 11 (68.75%) shoulders. The most common mechanism of injury was sports and RTA each 7 (43.75%) cases. The mean recurrent dislocation was 7.13 times before surgery. Among the cases 9 (56.25%) had no radiographic lesion, 4 (25%) had Hill Sachs lesion, 3 (18.75%) had Bankart lesions. The mean time interval between injuries to operation was about 3 years. There were 13 (81.25 %) cases without complications, 2 (12.50%) cases with limitation of movements and one case (6.25%) with occasional pain. At final follow up according to ROWE score for shoulder instability 10 (62.50%) with Excellent outcome, 5 cases (31.25%) with Good outcome and one case (6.25%) with Fair outcome in regards of stability, range of motion and function. **Conclusions:** From this study it can be concluded that, Patte modification of Latarjet procedure for recurrent anterior shoulder dislocation leads to Excellent to Good results in majority of cases.

**Keywords:-** Patte Modification, Latarjet Procedure, Recurrent Anterior Instability

## INTRODUCTION

Shoulder dislocations represent 50% of all joint dislocations in the human body with an incidence of 12 per 100,000/year.<sup>[1]</sup> Recurrent instability of the shoulder is the main complication of anterior glenohumeral and it accounts for 10 to 15 % recurrence rate in patients aged 20 to 40 years.<sup>[2]</sup> The operative management of recurrent instability has evolved since its first description by Bankart in. In the last 20-years, many open and arthroscopic procedures have been described, both for acute and chronic instabilities.<sup>[3]</sup> With improved understanding of the pathoanatomic changes associated with recurrent instability, more recently debate has shifted focus to soft tissue versus bony surgical stabilization procedures. Shoulders with recurrent instability are associated with a high incidence of bone loss. Glenoid and/or humeral bone lesions have been shown to be present in 90% to 95% of shoulders with recurrent instability. Failure to address these bone defects can result in a poor outcome.<sup>[4]</sup> The rate of recurrent anterior shoulder dislocation after surgery varies from 0 to 57% in the long term, and this can be due to inappropriate patient selection or unrecognized/ underestimated pathological changes.<sup>[5]</sup> Two techniques are widely applied in the surgical management of recurrent anterior instability of the shoulder: bone-block as described by Latarjet in 1954 and modified by Patte in 1980, and Bankart-type capsular retention or reinsertion, first described. In 1938. Michel Latarjet described his technique for shoulder stabilization in 1954, whereby the horizontal limb of the coracoid process was transposed to the anteroinferior glenoid rim through a window in the subscapularis and fixed with a single screw. The Latarjet-Patte

procedure is a modification of this involving the use of 2 screws and including repair of the anterior capsule to the stump of the coracoacromial ligament.<sup>[6]</sup> The Latarjet-Patte procedure has been proposed to address both bony and soft tissue deficiencies with a "triple-locking" effect. The procedure consists of a triple-locking technique, combining a "bone lock" constituted by the coracoid graft screwed to the anterior glenoid, a "muscular lock" constituted by the hammock effect of the conjoined tendon, and a "capsular lock" constituted by reinserting and shortening the inferior capsular pouch on a small flap of coracoacromial ligament left on the coracoids.<sup>[7]</sup> It giving a dynamic blocking function against the humeral head in outstretched positions of the upper arm, reinforcing the mechanical effect of the bone-block and the hammock" effect induced by lowering the subscapularis tendon. The coracoid graft provides a "bony effect" by restoring the anteroposterior diameter of the glenoid, thereby increasing stability and preventing an otherwise engaging Hill-Sachs lesion from levering on a deficient anteroinferior glenoid rim.<sup>[8]</sup> The most important stabilizing mechanism of the Latarjet Patte procedure is however the interaction between the conjoint tendon and lower subscapularis with the arm in abduction and external rotation. In this position, the conjoint tendon reinforces the inferior subscapularis fibers and anteroinferior joint capsule to provide a so-called "sling effect." It also counteracts the ligament laxity seen with recurrent instability through a tensioning effect on the lower subscapularis as it passes through a split in the muscle.<sup>[9]</sup> Essentially, the lower subscapularis fills the potential space into where the humeral head would otherwise dislocate. The further the arm moves into the at-

risk position of abduction and external rotation, the tighter the sling effect becomes. Finally, repair of the anterior capsule to the stump of the coracoacromial ligament completes the triple blocking effect. This mechanism is most important in abduction and neutral rotation. The Latarjet-Patte procedure is indicated for patients affected by recurrent anterior instability with glenoid bone loss 225% of the glenoid width, an engaging Hill-Sachs lesion, or failure of anterior labral repair.<sup>[10]</sup> Surgery can be proposed after a first time dislocation in patients involved in contact sports activities at a competitive level. Voluntary subluxation or dislocation is a contraindication to this procedure. The present study examined the effect of Patte modification of Latarjet procedure for recurrent anterior instability of the shoulder in our institute.

## **Objectives**

### **General objectives**

- To evaluate the surgical outcome of patte modification of Latarjet procedure for the treatment of recurrent anterior instability of shoulder.

### **Specific objectives**

- To evaluate clinical outcome.
- To examine the functional outcome.
- To observe the complications of the procedure.

## **MATERIAL AND METHODS**

The current study included sixteen (32) patients with recurrent anterior shoulder dislocation who were enrolled from July 2017 to June 2021 through non randomized purposive sampling considering the inclusion and exclusion criteria. They were surgically treated by Patte

modification of Latarjet procedure and were analyzed prospectively. The average follow-up time was 1year. Cases were selected for study from OPD after x-ray examination, then admitted to hospital. After counselling for surgical technique then taking consent for thesis enrolment, preoperative data were collected. After discussing the technique with the surgical team, operation done methodically, preoperative and postoperative data were recorded. Each patient was followed up for at least 24 weeks, clinical and functional scoring done and recorded for final outcome evaluation. Data will be collected and verified after data collection session for accuracy. Coding will be done by giving a serial number for each answer. Data will be clean, edited and verified daily to exclude any error or inconsistency. After coding, adherence and knowledge scoring will be done. Ethical clearance and permission will be taken from the concern authority. All patients will be explained regarding the study and informed consent will be taken prior history taking, clinical examination and operation. The study will not include any additional investigation and economic burden to the patients.

### **Inclusion criteria:**

Clinically diagnosed Recurrent Anterior Dislocation or Subluxation of shoulder joint.

**Age:** Between 18 to 55 years. Both Gender.

### **Exclusion criteria:**

Voluntary anterior instability, recurrent dislocation with Osteoarthritis, Recurrent dislocation with Rotator cuff tears, Age before 18 and after 55 years. Posterior shoulder dislocation.

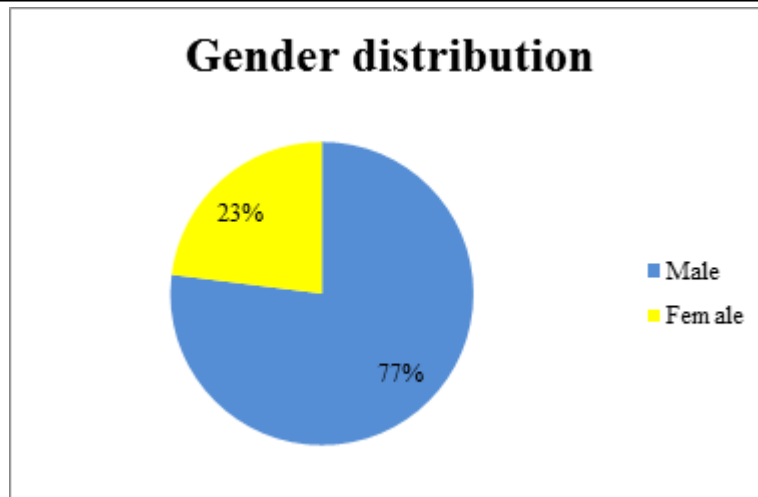
## RESULTS

A total number of 32 patients were enrolled in this study as per inclusion and exclusion criteria. Diagnosis of Recurrent anterior Instability of Shoulder was made by history, clinical examination and radiology. Patients were treated with Patte Modification of Latarjet Procedure. Patients were followed up regularly for at least 48 weeks. The results were assessed on the basis of ROWE score. The youngest in our series is 20 years old and the oldest is 38 years. Majority were in 18-23 years. Among 32 patients mean age was 25.88 years (Range 18-38 years old). In the present series, maximum patients were male 13(81%) and 3 (19%) patients were female. In the present series, 22(68.75%) with sided recurrent dislocation of shoulder and 10(31.25%) presented with left sided recurrent dislocation of shoulder. Out of 32 cases, 14 (43.75%) cases gave history of Sports injury, 14 (43.75%) cases gave history of road traffic accidents, 4 (12.50%) cases gave history of heavy weight lifting. Out of 16 cases, on average immobilization after the first dislocation is 9

days. Only one patient had history of on immobilization after dislocation. Among 16 patients 14 (43.75%) are Students, 8 (25%) are Service holders, 6 (18.75%) are housewife, One patient is labour and 2 (6.25%) is businessman. Among 32 Patients, mean frequency of recurrence before surgery was  $7.13 \pm 1.36$ . Out of 32 patient's 14 (43.75%) patients were operated between (1-2) years of receiving injury, 10 (31.25%) patients within (3-4) years, 8 (25%) patients within (5-6) years of injury. Mean interval between injury and operation was  $3.15 \pm 1.49$  years. In our series 8 (25%) cases had Hill Sach's lesion, 6 (18.75%) with Bankart Lesion and 18 (56.25%) with in any radiographic lesion. Among 32 patient's 26 (81.25%) patient's shows no complications up to final follow up, 4 (12.50%) patients showed limitation of movements and 2 (6.25%) patient reported pain at final follow up. Mean ROWE Score after Surgery at last follow-up  $86.19 \pm 7.06$ . Among 32 patients, 20 (62.50%) patient's shows excellent outcome, 10(31.25%) patients shows good result, 2(6.25%) patient shows fair outcome.

**Table 1:** Age distribution of the patients (n=32)

Age (In years)	Frequency	Percentage
18-23	14	43.75
24-28	12	37.5
29-33	4	12.5
34-38	2	6.25
Total	32	100
Mean±SD	25.88±4.67	



**Figure 1:** Gender distribution of the patients.

**Table 2:** Shoulder involved (n=32)

Side	Number of Patients	Percentage
Right	22	68.75
Left	10	31.25
Total	32	100

**Table 3:** Causes of 1<sup>st</sup> Dislocation

Causes of 1st Dislocation	Number	Percentage
Road traffic accident	14	43.75
Sports	14	43.75
Heavy weightlifting	4	12.5
Total	32	100

**Table 4:** Distribution of the patients by occupations

Occupation	Frequency	Percentage
Student	14	43.75
Businessman	2	6.25
Hosuswife	6	18.75
Service holder	8	25
Labor	2	6.25
Total	32	100

**Table 5:** Distribution of the patients by length of immobilization after first dislocation.

Length of immobilization after first dislocation (days)	Frequency	Percentage
5 to 10	22	68.75
11 to 14	10	31.25
Total	32	100
Mean±SD	9.14±3.27	



**Table 6:** Distribution of the patients by frequency of recurrence before surgery.

Recurrence of dislocation before surgery	Frequency	Percentage
1 to 6	14	43.75
7 to 12	18	56.25
<b>Total</b>	<b>32</b>	<b>100</b>
Mean±SD	7.13±1.36	

**Table 7:** Distribution of patient according to radiographic lesion.

Radiographic findings	Frequency	Percentage
Hill Sach's lesion	8	25.00
Bankart Lesion	6	18.75
No lesion	18	56.25
<b>Total</b>	<b>32</b>	<b>100.00</b>

**Table 8:** Time interval between first dislocation and operation (years).

Times interval in years	Frequency	Percentage
1 to 2	14	43.75
3 to 4	10	31.25
5 to 6	8	25
<b>Total</b>	<b>32</b>	<b>100</b>
Mean±SD	9.14±3.27	

**Table 9:** Complications after operation

Complication	Frequency	Percentage
None	26	81.25
Limitation of movements	4	12.5
Pain	2	6.25
<b>Total</b>	<b>32</b>	<b>100</b>

**Table 10:** ROWE Scores after Surgery at last follow-up

Score	Frequency	Percentage
100-90	20	62.5
89-75	10	31.25
74-50	2	6.25
<50	0	0
<b>Total</b>	<b>32</b>	<b>100</b>
Mean±SD	86.19±7.06	

**Table 11:** Final results according to ROWE score:

Outcome	Frequency	Percentage
Excellent	20	62.5
Good	10	31.25
Fair	2	6.25
Poor	0	0
<b>Total</b>	<b>32</b>	<b>100</b>

## DISCUSSION

The shoulder instability, surgery addresses two main issues: sustainable stability, which is the main pre-occupation of the patient, and conservation of a healthy shoulder over the long term. Surgically stabilized shoulders are less liable to develop. Osteoarthritis in the long term compared to spontaneously stabilizing shoulders. This is a study of surgical and functional outcome following Patte Latarjet procedure for recurrent anterior instability of the shoulder. In our series average age of the patients was  $25.88 \pm 4.67$  years. Majority of the dislocation occur in the age group of 18-23 years (43.75%) with male predominant (81%). Giles et al., (2014) showed similar results in their study. In 22 (68.75%) cases right shoulder was involved. Babu et al., (2018) in their study found 13 patients with right shoulder involved.<sup>[11]</sup> Majority of the patient were students 14 (43.75%), Service holder 8 (25%). Housewife were 6 (18.75%) and 2 case (6.25%) each a businessman and a labour. Main mechanism of injury was sports injury and road traffic accidents contributed 14 cases (43.75%) each. Besides that, Heavy weight lifting in 4 cases (12.50%). Apart from trauma, uncontrolled epilepsy and symptomatic hyperlaxity are considered other aetiological factors.

The most common pathological findings were Hill- Sachs lesion which comprises 25% and Bankart lesion was found in 18.75% cases. However 18 cases (56.25%) without any lesions. Babu et al., (2018) reported Hill Sachs lesion in majority of the cases.<sup>[11]</sup> The true incidence of Hill-Sachs lesions is unknown. However, they are associated with approximately 40% to 90% of all anterior shoulder instability events. The incidence may be as high as 100% in patients

with recurrent anterior instability.<sup>[12]</sup> A glenoid bony defect that is Bankart lesion has been reported in up to 22% of initial dislocations and in as many as 90% of patients with recurrent instability.<sup>[13]</sup> Loss of bone on the glenoid decreases the contact area available for the glenohumeral articulation and may lead to recurrent instability. Interval of operation between first dislocations to surgical intervention was 3.15 years on average. Where most of the patients were operated after waiting for at least 2 years. The reason for receiving delayed treatment is due to the fact that the patients did not report for treatment unless they had some disability or frequent dislocation. Frequency of instability before surgery ranged from 7 to 12 times in 18 (56.25%) cases. Instability can stem from a variety of coexisting factors including soft tissue pathology such as a labral tear, glenoid or humeral head bone loss, and ligamentous laxity. Persistent shoulder instability is commonly seen in younger patients, with the highest risk occurring in patients aged <25 years. Which is also relevant in our study as most of the cases belong to this age group. Immobilization after closed reduction has long been the standard treatment for primary anterior dislocation of the shoulder. In our study mean duration of immobilization after index dislocation were  $9.14 \pm 3.27$  days. Paterson et al., (2010) stated in their meta-analysis significance of immobilization after first dislocation. They demonstrated that the rate of recurrent instability was 41% (forty of ninety seven) in patients who had been immobilized for one week or less and 37% (thirty four of ninety-three) in patients who had been immobilized for three weeks or longer. Analysis of the best available evidence indicates there is no benefit of conventional sling immobilization for longer than one week for the

treatment of primary anterior shoulder dislocation in younger patients. An age of less than thirty years at the time of injury is significantly predictive of recurrence. In our series there were no complications noted in 26 cases (81.25%) with only 2 cases (6.25%) reported pain and 4 cases (12.50%) with limitation of movement. There were no cases with recurrence after surgery within our follow up period. In their study Allain et al., (1998) also stated no recurrence of dislocation or subluxation at a mean follow-up of 12 years for Patte Modification of Latarjet procedure.<sup>[14]</sup> This was better than the 89% and 38% recurrence rates for arthroscopic and open Bankart reconstruction. Zhang et al., (2010) in their series of 13 years follow up showed recurrence rate of 1.4% with only one case with osteoarthritis.<sup>[15]</sup> In our study according to ROWE score for shoulder instability; we had 20 patients (62.50%) with excellent (100-90) outcome, 10 cases (31.25 %) with Good (89-75) outcome and only 2 case (6.25%) with Fair (74-51) outcome. Allain et al., (1998) described good results according to the Rowe score in 88% of patients, fair results in 9%, and poor results in 3%. Neyton et al., (2015) observed similar rates (mean Rowe score of 93, subjective satisfaction rate of 94%) in rugby players who underwent the Latarjet-Patte reconstruction.<sup>[16]</sup> Modification of the Latarjet technique according to Patte differs from other previously reported techniques in several ways. It adds the mechanism of capsular retensioning to the classical bone block and sling effects. The graft and anterior glenoid are drilled only once, and rotation of the graft is avoided using a special

washer. One weakness of the technique is the necessity of drilling the coracoid with a 4.5 mm drill bit, potentially weakening the graft if it is narrow. As is the case with the other described technique, this is a demanding technique requiring meticulous preparation and dissection with a long learning curve.

### Limitations of the study

As a special technique may not equally convenient for every operating surgeon. Sample size was small to generate representative findings. Patient outcome report could have been subjected to inter and intra observer variations. Corona Pandemic situation jeopardized the harmony of the study. Lack of supervised physiotherapy and patient's compliance some extent may affect the outcome.

### CONCLUSIONS

Results of the modification of the Latarjet procedure according to Patte correlate with previous studies with respect to patient satisfaction and functional outcome. So, from this study it can be concluded that this is an effective technique for recurrent anterior instability of the shoulder. The results of the study can be utilized for future analysis. A long-term study comparing with other treatment modality can prove to be beneficial. A multi-centric study should be done for further validation of the result. Considering other implant for fixation. Dedicated training programme should be organized.





## REFERENCES

1. Allain J, Goutallier D, Glorion C. Long-term results of the Latarjet procedure for the treatment of anterior instability of the shoulder. *J Bone Joint Surg Am.* 1998;80(6):841-52. doi: 10.2106/00004623-199806000-00008.
2. Anakwenze OA, Hsu JE, Abboud JA, Levine WN, Huffman GR. Recurrent anterior shoulder instability associated with bony defects. *Orthopedics.* 2011;34(7):538-44. doi: 10.3928/01477447-20110526-21.
3. Bankart AS. Recurrent or Habitual Dislocation of the Shoulder-Joint. *Br Med J.* 1923;2(3285):1132-1133. doi:10.1136/bmj.2.3285.1132
4. Bankart ASB. The pathology and treatment of recurrent dislocation of the shoulder joint. *British Journal of Surgery.* 1938;26(101):23-29.
5. Bouju Y, Gadéa F, Stanovici J, Moubarak H, Favard L. Shoulder stabilization by modified Latarjet-Patte procedure: results at a minimum 10 years' follow-up, and role in the prevention of osteoarthritis. *Orthop Traumatol Surg Res.* 2014;100(4 Suppl):S213-8. doi: 10.1016/j.otsr.2014.03.010.
6. Balg F, Boileau P. The instability severity index score. A simple pre-operative score to select patients for arthroscopic or open shoulder stabilisation. *J Bone Joint Surg Br.* 2007;89(11):1470-7. doi: 10.1302/0301-620X.89B11.18962.
7. Fealy S, Rodeo SA, Dicarlo EF, O'Brien SJ. The developmental anatomy of the neonatal glenohumeral joint. *J Shoulder Elbow Surg.* 2000;9(3):217-22.
8. Cutts S, Prempeh M, Drew S. Anterior shoulder dislocation. *Ann R Coll Surg Engl.* 2009;91(1):2-7. doi:10.1308/003588409X359123
9. Cain PR, Mutschler TA, Fu FH, Lee SK. Anterior stability of the glenohumeral joint. A dynamic model. *Am J Sports Med.* 1987;15(2):144-8. doi: 10.1177/036354658701500209.
10. Constant CR, Murley AH. A clinical method of functional assessment of the shoulder. *Clin Orthop Relat Res.* 1987;(214):160-4. PMID: 3791738.
11. Ramhamadany E, Modi CS. Current concepts in the management of recurrent anterior gleno-humeral joint instability with bone loss. *World J Orthop.* 2016;7(6):343-354. doi:10.5312/wjo.v7.i6.343
12. Rowe CR, Patel D, Southmayd WW. The Bankart procedure: a long-term end-result study. *J Bone Joint Surg Am.* 1978;60(1):1-16.
13. Taylor DC, Arciero RA. Pathologic changes associated with shoulder dislocations. Arthroscopic and physical examination findings in first-time, traumatic anterior dislocations. *Am J Sports Med.* 1997;25(3):306-11. doi: 10.1177/036354659702500306.
14. Allain J, Goutallier D, Glorion C. Long-term results of the Latarjet procedure for the treatment of anterior instability of the shoulder. *J Bone Joint Surg Am.* 1998;80(6):841-52. doi: 10.2106/00004623-199806000-00008.
15. Zhang Y, Jordan JM. Epidemiology of osteoarthritis. *Clin Geriatr Med.* 2010;26(3):355-369. doi:10.1016/j.cger.2010.03.001
16. Neyton L, Young A, Dawidziak B, Visona E, Hager JP, Fournier Y, Walch G. Surgical treatment of anterior instability in rugby union players: clinical and radiographic results of the Latarjet-Patte procedure with minimum 5-year follow-up. *J Shoulder Elbow Surg.* 2012;21(12):1721-7. doi: 10.1016/j.jse.2012.01.023.

Source of Support: Nil, Conflict of Interest: None declared