



Assessment of Profile of Complications in Pterygium Surgery- A Clinical Study

Ashish Jain^{1*}, Priyanka Jain²,

¹Assistant Professor, Department of Pediatrics, Rama Medical College, Hapur, Uttar Pradesh, India.

Orcid ID: 0000-0003-0330-9129,

Email: jainmedicalcenter@yahoo.co.in,

²Assistant Professor, Department of Ophthalmology, Rama Medical College, Hapur, Uttar Pradesh, India.

Orcid ID: 0000-0002-2037-6334,

Email: priyankajainashish@gmail.com

*Corresponding author

Received: 07 May 2021

Revised: 27 June 2021

Accepted: 07 July 2021

Published: 21 August 2021

Abstract

Background: To assess complications of pterygium surgery. **Methods:** Fifty- six patients who underwent pterygium surgery in last 1 year of both genders were selected. Pterygium was graded in four stages, grade 1, grade 2, grade 3 and grade 4. Postoperative complications were recorded. **Results:** Out of 56 patients, males were 30 (53.7%) and females were 26 (46.3%). Grade 1 was seen in 4, grade 2 in 28, grade 3 in 16 and 4 in 8 patients. Common clinical features was progressive in 34, vascular in 26, atrophic in 14, symblepharon in 12 and ocular motility restriction in 4 cases. Treatment performed was bare sclera in 5, primary closure in 6, AMT in 10, CAG in 22, CAG+ AMT in 7 and primary closure+ MMC in 6 cases. Common complications were corneal thinning in 2, corneal perforation in 4, bleeding in 5, partial graft dislocation in 2 and graft hematoma in 1 case. A significant difference was observed ($P < 0.05$). **Conclusion:** Common complications of pterygium surgery were corneal thinning, corneal perforation, bleeding, partial graft dislocation and graft hematoma.

Key words: Corneal thinning, Corneal perforation, pterygium surgery, Sclera

INTRODUCTION

A pterygium is a wing-shaped growth of fibrovascular conjunctiva onto the cornea. Its incidence varies across geographical locations. Several hypotheses have been ascribed to its aetiology.^[1] Currently, it is believed that the pterygium is a growth disorder characterised by conjunctivalisation of the cornea due to localised ultraviolet induced damage to the limbal stem cells.^[2] Aggressive pterygial fibroblasts are also responsible for corneal invasiveness. The indications for surgery include reduced vision due to encroachment of the visual axis and irregular astigmatism, chronic irritation

and recurrent inflammation, restriction of ocular motility, and cosmesis.^[3]

It is commonly seen in tropical and subtropical areas between the latitudes 30 degree north and south of the equator which includes India. It is caused by increased light exposure, dust, dryness, heat and wind. The cornea must be clear to let the light get into the eye and the visual process begins.^[4] When the cornea loses its transparency, the sight could be severely affected, as happens when pterygium grows and covers the pupillary axis. Patients with pterygium consult physicians because of discomfort, ocular surface inflammation, red eyes, (aesthetic reasons) or finally, when their vision is decreased.^[5]

Although ocular lubrication is required in the presence of symptoms (irritation, red and dry eye), surgery is indeed necessary when the visual axis is covered or the ocular movement restricted.^[6] Another indication for pterygium surgery is cosmetic disturbance. The main complication of pterygium surgery is recurrence, which can be up to 89% according to the different surgical techniques. Pterygium excision with conjunctival autografting is currently the gold standard technique, which provides the lowest recurrence rate, between 3.3% and 16.7%. Low compliance with postoperative treatment has been associated with a higher risk of recurrence.^[7] We undertook present study to assess complications of pterygium surgery performed on patients.

MATERIALS & METHODS

Fifty- six patients who underwent pterygium surgery in last 1 year of both genders were selected. Approval of the study was obtained from institutional ethical clearance

RESULTS

Table 1: Distribution of patients

Total- 56		
Gender	Males	Females
Number	30 (53.7%)	26 (46.3%)

Out of 56 patients, males were 30 (53.7%) and females were 26 (46.3%).

Table 2: Grading of pterygium

Grading	Number	P value
1	4	<0.05
2	28	
3	16	
4	8	

committee. All selected patients were informed regarding the study and their written consent was obtained.

Demographic profile of each patient such as name, age, gender etc. was recorded. A thorough eye examination was performed by ophthalmologist. Pterygium was graded in four stages, grade 1 (less than 2.0 mm), grade 2 (2.0 mm - 4.0 mm), grade 3 (higher than 4.00 mm, without covering the visual axis) and grade 4 (tissue covering the visual axis). Routine follow-up was done. Parameters such as type of surgery performed (bare sclera excision, primary closure, amniotic membrane transplantation (AMT), CAG, conjunctival-limbal autograft (CLAG), or concomitant use of surgical adjuvants), recurrences with respect to the type of surgery performed and postoperative complications were recorded. Results of the present study after recording all relevant data were subjected for statistical inferences using chi- square test. The level of significance was significant if p value is below 0.05 and highly significant if it is less than 0.01.

Grade 1 was seen in 4, grade 2 in 28, grade 3 in 16 and 4 in 8 patients (Table 2, graph 1). A significant difference was observed ($P < 0.05$).

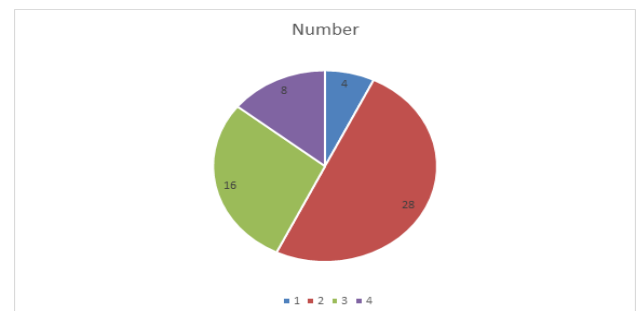


Figure 1: Grading of pterygium

Table 3: Assessment of parameters

Parameters	Variables	Number	P value
Clinical features	Progressive	34	<0.05
	Vascular	26	
	Atrophic	14	
	Symblepharon	12	
	Ocular motility restriction	4	
Treatment	Bare sclera	5	<0.05
	Primary closure	6	
	AMT	10	
	CAG	22	
	CAG+ AMT	7	
	Primary closure+ MMC	6	

Common clinical features was progressive in 34, vascular in 26, atrophic in 14, symblepharon in 12 and ocular motility restriction in 4 cases. Treatment performed was bare sclera in 5, primary closure in 6, AMT in 10, CAG in 22, CAG+ AMT in 7 and primary closure+ MMC in 6 cases. A significant difference was observed ($P < 0.05$) [Table 3].

Table 4: Complications of pterygium

Complications	Number	P value
Corneal thinning	2	<0.05
Corneal perforation	4	
Bleeding	5	
Partial graft dislocation	2	
Graft hematoma	1	

Common complications were corneal thinning in 2, corneal perforation in 4, bleeding in 5, partial graft dislocation in 2 and graft hematoma in 1 case. A significant difference was observed ($P < 0.05$) [Table 4].

DISCUSSION

Pterygium, a word derived from “pterygion” (ancient Greek for wing), is a wing-shaped, fibrovascular overgrowth arising from

subconjunctival tissue extending across the limbus onto the cornea.^[8] It is a degenerative condition of the subconjunctival tissue which proliferates as vascularized granulation tissue to invade cornea, destroying superficial layers of stroma and Bowman's membrane, the whole being covered by conjunctival epithelium.^[9] The indications for surgery include reduced vision due to encroachment of the visual axis and irregular astigmatism, chronic irritation and recurrent inflammation, restriction of ocular motility, and cosmesis.^[10] Numerous surgical techniques including bare sclera excision with or without the use of adjuncts like beta irradiation, thiotepa eye drops, intra- or postoperative mitomycin C (MMC) or antineoplastic agents, amniotic membrane transplantation, conjunctival autograft (CAG) with or without limbal stem cells have been described.^[11] In this study we assessed complications of pterygium surgery performed on patients.

We enrolled 56 patients of which males were 30 (53.7%) and females were 26 (46.3%). Fernandes et al,^[12] retrospectively analysed medical records of 920 patients (989 eyes) with primary and recurrent pterygia. The demographic variables, surgical technique (bare sclera, primary closure, amniotic membrane transplantation (AMT), conjunctival autograft (CAG), conjunctival-limbal autograft (CLAG), or surgical adjuvants), recurrences and postoperative complications were analysed. Results A total of 496 (53.9%) were male and 69 (7.5%) had bilateral pterygia. Bare sclera technique was performed in 267 (27.0%) eyes, primary conjunctival closure in 32 (3.2%), AMG in 123 (12.4%), CAG in 429 (43.4%), and CLAG in 70 (7.1%). Adjuvant mitomycin C was used in 44 (4.4%) cases. The mean duration of follow-up was 8.9717.0 and 5.978.8 months for unilateral primary and recurrent pterygia, respectively.

The overall recurrence rate was 178 (18.0%). Following primary and recurrent unilateral pterygium excision respectively, recurrences were noted in 46 (19.4%) and 1 (33.3%) eyes after bare sclera technique, five (16.7%) and 0 after primary closure, 28 (26.7%) and 0 with AMG, 42 (12.2%) and five (31.3%) with CAG, and nine (17.3%) and two (40%) with CLAG. Recurrences were significantly more in males with primary and recurrent pterygia, and in those below 40 years.

We found that grade 1 was seen in 4, grade 2 in 28, grade 3 in 16 and 4 in 8 patients. Common clinical features was progressive in 34, vascular in 26, atrophic in 14, symblepharon in 12 and ocular motility restriction in 4 cases. Treatment performed was bare sclera in 5, primary closure in 6, AMT in 10, CAG in 22, CAG+ AMT in 7 and primary closure+ MMC in 6 cases. Prabhasawat et al,^[13] conducted a study in which 120 surgeries were performed in 99 patients. Protocol 1 was applied in 63 cases and the next 57 followed protocol 2. Compliance with protocol 1 (57.6%) was lower than with protocol 2 (84.9%) ($p=0.002$). Intraoperative complications (graft tear, corneal thinning, corneal perforation and bleeding) were found in 10 cases of protocol 1 and three cases of protocol 2, $p=0.08$. Postoperative complications (graft dislocation, graft haematoma, ocular hypertension and recurrence) were found in 31 cases of protocol 1 (46.2%) and eight cases of protocol 2 (14%), $p=0.001$. Six weeks after surgery, ocular hypertension was detected in eight cases corresponding to protocol 1 (13.6%) and two cases of protocol 2 (3.8%), $p=0.099$. Recurrence rate during first year was higher in protocol 1 (26.3%) compared to protocol 2 (7.6%), $p=0.011$. No cases of visual acuity worsening or infection were registered.

We found that common complications were corneal thinning in 2, corneal perforation in 4, bleeding in 5, partial graft dislocation in 2 and graft hematoma in 1 case. Elwan et al,^[14] found that a pterygium is generally managed conservatively unless it is progressing toward the pupillary area causing excessive astigmatism, resulting in decreased vision. The reported rates of recurrence are 25%–45% after simple excision of primary pterygium. The high rates of the recurrence have been explained by the theory of corneal limbal stem cell deficiency.

Koranyi et al,^[15] compared 7/0 vicryl suture to fibrin glue in their study. They assessed postoperative patient complaints and operation time. They found that patient discomfort was less and operation time was shorter in fibrin glue group. In addition, they reported that the cost of one fibrin glue was equal to the cost of five sutures and one fibrin glue can be used for 6–7 patients, making the overall cost of surgery same for both the Group.

CONCLUSION

Common complications of pterygium surgery were corneal thinning, corneal perforation, bleeding, partial graft dislocation and graft hematoma.

REFERENCES

1. Li DQ, Lee SB, Gunja-Smith Z, Liu Y, Solomon A, Meller D, et al. Overexpression of collagenase (MMP-1) and stromelysin (MMP-3) by pterygium head fibroblasts. *Arch Ophthalmol.* 2001;119(1):71-80.
2. Chui J, Coroneo MT, Tat LT, Crouch R, Wakefield D, Di Girolamo N. Ophthalmic pterygium: a stem cell disorder with premalignant features. *Am J Pathol.* 2011;178(2):817-827. doi:10.1016/j.ajpath.2010.10.037

3. Hirst LW. The treatment of pterygium. *Surv Ophthalmol.* 2003;48(2):145-80. doi: 10.1016/s0039-6257(02)00463-0.
4. Rao SK, Lekha T, Mukesh BN, Sitalakshmi G, Padmanabhan P. Conjunctival-limbal autografts for primary and recurrent pterygia: technique and results. *Indian J Ophthalmol* 1998; 46: 203–209.
5. Dupps WJ Jr, Wilson SE. Biomechanics and wound healing in the cornea. *Exp Eye Res.* 2006;83(4):709-20. doi: 10.1016/j.exer.2006.03.015. Epub 2006 May 23.
6. Kheirkhah A, Safi H, Nazari R, Kaghazkanani R, Hashemi H, Behrouz MJ. Effects of pterygium surgery on front and back corneal surfaces and anterior segment parameters. *Int Ophthalmol.* 2012;32(3):251-7. doi: 10.1007/s10792-012-9560-2.
7. Ti SE, Chee SP, Dear KB, Tan DT. Analysis of variation in success rates in conjunctival autografting for primary and recurrent pterygium. *Br J Ophthalmol.* 2000;84(4):385-9. doi: 10.1136/bjo.84.4.385.
8. Alpay A, Uğurbaş SH, Erdoğan B. Comparing techniques for pterygium surgery. *Clin Ophthalmol.* 2009;3:69-74. PMID: 19668546.
9. Nakamura T, Inatomi T, Sekiyama E, Ang LP, Yokoi N, Kinoshita S. Novel clinical application of sterilized, freeze-dried amniotic membrane to treat patients with pterygium. *Acta Ophthalmol Scand.* 2006;84(3):401-5. doi: 10.1111/j.1600-0420.2006.00667.x.
10. Pikkell J, Porges Y, Ophir A. Halting pterygium recurrence by postoperative 5-fluorouracil. *Cornea.* 2001;20(2):168-71. doi: 10.1097/00003226-200103000-00011.
11. Ha SW, Park JH, Shin IH, Kim HK. Clinical analysis of risk factors contributing to recurrence of pterygium after excision and graft surgery. *Int J Ophthalmol.* 2015;8(3):522-7. doi: 10.3980/j.issn.2222-3959.2015.03.15.
12. Fernandes M, Sangwan VS, Bansal AK, Gangopadhyay N, Sridhar MS, Garg P, et al. Outcome of pterygium surgery: analysis over 14 years. *Eye (Lond).* 2005;19(11):1182-90. doi: 10.1038/sj.eye.6701728.
13. Prabhasawat P, Tesavibul N, Leelapatranura K, Phonjan T. Efficacy of subconjunctival 5-fluorouracil and triamcinolone injection in impending recurrent pterygium. *Ophthalmology.* 2006;113(7):1102-9. doi: 10.1016/j.ophtha.2006.02.026.
14. Elwan SA. Comparison between sutureless and glue free versus sutured limbal conjunctival autograft in primary pterygium surgery. *Saudi J Ophthalmol.* 2014;28(4):292-298. doi:10.1016/j.sjopt.2014.03.012
15. Koranyi G, Seregard S, Kopp ED. Cut and paste: a no suture, small incision approach to pterygium surgery. *Br J Ophthalmol.* 2004;88(7):911-4. doi: 10.1136/bjo.2003.032854.

Source of Support: Nil, Conflict of Interest: None declared